

Brief report

Severe hereditary spherocytosis and distal renal tubular acidosis associated with the total absence of band 3

Maria Leticia Ribeiro, Nicole Alloisio, Helena Almeida, Clara Gomes, Pascale Texier, Carlos Lemos, Gabriela Mimoso, Laurette Morlé, Faiza Bey-Cabet, René-Charles Rudigoz, Jean Delaunay, and Gabriel Tamagnini

Absence of band 3, associated with the mutation Coimbra (V488M) in the homozygous state, caused severe hereditary spherocytosis in a young child. Although prenatal testing was made available to the parents, it was declined. Because the fetus stopped moving near term, an emergency cesarean section was performed and a severely anemic, hydropic female baby was delivered. She was resuscitated

and initially kept alive with respiratory assistance and hypertransfusion therapy. Cord blood smears revealed erythroblastosis, poikilocytosis, and red cells with stalk-like elongations. Band 3 and protein 4.2 were absent; spectrin, ankyrin, and glycophorin A were significantly reduced. Renal tubular acidosis was detected by the age of 3 months. Nephrocalcinosis appeared soon thereafter. After 3 years of

follow-up the child is doing reasonably well on a regimen that includes regular blood transfusions and daily bicarbonate supplements. The long-term prognosis remains uncertain given the potential for hematologic and renal complications. (Blood. 2000; 96:1602-1604)

© 2000 by The American Society of Hematology

Introduction

Band 3, also known as the red cell anion exchanger 1, is encoded by the *EPB3* gene. Band 3 Coimbra (GTG→ATG; V488M) represents a mutation at the beginning of the fourth transmembrane domain.¹ Insertion of the fourth transmembrane domain is a prerequisite for incorporation of transmembrane domains 1 through 3² and therefore band 3 Coimbra must represent a membrane insertion defect. In addition, an *N*-terminally truncated band 3 isoform exists in renal tubular intercalated A cells.

In the heterozygous state, band 3 Coimbra causes typical hereditary spherocytosis (HS) and is associated with partial deficiency of band 3 and of protein 4.2 (the latter is deficient as a secondary phenomenon).¹ In addition, certain mutations of the *EPB3* gene are responsible for dominant distal renal tubular acidosis (DRTA).³⁻⁵ In these cases, the amount of erythrocyte band 3 is normal and hematologic manifestations are absent. A mutation causing band 3 deficient-HS and partial DRTA,⁶ or a higher basal urinary pH,⁷ in the heterozygous state has been observed.

Severe HS resulting from the absence of band 3 has been observed in a natural strain of cattle⁸ and in 2 band 3 null mouse strains engineered through targeted recombination.^{9,10} In one strain glycophorin A was absent,^{10,11} and a susceptibility with respect to thrombotic complications was noted.¹² Severe HS in humans was first reported by Ribeiro and colleagues.¹³ We herein provide a full account of a case of severe HS associated with total absence of band 3, as well as follow-up over a subsequent 3-year period.

Study design

Several cousins were found to be heterozygous for band 3 Coimbra, including the patient's mother who has had 3 pregnancies. In her first pregnancy (1989), the fetus stopped moving near term, and a stillborn baby with hydrops fetalis was delivered. We have almost no information on the fetus, but we may reasonably surmise that it was homozygous for band 3 Coimbra. In her second pregnancy (1994), prenatal diagnosis, taking advantage of an *Nla*III site created by mutation Coimbra (not shown), concluded that the fetus was homozygous for the mutation. This led to medical termination of pregnancy after approval by the Coimbra Maternity Ethical Committee. The placenta had a normal appearance, but on histologic examination, a deficient formation of the capillaries and a marked siderosis were observed. The male fetus had cervical edema and no obvious malformation. Liver and spleen samples were unsuitable for analysis.

The parents declined prenatal diagnosis in the third pregnancy (1996). By week 34 of gestation, a pericardial effusion was recorded. At week 36, there was significant ascites and anasarca, and the fetus stopped moving. An emergency cesarean section was performed. The hydropic female newborn had intense pallor, generalized edema, prominent ascites, and massive hepatosplenomegaly (weight, 2445 g; Apgar scores, 2, 8, and 9).

Red blood cell indices in cord blood were: red blood cells, 1.07 T/L; hemoglobin, 52 g/L; hematocrit, 15.7%; mean corpuscular volume, 147 fL; mean corpuscular hemoglobin, 49 pg; mean corpuscular hemoglobin concentration, 31 g/dL; and reticulocytes, 9.57%. Red blood cells exhibited a wide variety of abnormal morphologies, some presenting

From Unidade de Hematologia Molecular, Serviço de Hematologia, Centro Hospitalar de Coimbra, Coimbra, Portugal; Laboratoire de Génétique Humaine, CNRS URA 1171, and Centre de Génétique Moléculaire et Cellulaire, CNRS UMR 5534, Villeurbanne, France; Unidade de Nefrologia, Hospital Pediátrico de Coimbra, Coimbra, Portugal; Maternidade Bissaya Barreto, Centro Hospitalar de Coimbra, Coimbra, Portugal; Service de Biochimie, Hôpital Debrousse, Lyon, France; Service d'Obstétrique, Hôpital de la Croix-Rousse, Lyon, France.

Submitted April 2, 1999; accepted April 18, 2000.

Supported by the Forum Hematológico, the Centre National de la Recherche Scientifique (URA 1171), the Institut National de la Santé et de la Recherche Médicale (CRE 930405), the Université Claude-Bernard Lyon-1', the

Association pour la Recherche sur le Cancer, the Association Française contre les Myopathies, and the Conseil de la Région Rhône-Alpes. Presented in part at the 39th Annual Meeting of the American Society of Hematology, San Diego, December 5-9, 1997, and published by Blood 90:265a, 1997 (suppl, abstract).

Reprints: M. L. Ribeiro, Unidade de Hematologia Molecular, Serviço de Hematologia, Hospital Pediátrico, Centro Hospitalar de Coimbra, 3001 Coimbra Codex, Portugal; e-mail: leticiar@mail.telepac.pt.

The publication costs of this article were defrayed in part by page charge payment. Therefore, and solely to indicate this fact, this article is hereby marked "advertisement" in accordance with 18 U.S.C. section 1734.

© 2000 by The American Society of Hematology

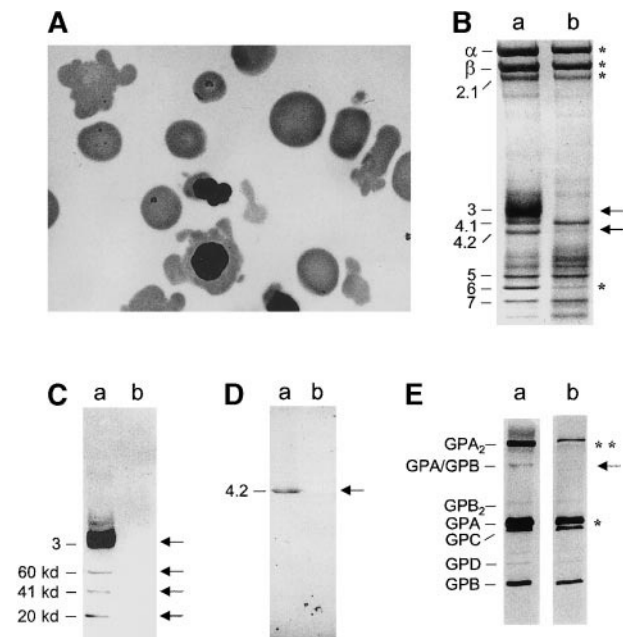


Figure 1. Peripheral blood smear, red cell membrane proteins, and glycoproteins before transfusion. (A) Red blood cells with bizarre shapes, spherocytes, and erythroblasts with cytoplasmic elongations. (B) Coomassie blue staining. (C) Western blotting of band 3 using a monoclonal antibody (Sigma, St Louis, MO). (D) Western blotting of protein 4.2 using our own polyclonal antibody. (E) Silver staining of glycoproteins; a: control; b: patient (venous blood prior to transfusion). (B) In the patient, band 3 and protein 4.2 were missing (denoted by \leftarrow); Spectrin α and β chains, ankyrin were strongly reduced, as was band 6 (*). Unlike the membrane of mice with targeted inactivation of the band 3 gene,^{9,10} the patient's membrane retained negligible amounts (4%) of hemoglobin (versus 1% in controls); residual hemoglobin would not significantly alter the quantification of membrane proteins. The amounts of protein 4.1 and actin were found to be rather similar to those of controls. (C) Band 3 was present and accompanied by known proteolytic fragments (60, 41, and 22 kD) in the control. In the patient, band 3 was totally missing (\leftarrow). (D) Protein 4.2 was totally missing as well (\leftarrow). (E) There was a strong reduction of the GPA dimer (**) and a less pronounced decrease of the GPA monomer (*). The heterodimer GPA/GPB was nearly undetectable (\leftarrow). No obvious differences were recorded as for the other glycoproteins.

with long spike-like elongations (Figure 1A). Blood transfusion, intensive resuscitation, and assisted respiratory ventilation were immediately initiated after birth. During 6 weeks in the neonatal intensive care unit, the baby required continuous ventilation, drainage of the ascitic fluid, and exchange transfusion (taking severe hyperbilirubinemia into account). A hypertransfusion regimen was started because pretransfusion hemoglobin levels were rarely above 6.5 g/L. Erythroblasts and nucleated red blood cells with scant and irregular cytoplasm were present. Iron chelating treatment was initiated when the serum ferritin concentration reached 800 ng/L (8-12 hours of intravenous infusion of desferrioxamine [40 mg/kg] twice a week).

Hyperchloremic metabolic acidosis was detected by the age of 3 months. The infant received oral sodium bicarbonate (8 mEq/kg daily) and subsequently also received monopotassium phosphate. Soon after the discovery of blood acidosis, ultrasound showed the onset of nephrocalcinosis. Correcting the acidosis led to the normalization of calciuria. Nephrocalcinosis subsequently remained stable without impairment of glomerular filtration.

Psychomotor development was slightly delayed, but there appeared to be no increased susceptibility to infection, no neurologic abnormality, no hearing impairment, and no thrombotic tendency. At the age of 3, the child was doing reasonably well.

Red cells were obtained from umbilical cord and peripheral blood before the first transfusion. Sodium dodecyl sulfate-polyacrylamide gel electrophoresis and Western blotting of membrane proteins and DNA analysis were carried out as described before,¹ with minor modifications. Characterizations of the renal acidosis were based on standard methodologies.¹⁴⁻¹⁶

Results and discussion

Polymerase chain reaction amplification of DNA from the child's white blood cells followed by *Nla*III digestion demonstrated homozygosity for mutation Coimbra. Band 3 and protein 4.2 were absent. Spectrin α and β chains and ankyrin were reduced (by about 43% and 57%, respectively) in comparison to protein 4.1, which was taken as a reference (Figure 1B-D). Band 6 was strongly diminished (Figure 1B), and glycophorin A was markedly decreased (Figure 1E). These features matched those described in 1 band 3 null mouse strain with a number of small differences.^{10,11}

The urine anion gap was positive, and the value of plasma K^+ was normal to decreased. The lowest urine pH after furosemide administration was 6.6. The urine/blood P_{CO_2} gradient was less than 20 mm Hg after $NaHCO_3$ loading, the fractional excretion of HCO_3^- at normal plasma HCO_3^- concentration was 4%, and there was a high Ca^{++} urinary excretion (urinary Ca^{++} /creatinine ratio 1.2 mmol/mmol). These tests indicated a distal acidification defect (Table 1).

The child would probably have died had not an extensive knowledge of the family history and of the underlying mutation led to preparation for intensive care. The prognosis is uncertain, however. The transfusion demand will remain the same, necessitating the control of iron overload. Bone marrow transplantation with a compatible donor would represent the most satisfactory solution. In the meantime, a partial or total splenectomy is being considered to reduce transfusion requirements. DRTA has been corrected with

Table 1. Differential features of renal proximal or distal tubular acidosis and the patient's values

	Normal	Patient	Distal RTA	Proximal RTA
During metabolic acidosis (spontaneous)				
Plasma HCO_3^- (mEq/L)	18-22*	15	Low	Low
Plasma K^+ (mEq/L)	3.5-4.5*	3.5	Normal/low	Normal/low
Urine pH	< 5, 5†	7.3	> 5.5	< 5.5
Urine anion gap (mEq/L)	-31 \pm 23.5†	+ 64	Positive	Negative
Ca^{2+} /creat (u) (mmol/mmol)	< 0.7*	1.2	High	Normal
Furosemide test				
Minimum urine pH	4.99 \pm 0.3‡	6.6	> 5.5	< 5.5
During normal plasma				
HCO_3^- (after $NaHCO_3$ load)				
$FE_{HCO_3^-}$ (%)	< 3*	4	< 5	> 10-15
U- P_{PCO_2} (mm Hg)	> 20†	15.8	< 20	> 20
Presence of nephrocalcinosis or lithiasis				
		Present	Common	Rare

Urine anion gap, $(Na^+ + K^+ - Cl^-)$; Ca^{2+} /creat (u), urine calcium to creatinine ratio (mmol/mmol); $FE_{HCO_3^-}$, fractional excretion of bicarbonate; U- P_{PCO_2} , urine to blood P_{CO_2} gradient.

When a urine sample from a patient with hyperchloremic metabolic acidosis has a positive anion gap $(Na^+ + K^+ - Cl^-)$, a defect in distal urinary acidification is suspected. If the value of plasma K^+ is normal or decreased, the demonstration of the inability to lower urine pH below 5.5, either after NH_4Cl loading or after furosemide administration, establishes the diagnosis of distal acidosis. The diagnosis is further supported by a low urine/blood P_{CO_2} gradient (< 20 mm Hg) after $NaHCO_3$ loading. A fractional excretion of HCO_3^- at normal plasma HCO_3^- concentration exceeding 5% of the filtered load indicates the presence of a proximal defect in HCO_3^- reabsorption. To complete the diagnostic work-up, we searched for a rise in Ca^{2+} urinary excretion (urinary Ca^{2+} /creatinine ratio > 0.7 mmol/mmol) and nephrocalcinosis by ultrasound. These features are commonly found in association with distal acidosis.

*Data from Rodriguez-Soriano and Vallo.¹⁵

†Data from Dalton and Haycock.¹⁴

‡Data from Rodriguez-Soriano and Vallo.¹⁵

oral HCO_3^- supplementation, but nephrocalcinosis will persist and may cause renal failure.

A similar case of HS with missing band 3 has been identified.¹⁷ No DRTA occurred in this instance because the frameshift mutation only caused deletion of exon 2 and spared the renal isoform of band 3. This work shows that intensive treatment may keep a patient with total band 3 deficiency alive. Nevertheless, potential hematologic and renal complications can be quite severe. Thus, medical termination of pregnancy, as was done with the previous gestation, remains an alternative.

Acknowledgments

We thank the family studied here for their kind cooperation, the Prenatal Diagnosis Unit of the Maternidade Bissaya Barreto for assistance during the pregnancy, and Dr M. J. Julião for performing the postmortem examination of the fetus after the second pregnancy.

References

- Alloisio N, Texier P, Vallier A, et al. Modulation of clinical expression and band 3 deficiency in hereditary spherocytosis. *Blood* 1997;90:414.
- Ota K, Sakaguchi M, Hamasaki N, Mihara K. Assessment of topogenic functions of anticipated transmembrane segments of human band 3. *J Biol Chem*. 1998;273:28286.
- Bruce LJ, Cope DL, Jones GK, et al. Familial distal renal tubular acidosis is associated with mutations in the red cell anion exchanger (band 3, *AE1*) gene. *J Clin Invest*. 1997;100:1693.
- Jarolim P, Shayakul C, Prabakaran D, et al. Autosomal dominant distal renal tubular acidosis is associated in three families with heterozygosity for the R589H mutation in the *AE1* (band 3) $\text{Cl}^-/\text{CO}_3^-$ exchanger. *J Biol Chem*. 1998;273:6380.
- Karet FE, Gainza FJ, Györy AZ, et al. Mutations in the chloride-bicarbonate exchanger gene *AE1* cause autosomal dominant but not autosomal recessive distal renal tubular acidosis. *Proc Natl Acad Sci U S A*. 1998;95:6337.
- Rysava R, Tesar V, Jiras M Jr, Brabec V, Jarolim P. Incomplete distal renal tubular acidosis co-inherited with a mutation in the band 3 (*AE1*) gene. *Nephrol Dial Transplant*. 1997;12:1869.
- Lima PRM, Gontijo JAR, Lopes de Faria JB, Costa FF, Saad STO. Band 3 Campinas: a novel splicing mutation in the band 3 gene (*AE1*) associated with hereditary spherocytosis. Hyperactivity of the Na^+/Li^+ countertransport and an abnormal renal bicarbonate handling. *Blood*. 1997;90:2810.
- Inaba M, Yawata A, Koshino I, et al. Defective anion transport and marked spherocytosis with membrane instability caused by hereditary total deficiency of red cell band 3 in cattle due to a nonsense mutation. *J Clin Invest*. 1996;97:1804.
- Peters LL, Shivdasani RA, Liu SC, et al. Anion exchanger 1 (band 3) is required to prevent erythrocyte surface loss but not to form the membrane skeleton. *Cell*. 1996;86:917.
- Southgate CD, Chishti AH, Mitchell B, Yi SJ, Palek J. Targeted disruption of the murine erythroid band 3 gene results in spherocytosis and severe hemolytic anemia despite a normal membrane skeleton. *Nature Genet*. 1996;14:227.
- Hassoun H, Hanada T, Lutchman M, et al. Complete deficiency of glycophorin A in red blood cells from mice with targeted inactivation of the band 3 (*AE1*) gene. *Blood*. 1998;91:2146.
- Hassoun H, Wang Y, Vassiliadis J, et al. Targeted inactivation of murine band 3 (*AE1*) gene produces a hypercoagulable state causing widespread thrombosis in vivo. *Blood*. 1998;92:1785.
- Ribeiro ML, Alloisio N, Almeida H, et al. Hereditary spherocytosis with total absence of band 3 in a baby with mutation Coimbra (V488M) in the homozygous state (abstract). *Blood*. 1997;90(suppl):265a.
- Rodriguez-Soriano J, Vallo A. Renal tubular acidosis. *Pediatr Nephrol*. 1990;4:268.
- Dalton RN, Haycock GB. Laboratory investigation. In: Holliday MA, Barrat TM, Avner ED, eds. *Pediatric Nephrology*. Baltimore: Williams & Wilkins; 1994:397.
- Rodriguez-Soriano J, Vallo A. Renal tubular hyperkalemia in childhood. *Pediatr Nephrol*. 1988;2:498.
- Perrotta S, Nigro V, Iolascon A, et al. Dominant hereditary spherocytosis due to band 3 Neapolis produces a life-threatening anemia at the homozygous state (abstract). *Blood*. 1998;92(suppl):9a.