

# Mycophenolate mofetil in chronic glomerular diseases

H. Oliveira Sá and T. Mendes\*

Serviço Nefrologia (Dr. Dr. Mário Campos). Hospital da Universidade Coimbra. \*Serviço de Nefrologia (Dir. Dr. Armando Carreira). Centro Hospitalar de Coimbra. Portugal.

*Nefrología* 2008; 28 (1) 82-92

## INTRODUCTION

Mycophenolate mofetil (MMF), the first pharmaceutical prodrug of mycophenolic acid (MPA) that received approval for human clinical use, has been utilised in solid organ transplantation since 1995, particularly in kidney transplantation. MMF launching occurred one hundred years after MPA discovery as a fermentation product of *Penicillium Brevicompactum* and related fungi in 1893<sup>1</sup>. Since 2002, MMF is the more frequent immunosuppressant used in solid organ transplantation. In kidney transplantation the antimetabolite MMF assumed a very important role in immunosuppressive regimens, with 80% of end-stage renal patients receiving MMF at hospital discharge after kidney transplantation in EUA<sup>2</sup>. The other prodrug of MPA, the enteric coated mycophenolate sodium (EC-MPAS), has been introduced in transplantation drug market in 2004. Clinical experience with this formulation is significantly lower than MMF, both in organ transplantation and other human autoimmune diseases, so we focus this review on the clinical use of MMF in kidney glomerular diseases other than kidney transplantation.

There is clinical rationale in trying to profit from MMF properties to treat or arrest the progression of many chronic glomerular diseases. In fact MPA which selectively inhibits B and T lymphocyte proliferation acts as a blocker of the inosine monophosphate dehydrogenase enzyme of the *de novo* purine synthesis and is characterized by other properties that support its use in glomerular diseases that progress to ESRD. These mechanisms are the impairment of antigen presentation by dendritic cells, the suppression of monocyte recruitment and of the glycosylation of adhesion molecules, the inhibition of vascular smooth muscle cell proliferation and of cytokine induced nitric oxide production. Mycophenolate mofetil has also demonstrated synergistic effects with angiotensin II inhibitors (ACE or ARA) in retarding the progression of chronic renal diseases in experimental animal models<sup>3,4</sup>.

Although there is theoretical support to use MMF in chronic glomerular diseases, we have to wait for the conclusion of adequately powered long-term randomized and controlled clinical trials before it should receive approval for the

treatment of chronic glomerular diseases. At present time, MMF use for treatment of renal diseases other than kidney transplantation is supported by evidence-based medicine. This review intends to be a comprehensive summary of the main MMF indications in chronic glomerular diseases based on clinical and laboratorial evidence nowadays. MMF indications in different kind of glomerular diseases are presented in decrescent schedule, according to the strength of the evidence of its benefit, as showed in schematic picture of figure 1.

## LUPUS NEPHRITIS

The immunosuppressive treatment of lupus nephritis (LN) showed a significantly improvement in last decades due primarily to cyclophosphamide (CYC) use, but it is still very far from the ideal therapy. The high rate of complications associated with CYC therapy including infection, malignant disease, gonadal failure and alopecia, make clinicians interested in finding another less toxic alternatives. There is also concern about cases of resistance to cytotoxic therapy and frequent relapses of active nephritis that forces us to look for another drug with a more favourable profile both on efficacy and tolerability<sup>5</sup>. There is increasing evidence suggesting that MMF could be this alternative, as we can see in further demonstration of MMF efficacy in some randomized and controlled clinical trials on proliferative and membranous LN<sup>6-13</sup>. Recent meta-analysis about this matter support an important role for MMF in lupus nephritis<sup>14-16</sup>. Azathioprine (AZA), a less toxic immunosuppressive drug is not a good alternative to CYC for LN, especially as a remission induction therapy, as recently confirmed by data of a controlled randomized clinical trial conducted by Grootsholten G et al, with a follow-up of 2 years<sup>17</sup>.

Proliferative Lupus Nephritis (Classes III and IV)

## REMISSION INDUCTION THERAPY

Standard therapy to proliferative LN (Classes III and IV) based upon a series of randomized controlled trials at the EUA National Institutes of Health (NIH), has been a regimen consisting of six monthly pulses of intravenous CYC (0,5-1 g/m<sup>2</sup>) followed by subsequent trimestral intravenous CYC pulses for two years. The combination of this regimen with monthly intravenous metilprednisolone could contribute to higher efficacy concerning long term renal outco-

**Correspondence:** Helena Sá  
 helena.oliveirasa@sapo.pt  
 Hospital da Universidade de Coimbra. Praceta Mota Pinto  
 3000-075 Coimbra. Portugal

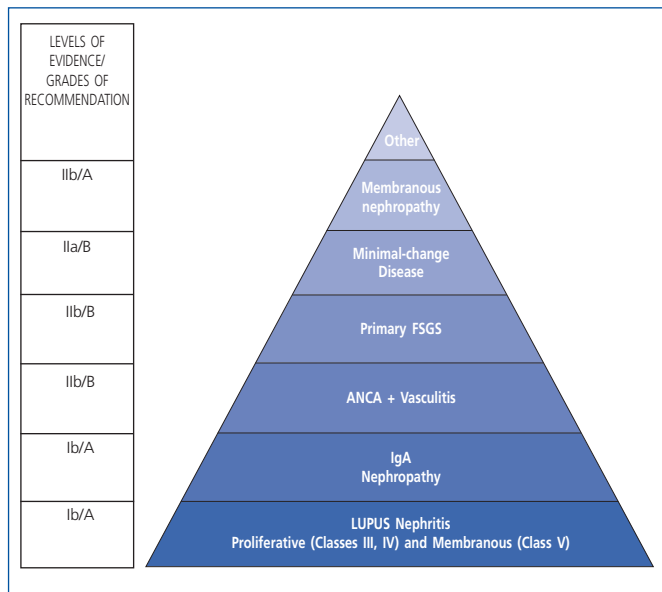
mes<sup>18,19</sup>. To obviate adverse toxic events with this standard regimen, an European based multicenter prospective trial was designed, the European-Lupus Nephritis trial. This clinical trial provided relevant data that allows us to safely use lower and shorter doses of CYC (fixed intravenous pulses of 500 mg every 2 weeks for a total of six doses followed by oral azathioprine as maintenance therapy) to induce the remission of proliferative LN, in particular in case of less severe renal injury<sup>20</sup>.

There are some important controlled prospective studies conducted to evaluate the efficacy and tolerability of MMF in induction therapy of proliferative LN that have been published<sup>6-13</sup>. There are other several randomized controlled clinical trials underway at the moment to clarify definitively MMF role on the treatment of LN. Data of the already published trials are heartening to support MMF use in induction remission of LN, in particular in case of less severe renal injury. The most important limitations of these studies are the selective population of Asiatic patients, the few number of patients in each arm of the studied groups and the short follow-up. One of these trials, randomized, conducted by Chan T et al, compared induction of remission of proliferative lupus nephritis with MMF (2 g a day) to oral CYC (2,5 mg/kg/d) for 6 months, both with oral prednisolone, in a Chinese population of 42 patients. At 6 months and during the maintenance therapy, those in the MMF group continued on MMF with smaller doses (1 g/day) and those in CYC group were switched to azathioprine (1,5 mg/kg/day)<sup>6</sup>. Data have been evaluated and published first at 12 months of follow-up, then more recently at 63 months of follow-up, with the same favourable results on renal outcomes<sup>10</sup>. The main conclusion of this trial and its expansion analysis was that MMF associated with prednisolone was as effective as a regimen of CYC and prednisolone followed by AZA but less toxic (less incidence of infection).

Another prospective trial, controlled but not randomized, published by Hu et al in 2002 about MMF use in induction therapy of LN, compared 6 months of oral MMF (1-1,5 g/day) with pulses of intravenous CYC in 46 Chinese patients with diffuse proliferative LN, both groups receiving supplemental steroid treatment<sup>7</sup>. The investigation lead the authors to conclude that MMF was more effective than CYC in controlling renal outcomes (reduction of proteinuria and hematuria, immunologic parameters of lupus activity like anti-DNA<sub>ds</sub> and histologic signs of vascular injury in serial renal biopsies) and less toxic (especially gastrointestinal symptoms and infections). The nonrandomized nature of this study and the short follow-up (6 months) preclude any definitive conclusions. Other randomized controlled study comparing pulse intravenous CYC versus oral MMF in the induction therapy of proliferative LN was recently published by Ong LM et al<sup>11</sup>. They studied 44 patients with 6 months of follow-up. The main conclusion of this trial was that MMF at doses of 2 g/day in combination with steroids was as effective induction therapy as monthly intravenous CYC (0,75-1 g/m<sup>2</sup>), at least for moderately severe proliferative LN. Ginzler EM et al published data of the larger randomized controlled trial comparing oral MMF to monthly intravenous pulses of CYC in remission induction of lupus nephritis<sup>12</sup>. They studied a population of 140 patients with LN at high risk for renal failure. Forty six percent of studied patients were Afro-americans and 54% had diffuse proliferative nephritis at renal histology. The main limitations of this study was a short follow-up of 6 months, the fact that in the CYC group steroid pulses were not used (the standard therapy for severe LN) and finally, the fact that more than half of all patients did not reached the end of the study. We have also to assinalate that 27 of the 140 patients had pure membranous lupus. In this trial, MMF therapy was more effective than intravenous CYC in inducing remissions of LN and it was associated with less adverse events. At 6 months of follow-up there was an absolute difference of 16,7 percentage points between the number of patients who achieve complete remission on the MMF arm and those on the intravenous CYC arm (95% CI, p = 0,005).

In summary, there are some controlled randomized trials that support the option of MMF to induce remission in LN instead of intravenous CYC, especially in case of less severe renal injury. This was elegantly summarized by Stassen PM et al.<sup>21</sup> In cases with rapidly progressive nephritis and acute renal failure, there are no definitive results to support MMF use and we must choose CYC and steroid pulses. Waldman M in a recent, excellent review about lupus nephritis treatment, suggests MMF therapy to induce remission in proliferative lupus nephritis at the same level of CYC, depending only of the severity of the disease and on the rigorous surveillance of the therapy resistance<sup>22</sup>. There are some recent data proving that MMF choice is associated with fewer adverse events compared to CYC and to better quality of life due to the reduced side-effects during MMF treatment<sup>13</sup>.

There are at least six larger and long term multicenter international trials underway to study efficacy and tolerability of MMF (or EC-MPA) as remission induction and maintenance therapy in lupus nephritis (NIH study numbers NCT



**Figure 1.** Chronic glomerulopathies in which MMF has been used with benefit. Diseases where evidence supporting its use is stronger are presented in the lower levels. At the left side, levels of evidence and grades of recommendation are shown for each category.

## continual medical education

00425438, 00298506, 00204022, 00423098, 00371319 and 00377637). These prospective, controlled and randomized trials including approximately 1,300 patients, will be concluded in the next decade, and would definitely clarify MMF approval for LN therapy.

### REMISSION MAINTENANCE THERAPY

There are a few trials dedicated to studying the ideal maintenance regimen in LN. What defines an optimum maintenance drug is its efficacy to avoid relapses associated with long term good tolerability. MMF has a favourable side-effect profile, as we can extrapolate from the organ transplantation trials. The beneficial effect of MMF as an antiproliferative drug, able to reduce vascular smooth muscle cells proliferation and to potentiate angiotensin II blockers, makes this prodrug very promising as a maintenance drug in LN<sup>3</sup>. The same can be thought about AZA although the comparison of this antimetabolite drug in maintenance therapy of lupus nephritis with MMF therapy is not yet well clarified.

The reference controlled randomized study concerning MMF use in maintenance therapy in lupus nephritis was published in 2004 by Contreras G et al<sup>8</sup>. They studied 59 patients with lupus nephritis (12 in class III, 46 in class IV and 1 in class V) that received induction therapy consisting of 6 monthly pulses of CYC (0,5-1 g/m<sup>2</sup>) plus oral corticosteroids and than were randomly assigned to one of three maintenance therapies: quarterly intravenous CYC (0,5-1 g/m<sup>2</sup>), oral AZA (1-3 mg/kg/day) or MMF (0,5-3 g/day) for one to three years. The results demonstrated that MMF and AZA groups showed better results on patient and renal survival than the CYC group. The relapse incidence was lower in MMF group compared with CYC group. In this study AZA seems to be a safer and effective long term maintenance therapy, in opposite with data about its effects in induction phase of lupus nephritis therapy<sup>17</sup>.

There are some prospective studies that demonstrated that MMF could be an useful alternative in the treatment of lupus nephritis in patients with failure, intolerance or relapses after treatment with CYC and steroids<sup>23,24</sup>. To clarify the primacy of these two drugs, MMF or AZA, on the maintenance therapy of proliferative LN, there is now underway a randomized, controlled trial, started at 2001 and that will be completed in 2011. This study, designed MAINTAIN Nephritis trial (NIH number NCT00204022) is expected to help us to conclude about MMF efficacy versus AZA for maintenance therapy of proliferative LN.

### MEMBRANOUS LUPUS NEPHRITIS (CLASS V)

Membranous LN is characterized by the presence of global or segmental continuous granular subepithelial immune deposits. Should we also find the presence of subendothelial immune deposits, then a combined diagnosis of LN class III or IV and V must be used, depending on their distribution (International Society of Nephrology/Renal Pathology Society guidelines, 2003)<sup>25</sup>. The treatment of LN with those characteristics should follow the recommendations of proliferative LN treatment. This is a clear change

in the way of categorizing this type of injury, as in the ancient WHO classification system the combined lesions were classified as Vc or Vd and treated like pure membranous nephritis<sup>25,26</sup>.

If, however, the renal biopsy shows a pure membranous feature (Class V LN), which is reported in 20% of the cases, the treatment of this entity remains unclear nowadays. There is anecdotal experience with all kinds of immunosuppressive and cytotoxic drugs in membranous LN, including cyclosporine (CsA), AZA, CYC, MMF, associated or not with corticosteroids (small uncontrolled series, retrospective studies, case reports)<sup>22,27-29</sup>. Data on MMF use in pure membranous LN is restricted to the prospective study of Ginzler EM mentioned before, in which 27 of the 140 patients had pure membranous LN<sup>12</sup>. The analysis of this subgroup results showed that MMF response was similar to intravenous monthly CYC response. There is underway another controlled randomized NIH study to investigate both MMF and tacrolimus drugs on the treatment of pure membranous LN (NCT00404794).

The natural evolution of membranous LN is variable, and perhaps, the less severe cases can be treated in a more conservative way. Appel GB *et al* recommended that pure membranous lupus nephritis should be treated according to proteinuria levels and glomerular filtration rate. Patients with subnephrotic levels of proteinuria and preserved glomerular filtration rate should be treated with a short course of CsA associated to low dose corticosteroids and to an inhibitor of the renin-angiotensin system and statins. For nephrotic patients, and those with reduced glomerular filtration rate, the alternatives are either CsA, intravenous monthly CYC, MMF or AZA<sup>22</sup>.

In summary, about MMF use for LN treatment, we conclude that for maintenance MMF seems an effective and secure option, although this statement is mainly based in one randomized controlled study of 140 patients, including patients either with proliferative and membranous lesions<sup>12</sup>. For induction therapy, in proliferative LN, there are more controlled randomized studies designed to assigne MMF primacy, but all of them with some kind of limitations: a small number of studied patients, a high number of asiatic patients, less severe renal disease. Nevertheless, based on these studies results and beyond the limitations mentioned, MMF seems to be an adequate alternative to intravenous CYC for remission induction therapy (table I). As recommended by Appel GB, we could use MMF as first choice therapy in cases of lesser severity of renal disease and concern about side effects of CYC, and then keeping to monotorize outcomes and drug response. In case of drug resistance we must quickly switch to CYC<sup>22</sup>. The role of other biologic agents like rituximab in combination with MMF for induction therapy and maintenance in patients with proliferative LN, will be clarify by multi-center prospective randomized trials currently underway (NCT00282347).

### IGA NEPHROPATHY

Many advances in understanding the pathogenesis of IgA nephropathy have occurred in the last years. Genetic factors have been recognized that could explain certain familial

cases (e.g. gene loci 6q22-23)<sup>30,31</sup>. The undergalactosylation of IgA1 at the O-linked hinge region and its deposition in the mesangium is one of the processes best known, although the primary defect (B cell or galactosyltransferase enzyme defect) are not clearly defined<sup>32</sup>. 20-30% of patients with idiopathic IgA nephropathy will develop end-stage renal failure at 20 years. The main predictors of poor outcome are male gender, hypertension, persistent microscopic hematuria and the extent of proteinuria and renal insufficiency<sup>33</sup>. Specific treatment must be offered to those at risk for renal failure.

Standard therapy of IgA nephropathy in patients with predictors of poor outcome is the use of angiotensin blockade (ACE inhibitors and/or angiotensin receptor blockers ARB) with the aim of lowering blood pressure to values approximately of 110/70 mmHg and proteinuria of lower than 500 mg/day<sup>32,34</sup>.

Immunosuppressive agents should be used when the response to angiotensin blockers is not satisfactory<sup>33,35</sup>. Glucocorticoids have been largely studied in IgA nephropathy and are still a valid therapeutic option to reduce the risk for ESRD and proteinuria even when used only for 6 months<sup>36,37</sup>. The primary indication of steroids are the group of relatively well-preserved renal function (creatinine clearance > 70 ml/m) and moderate degree of proteinuria. Cytotoxic agents have also demonstrated efficacy in these cases but with more adverse events. The role of MMF in IgA nephropathy is not clearly established as the results of published studies are contradictory<sup>38-41</sup>. Although those trials are prospective, controlled and randomized, studies lack sufficient statistic power as few patients reached primary end-points. Two of them studied patients with moderate to advanced IgA nephropathy and compared MMF therapy with placebo in a total of 38 patients, did not show significant benefit of MMF in reducing proteinuria or preserving renal function<sup>39,41</sup>. The other two studies reported a total of 77 asiatic patients (chinese) and compare MMF to placebo or prednisone. There was a significant reduction in proteinuria in the MMF groups but without beneficial effect on renal insufficiency<sup>38,40</sup>. Follow-up in both of these studies was short, between 6 and 12 months.

There is currently underway at least 2 larger prospective randomized trials designed to clarify MMF role on IgA nephropathy treatment (NHI study number NCT 00318474 recruiting 200 patients and Dal Canton et al' study<sup>42</sup>).

In table 1 we hereby present a summary overview of the main clinical results of MMF use in the two groups of glomerular pathologies were randomized trials have been performed: Lupus nephritis and IgA Nephropathy.

### ANCA-POSITIVE VASCULITIS

ANCA-positive small vessel vasculitis included Wegener Granulomatosis, ANCA positive Churg-Strauss syndrome, microscopic polyangiitis and renal-limited small vessel vasculitis. These entities represent 7-8% of the total population of small-vessel vasculitis (systemic and renal limited) and are responsible for approximately 5% of cases of ESRD<sup>43</sup>. Aggressive therapy of these disorders with kidney involvement is absolutely determinant on the recovery of renal function, and frequently associated with pulmonary

injury. The treatment is divided in two primary clinical issues: remission induction and maintenance therapy.

### REMISSION INDUCTION THERAPY

Standard remission therapy in ANCA-positive small vessel vasculitis is intravenous pulses of methylprednisolone followed by CYC plus oral steroids. In dialysis-dependent patients and patients with pulmonary injury, plasmapheresis may be used instead of pulse intravenous methylprednisolone to induce remission of ANCA-positive small vessel vasculitis<sup>44</sup>. Controversy about use of intravenous pulses of CYC or on opposite oral CYC, was clarified by data from de Groot et al and the European Vasculitis Study Group (EUVAS) that compared intravenous CYC to oral CYC for induction of remission in ANCA positive vasculitis in a randomized trial (CYCLOPS); they concluded that, there was no significant difference of disease-free interval between the two groups and, therefore, there seems to be little benefit to recommend oral CYC as long term therapy<sup>45,46</sup>.

Cyclophosphamide therapy, either intravenous or oral, is not devoid of toxicity (35% of cases reporting severe adverse events) as well of insufficient response (30% relapse incidence); therefore, it's reasonable to find alternative drugs<sup>47</sup>. Methotrexate (MTX) is also being used during both induction and maintenance therapy phases of these forms of vasculitis but it's a drug with non negligible profile of toxicity<sup>45,48</sup>. There are anecdotal reports of success with the use of biologic agents like TNF blockers (infliximab) or the lymphocyte-depleting drugs (anti CD52 mAb and anti CD20 mAb) in refractory disease but the high risk of cancer and other serious adverse events associated with these therapies, dissuade us to continue to recommend them<sup>49,50</sup>. As an alternative to these biologic agents MMF has been tested only in uncontrolled series of patients, intolerant or refractory to standard therapy with CYC<sup>51-53</sup>. The results are not brilliant, but it must be emphasized that, due the severity of the renal disease in most cases and the natural reluctance to use a novel drug with uncertain efficacy, most of the studies have examined the use of MMF in cases of relapse or resistance to CYC therapy during the induction phase. In one of them, conducted by Joy MS et al, 12 patients with relapsing disease (n = 6) or non response (n = 6) to a course of 6 months of CYC, received MMF 1-1,5 g twice daily, for a total of 24 weeks plus oral corticoids<sup>53</sup>. Only 10 patients completed 12 months of evaluation. MMF treatment was well tolerated, with only transient effects related mostly to gastrointestinal intolerance. In spite a good response, in what it concerns vasculitis disease activity with MMF therapy in 9 of the 10 final patients evaluated, only a minority of these subjects achieved a long-lasting remission (3/10). The other behaved like short relapsers or poor responders. The authors manifest the opinion that MMF alone is unlikely to be an effective rescue therapy for subjects resistant to induction therapy with CYC. The other reports are also inconclusive about MMF benefit to induce remission in ANCA-positive small vessel vasculitis<sup>51,52</sup>. At the moment, there are underway 3 larger multicenter prospective controlled studies (2 randomized) to evaluate the efficacy of MMF in remission induction of ANCA-asso-

**Table I. Summary overview of the main clinical results of MMF randomized trials in Lupus Nephritis and IgA Nephropathy**

Author, year, reference	N. of patients	Mean follow-up	Main efficacy and safety outcomes
<b>Proliferative Lupus Nephritis</b>			
Chan TM et al 2000 <sup>6</sup> (randomized)	n = 42	12 months	CR: 16/21 CYC oral/AZA; 17/21 MMF PR: 3/21 CYC oral/AZA; 3/21 MMF Death: 2/21 CYC oral/AZA; 0/21 MMF Infections: 7/21 CYC oral/AZA; 4/21 MMF <i>MMF + prednisolone is as effective as CYC oral+ prednisolone followed by AZA in inducing CR or PR and less toxic.</i>
Chan TM et al 2005 <sup>10</sup> (randomized, extended long-term study)	n = 64 (42 from <sup>6</sup> )	63 months	CR: 23/30 CYC oral/AZA; 24/32 MMF PR: 7/30 CYC oral/AZA; 7/32 MMF Death: 2/30 CYC oral/AZA; 0/32 MMF Infections: 12/30 CYC oral/AZA; 4/32 MMF <i>MMF + prednisolone is more effective than CYC oral+prednisolone followed by AZA in terms of renal and patient survival and less toxic.</i>
Ginzler EM et al 2005 <sup>12</sup> (randomized)	n = 140	6 months	CR: 4/69 iv CYC; 16/71 MMF PR: 17/69 iv CYC; 21/71 MMF Death: 2/69 iv CYC; 0/71 MMF Infections: 68/75 iv CYC; 42/83 MMF <i>MMF is more effective than CYC pulse therapy in inducing remission and more safe.</i>
Ong LM et al 2005 <sup>11</sup> (randomized)	n = 44	6 months	CR: 3/25 iv CYC; 5/19 MMF PR: 10/25 iv CYC; 6/19 MMF Death: 0/25 iv CYC; 0/19 MMF Infections: 3/25 iv CYC; 3/19 MMF <i>MMF + corticosteroids is as effective and safer than CYC pulse therapy + corticosteroids as induction therapy.</i>
Contreras G et al 2004 <sup>9</sup> (randomized)	n = 59	72 months	CRF: 3/20 iv CYC; 1/20 MMF Relapse-free survival: 12/20 iv CYC; 17/20 MMF Death: 4/20 iv CYC; 1/20 MMF Infections: 15/20 iv CYC; 6/20 MMF <i>Maintenance with MMF following short-term CYC induction is as effective and safer than long-term CYC pulse therapy.</i>
<b>IgA Nephropathy</b>			
Chen X et al 2002, (randomized) <sup>38</sup>	n = 62	12 months	Reduction of proteinuria at 12 months: MMF 0,8 ± 0,8 g/24 h; corticosteroids: 1,4 ± 1,6 g/24 h, p < 0,05 Remission rate: MMF 44,1%; corticosteroids: 19,1%, p < 0,05 <i>MMF is more efficacious in reducing proteinuria than prednisone.</i>
Maes BD et al 2004 (randomized) <sup>39</sup>	n = 34	36 months	MMF vs control (ACEIs + placebo) <i>No beneficial effect of MMF on renal function outcome or proteinuria.</i>
Tang S et al 2005 (randomized) <sup>40</sup>	n = 40	18 months	Reduction of proteinuria by 50% or >: MMF 16/20; control (ACEIs, ARA): 6/20, p = 0,001 Rate of change of creatinine clearance: no difference MMF vs control (ACEIs,ARA) <i>MMF is effective in lowering proteinuria.</i>
Frisch G et al 2005 (randomized) <sup>41</sup>	n = 32	24 months	MMF vs control (ACEIs + placebo), mean baseline SCr 2,4 mg/dl <i>MMF not effective in reducing proteinuria nor modifying decrease of renal function in patients who have already moderate renal insufficiency.</i>

CR – Complete remission; PR – Partial remission; SCr- serum creatinine.

ciated vasculitis when compared to CYC (NIH trials numbers NCT00103792, NCT00414128, NCT00405860). On the background of the literature, and at the present time, data doesn't support MMF use as first option therapy to induce remission in ANCA associated vasculitis.

### REMISSION MAINTENANCE THERAPY

There is an important phase III controlled trial underway to compare MMF to AZA in remission maintenance phase of ANCA-positive small vessel vasculitis treatment after induction with CYC plus corticoids. This study is designed IM-

PROVE trial (NIH trial NCT00307645) and will be concluded in 2008. A number of several therapeutic options had been tried to get reasonable alternatives to CYC during the maintenance phase of the treatment, avoiding relapses of disease activity. Methotrexate is one of them but the results were poor, first of all due to increased risk for malignancy<sup>45,48</sup>. Azathioprine seems to be an alternative to sustained CYC therapy after remission achievement on vasculitis ANCA-positive, based on data of the literature. In fact the Cyclophosphamide versus Azathioprine for Remission in Generalized Vasculitis trial (CYCAZAREM) conducted by EUVAS Group, concluded that efficacy of AZA in combination with steroids is identical to CYC's for maintenance therapy, with well tolerability<sup>54</sup>.

Data about MMF efficacy for remission maintenance therapy in ANCA vasculitis are based on uncontrolled studies and case series. One of them, conducted by Langford CA et al reported a good tolerability but a high frequency of relapses (43% at 18 months of follow-up, n = 14)<sup>55</sup>. Another study by Koukoulaki M et al, concerning 29 patients, reinforced the high rate of long-term relapses when using MMF for remission maintenance in ANCA-associated vasculitis with renal involvement. The mean duration of MMF therapy was 20 months but 48,3% of patients relapsed at mean time of 14 months<sup>52</sup>. Nowack R et al described, in opposite, a small rate relapses with MMF use (1/11) although the period of follow-up was shorter (15 months) and the number of patients smaller (n = 11)<sup>56</sup>. Another uncontrolled study using MMF in relapsing or resistant ANCA-positive small vessel vasculitis, demonstrated a sustained reduction in Birmingham Vasculitis activity score in patients classified as disease relapsers<sup>53</sup>.

In summary, on the basis of current knowledge, for remission maintenance therapy in ANCA-positive small vessel vasculitis, AZA plus steroids seems a rationale choice to avoid sustained CYC therapy. As MMF experience for maintenance therapy is based on uncontrolled studies, we must wait until larger controlled studies are finalized to clarify the beneficial effects of MMF compared to AZA.

### PRIMARY FOCAL AND SEGMENTAL GLOMERULOSCLEROSIS (FSGS)

Primary FSGS is still a challenge to the nephrologist in terms of diagnostic and treatment. As said by Alain Meyrier in a recent review about this topic, FSGS is not a disease but a lesion of obscure pathophysiology, with different variants (tip, perihilar, cellular, collapsing and FSGS not otherwise specified or NOS)<sup>57</sup>. The primary defect seems to concentrate on glomerular epithelial cell function like podocytes, although in some types like collapsing variant of FSGS, parietal epithelial cell role is crucial in the proliferative events. In recent years, genetics of familial cases of FSGS have been clarified, contributing to a better understanding of pathogenesis of this common form of nephrotic syndrome (a podocytopathy with altered podocyte-specific proteins is commonly present: podocin/NPHS-2 gene, nephrin/NPHS-1 gene,  $\alpha$ -actinin 4/ACTN4 gene, CD2AP protein and gene, TRPC6 protein and gene, WT1 protein and gene)<sup>58</sup>.

Corticosteroids, administrated in high doses and for a prolonged course (for 3 to 6 months), remain the mainstay of treatment of primary FSGS. The best indicator of favorable prognosis is proteinuria reduction<sup>59</sup>. Cytotoxic agents like CYC and chlorambucil are specially indicated in case of steroid-dependency. Steroid-resistance nephrotic syndrome remains one of the leading causes of progression to end stage renal disease in FSGS. Cyclosporine (CsA) is an important therapeutic option in steroid resistant FSGS<sup>60</sup>. In pediatric population, CsA seems to have the beneficial effect of being a steroid-sparing agent, pushing a significant additional subsets of child into remission<sup>61</sup>. Cyclosporine must be used in low doses (lower than 5 mg/kg/day) associated with corticosteroids and for a prolonged course (frequently more than 18 months). The main problem with this kind of therapeutic is CsA-dependency, even to a very low daily dosage (as 1 mg/kg/day).

MMF clinical experience in FSGS is resumed to a few small uncontrolled studies and case series of patients with no response to other therapies (steroid and cyclosporine resistant) and with a short follow-up<sup>62-65</sup>. At the current time, MMF use in FSGS remains totally empirical. Choi MJ et al described MMF use in 18 patients with primary FSGS<sup>62</sup>. Indications for MMF treatment included steroid-resistance and steroid or cyclosporine-dependency associated with progressive renal insufficiency. Twelve of 18 patients received concomitant steroid treatment. They observed total remission in 2 patients and proteinuria reduction in 16. Corticosteroids were withdrawn completely in 8 of 12 patients. Day CJ et al studied seven patients with frequent relapses of nephrotic syndrome, despite treatment with CYC and/or CsA; they were treated with MMF 1g twice daily together with prednisolone<sup>63</sup>. Six patients went into complete remission and the seventh into partial remission. It must be emphasized that in this group of patients, only 2 had FSGS diagnostic on the renal biopsy, the others were diagnosed as having minimal-change disease, which can partially explain the favorable results. Montané B et al treated nine children and young adults with FSGS steroid resistance, that had failed conventional treatment regimens with MMF (250-500 mg/m<sup>2</sup> per day)<sup>64</sup>. This drug, in association with angiotensin blockade, was responsible for 72% reduction of proteinuria below baseline after 6 months of follow-up and this level was maintained for a minimum of 24 months of observation.

More recently, Cattran DC et al performed an open-label 6 months trial of MMF in 18 patients with corticosteroid-resistant nephrotic syndrome. Of these 18 patients, 75% had failed to respond to a cytotoxic and/or calcineurin inhibitor<sup>65</sup>. They observed a substantial improvement in proteinuria in 44% (8/18) of the patients by 6 months, although no one had a complete remission and relapses were frequently observed.

Controlled trials are required to establish the role of MMF on FSGS's treatment. An important randomized, controlled trial of FSGS is now occurring in the United States (NCT00135811). This trial intends to compare two different treatment regimens in biopsy-proven primary FSGS, namely CsA *versus* MMF/pulse steroids and has as primary objective

## continual medical education

to determine whether treatment with MMF/pulse steroids is superior to CsA in inducing remission from proteinuria over 12 months. The estimated number of patients being recruited ( $n = 500$ ) and the characteristics of the study are essential for our knowledge of MMF risk/benefit ratio on the treatment of FSGS.

### MINIMAL-CHANGE DISEASE

Minimal-Change Disease is found mostly in pediatric population (> 85% cases of nephrotic syndrome). In adults it accounts for approximately 10 to 15% of idiopathic nephrotic syndrome<sup>66</sup>. Minimal-Change Disease's pathognomonic lesion is the alteration of foot processes (effacement) that is observed on electron microscopy. Although primary Minimal-Change Disease has been described for decades, the pathogenesis of this kind of injury remains unknown. There are some hypothetic culprits that could explain the main histological alterations. Some of the proposed mechanisms are a cell circulating permeability factor like IL13, IL4 or the macrophage migration inhibitory factor and more recently, some oxygen species that could damage podocytes<sup>67-69</sup>.

Oral glucocorticoids remain the standard therapy in both adult and children Minimal-Change Disease. The steroid response is generally good: complete remissions are common with only < 7% of children and approximately 12% of adults being steroid-resistant. The problem is the elevated rate of relapses or the high incidence of steroid-dependency. Cyclophosphamide (2 mg/kg/day for 12 weeks) or CsA (3-6 mg/kg/day) are two alternatives to these subgroups of patients<sup>70</sup>. Concerns about this kind of therapy are the toxic adverse effects associated with these drugs, particularly with CYC, and the very common cyclosporine-dependency or cyclosporine-nephrotoxicity. This kind of concern is bigger in pediatric population where both steroid and CsA dependency compromise seriously the growth and long-term renal survival. Persecuting the aim of finding better alternatives to CYC and CsA in Minimal-Change Disease, some uncontrolled observations suggest that MMF therapy might have a beneficial role in the management of cases of steroid-dependency or steroid-resistance, and would help obviate the need for CYC or CsA's use, particularly in pediatric population<sup>62,71-73</sup>. Most part of the studies report to cases of steroid-dependency in children and, all together, they include approximately 100 patients<sup>74-80</sup>. The doses of MMF differed between 180 and 600 mg/m<sup>2</sup> body surface/dose twice daily. The findings in all of those uncontrolled studies indicate that MMF is a useful therapy in the treatment of patients with steroid-dependent nephrotic syndrome and well tolerated. MMF therapy in general, results in significant steroid or cyclosporine sparing. The results in steroid-resistant nephrotic syndrome were more disappointing<sup>78,79</sup>.

Based on these encouraging preliminary observations in steroid or CsA-dependency, mainly in pediatric population, clinicians may choose to treat steroid-dependent children early with MMF, avoiding the adverse effects of long term steroid or cyclosporine therapy. Experience in adult steroid-dependent or steroid-resistant nephrotic syndrome treated

with MMF is smaller, but still demonstrate similar clinical efficacy in steroid or cyclosporine sparing.

In the meantime, we have to wait until controlled clinical trials of MMF therapy in steroid dependent and steroid-resistant nephrotic syndrome due to Minimal-Change Disease and FSGS are available.

### MEMBRANOUS NEPHROPATHY

As well as Minimal-Change disease is the most common form of nephrotic syndrome in children, primary membranous nephropathy (MN) still remains the most common form of nephrotic syndrome in adults<sup>81</sup>. Membranous nephropathy's pathogenesis is associated to subepithelial deposits (endogen or exogen unknown antigen) and secondary activation of the complement with formation of the attack complex *in situ* that damages the overlying podocytes. To date, there is no MN's treatment based precisely on the known pathogenesis - as human trials with antiC5 (Eculizumab) have been inconclusive<sup>82,83</sup>. As wisely mentioned by Cattran DC, spontaneous remission occurs at a higher rate in this disease than in other primary progressive nephropathies (up to 30%)<sup>84</sup>. The high rate of spontaneous remission in this disease, suggests an auto-regulated mechanism of injury and repair, as long as the pathogenic process is not severe enough, to promote irreversible lesions on the glomerular structure and function. The other two thirds of patients that did not develop spontaneous remission, show either persistent proteinuria with long-term preservation of renal function or slow progression to renal failure<sup>85</sup>. These medium and high-risk patients need usually to be treated with immunosuppressive drugs that include alkylating agents together with steroids for 6 months or cyclosporine and steroids for 6-12 months<sup>60,86,87</sup>. There is no evidence for benefit with immunosuppressive therapy for those with sub-nephrotic range proteinuria, normal renal function or stage I or II disease on renal biopsy<sup>84</sup>. The importance of reaching remission of nephrotic syndrome in MN is overwhelming evident. Cattran DC et al determined in a cohort of 350 patients with nephrotic MN that 10 yr-renal survival was 100% in the complete remission group, 90% in the partial remission group and only 45% in the no remission group<sup>88</sup>.

In spite of the MN treatment guidelines with cytotoxic agents or cyclosporine, a recent well performed meta-analysis of the different therapeutic classes (glucocorticoids alone, various alkylating agents with or without glucocorticoids, calcineurin inhibitors either alone or with glicocorticoids and finally azathioprine on the antimetabolite class), that included 943 studies (only 18 randomized controlled trials) involving 1,025 patients, failed to show any long-term beneficial effect of any kind of treatment regimen on patient or renal survival<sup>89</sup>. This meta-analysis precluded the use of glucocorticoids alone in nephrotic MN in any case.

New therapeutic agents in MN have to demonstrate the contribute to ameliorate long-term renal survival besides the ability to decrease proteinuria.

Membranous nephropathy's treatment with MMF has been tried in several uncontrolled, nonrandomized trials that inclu-

de problematic cases of steroid or cytotoxic resistance. In the global, those uncontrolled studies report to 41 patients with a follow-up between 8 and 9 months of MMF therapy. Choi MJ et al used a median MMF range dose of 2 g/day and described a median Up/c decrease from 7,3 to 1,5 ( $p = 0,0001$ ) in 17 patients with steroid or cytotoxic resistant MN<sup>62</sup>. There were no significant change of serum creatinine or mean arterial pressure. Two patients of 17 achieved a complete remission. Miller G et al studied 16 nephrotic patients with MN treated for a mean of 8 months (MMF dose range 0,5 to 2 g/day)<sup>90</sup>. Partial remissions occurred in 2 of the 16 patients and 6 patients experienced a halving reduction of proteinuria. There were no changes in mean serum creatinine. Polenakovic M et al studied 8 patients with nephrotic MN treated for 9 months with MMF and described a significant reduction of proteinuria from 4,4 to 1,9 g/day<sup>91</sup>.

There are two nonrandomized prospective trials with historic controls and a follow-up of 12 months that aimed to compare MMF treatment in MN with patients treated with alkylating agents<sup>92,93</sup>. The first, described a significant and comparable reduction in proteinuria in the MMF group related to cytotoxic group but includes only 13 patients; the other, more recent and including 32 patients, although demonstrating a decrease of proteinuria and improved renal function with MMF therapy, wasn't as effective nor better tolerated than CYC therapy.

There is now underway a small controlled randomized trial designed to compare MMF associated with prednisolone to clorambucil plus prednisolone in MN (NIH trial NCT00404833).

To date and facing those discouraging results about immunosuppressive therapy in MN, including MMF, we might share Remuzzi G hope that new and better agents that attack the basic pathophysiology of MN are needed, namely therapy that target B cells (e.g., rituximab)<sup>94</sup> or synthetic ACTH<sup>95</sup>. Further trials with this kind of biological agents acting as a specific immunotherapy are required.

## OTHER GLOMERULAR DISEASES

There are a few references reporting MMF use in other primary or secondary glomerular diseases characterized by macrophage infiltration, overexpression of growth factors and proinflammatory cytokines, increase in protein excretion and/or renal insufficiency. Some of these studies as in diabetes mellitus, subtotal renal ablation syndrome and anti-membrane glomerular basement membrane glomerulonephritis are experimental<sup>96-101</sup>. The findings of these studies in rat models suggest a potential therapeutic role of MMF in the inhibition of glomerular inflammation and progression of renal histologic injury. There are anecdotal clinical reports about MMF use in patients with severe glomerular pathology refractory to conventional therapies that show some benefit on proteinuria remission and improvement of renal function. One of them included patients with primary membranoproliferative glomerulonephritis in which MMF contributes to renal insufficiency resolution in 20% of the cases<sup>102</sup>, the other reported a patient with Goodpasture's syndrome refractory to conventional therapy that went into stable remission with MMF therapy<sup>103</sup>.

## REFERENCES

- Gosio B. Sperimentate su culture pure di bacilli del carbonchio dimostreranno notevole potere antisettica. *C R Acad Med Torino* 1893; 61: 484.
- OPTN/SRTR Annual Report 2004. [http://www.ustransplant.org/annual\\_reports/archives/2004/data\\_tables.htm](http://www.ustransplant.org/annual_reports/archives/2004/data_tables.htm).
- Allison AC and Eugui EM. Mechanisms of action of mycophenolate mofetil in preventing acute and chronic allograft rejection. *Transplantation Suppl* 2005; 80 (2S): S181-90.
- Badid C, Desmouliere A and Lavilli M. Mycophenolate mofetil: implications for the treatment of glomerular disease. *Nephrol Dial Transplant* 2001; 16: 1752-6.
- McCune WJ. Mycophenolate mofetil for lupus nephritis. *New Engl J Med* 2005; Nov 24; 353 (21): 2282-4.
- Chan TM, Li FK, Tang CS, Wong RW, Fang GX, Ji YL et al. Efficacy of mycophenolate mofetil in patients with diffuse proliferative lupus nephritis. Hong Kong-Guangzhou Nephrology Study Group. *N Engl J Med* 2000; 343: 1156-1162.
- Hu W, Liu Z, Chen H, Tang Z, Wang Q, Shen K and Li L. Mycophenolate mofetil vs cyclophosphamide therapy for patients with diffuse proliferative lupus nephritis. *Chin Med J (England)* 2002; 115: 705-9.
- Contreras G, Pardo V, Leclercq B, Lenz O, Tozman E, O'Nan et al. *N Engl J Med* 2004; 350: 971-80.
- Contreras G, Tozman E, Nahar N and Metz D. Maintenance therapies for proliferative lupus nephritis: mycophenolate mofetil, azathioprine and intravenous cyclophosphamide. *Lupus* 2005; 14 Suppl 1: s33-8.
- Chan TM, Tse KC, Tang CS, Mok MY, Li FK; Hong-Kong Nephrology Study Group. Long-term study of mycophenolate mofetil as continuous induction and maintenance treatment for diffuse proliferative lupus nephritis. *J Am Soc Nephrol* 2005; 16 (4): 1076-84.
- Ong LM, Hooi LS, Lim TO, Goh BL, Ahmad G, Ghazalli R et al. Randomized controlled trial of pulse intravenous cyclophosphamide versus mycophenolate mofetil in the induction therapy of proliferative lupus nephritis. *Nephrology (Carlton)* 2005; 10 (5): 504-10.
- Ginzler EM, Dooley MA, Aranow C, Kim MY, Buyon J, Merrill JT et al. Mycophenolate mofetil or intravenous cyclophosphamide for lupus nephritis. *N Engl J Med* 2005 Nov 24; 353 (21): 2219-28.
- Tse KC, Tang CS, Lio WI, Lam MF and Chan TM. Quality of life comparison between corticosteroid-and-mycophenolate mofetil and corticosteroid-and-oral cyclophosphamide in the treatment of severe lupus nephritis. *Lupus* 2006; 15 (6): 371-9.
- Zhu B, Chen N, Lin Y, Ren H, Zhang W, Wang W et al. Mycophenolate mofetil in induction and maintenance therapy of severe lupus nephritis: a meta-analysis of randomized controlled trials. *Nephrol Dial Transplant* 2007; 22 (7): 1933-42.
- Moore RA and Derry S. Systematic review and meta-analysis of randomized trials and cohort studies of mycophenolate mofetil in lupus nephritis. *Arthritis Res Ther* 2006; 8 (6): R182.
- Walsh M, James M, Jayne D, Tonelli M, Manns BJ and Hemmelgarn BR. Mycophenolate mofetil for induction therapy of lupus nephritis: a systematic review and meta-analysis. *Clin J Am Soc Nephrol* 2007; 2: 968-75.
- Grootsholten C, Ligtenberg G, Hagen EC, Van den Wall Bake AW, Glas-Vos JW, Bijl M et al. Azathioprine/methylprednisolone versus cyclophosphamide in proliferative lupus nephritis. A randomized controlled trial. *Kidney Int* 2006; 70 (4): 732-42.
- Boumpas DT, Austin HA, Vaughn EM, Klippel JH, Steinberg AD, Yarboro CH et al. Controlled trial of pulse methylprednisolone versus two regimens of pulse cyclophosphamide in severe lupus nephritis. *Lancet* 1992; 340: 741-5.
- Illei GG, Austin HA, Crane M, Collins L, Gourley MF, Yarboro CH et al. Combination therapy with pulse cyclophosphamide plus pulse methylprednisolone improves long-term renal outcome without adding toxicity in patients with lupus nephritis. *Ann Intern Med* 2001; 135: 248-57.
- Houssiau FA, Vasconcelos C, D'Cruz D, Sebastiani GD, Garrido Ed Ede R, Danieli MG et al. Immunosuppressive therapy in lupus nephritis: the Euro-Lupus Nephritis Trial, a randomized trial of low-dose versus high-dose intravenous cyclophosphamide. *Arthritis Rheum* 2002; 46: 2121-31.



21. Stassen PM, Kallenberg CGM and Stegeman CA. Use of mycophenolate acid in non-transplant renal diseases. *Nephrol Dial Transplant* 2007; 22: 1013-19.
22. Waldman M and Appel GB. Update of the treatment of lupus nephritis. *Kidney Int* 2006; 70: 1403-12.
23. Segarra A, Amoedo ML, Martínez García JM, Pons S, Praga M, García EI et al. Efficacy and safety of «rescue therapy» with mycophenolate mofetil in resistant primary glomerulonephritis —a multicenter study. *Nephrol Dial Transplant* 2007; 22 (5): 1351-60.
24. Suría S and Checa MD. Mycophenolate mofetil in the treatment of lupus nephritis, in patients with failure, intolerance or relapses after treatment with steroids and cyclophosphamide. *Nefrología* 2007; 27 (4): 459-65.
25. Weening JJ, D'Agati VD, Schwartz MM, Seshan SV, Alpers CE, Appel GB et al. The classification of Glomerulonephritis in systemic lupus erythematosus revisited. *J Am Soc Nephrol* 2004; 15: 241-50.
26. Appel GB, Silva FG, Pirani CL, Meltzer JI and Estes D. Renal involvement in systemic lupus erythematosus (SLE): a study of 56 patients emphasizing histologic classification. *Medicine (Baltimore)* 1978; 57 (5): 371-410.
27. Chan TM, Li FK, Hao WK, Chan KW, Lui SL, Tanq S et al. Treatment of membranous lupus nephritis with nephrotic syndrome by sequential immunosuppression. *Lupus* 1999; 8: 545-51.
28. Hu W, Liu Z, Shen S, Li S, Yao X, Chen H et al. Cyclosporine A in treatment of membranous lupus nephropathy. *Chi Med J (England)* 2003; 116: 1827-30.
29. Mok CC, Ying KY, Lau CS, Yim CW, Nq WL, Wong WS et al. Treatment of membranous lupus nephropathy with prednisone and azathioprine: an open-label trial. *Am J Kidney Dis* 2004; 43: 269-76.
30. Suzuki H, Suzuki Y, Yamanaka T, Hirose S, Nishimura H, Toei J et al. Genome-wide scan in a novel IgA nephropathy model identifies a susceptibility locus on murine chromosome 10, in a region syntenic to human IGAN1 on chromosome 6q22-23. *J Am Soc Nephrol* 2005 May; 16 (5): 1289-99.
31. Schena FP, Cerullo G, Torres DD, Scolari F, Foramitti M, Amoroso A, Pirulli D, Floege J, Mertens PR, Zerres K, Alexopoulos E, Kirmizis D, Zelante L, Bisceglia L, Ghiggeri GM, Frascà GM; European IgA nephropathy Consortium. The IgA nephropathy Biobank. An important starting point for the genetic dissection of a complex trait. *BMC Nephrol* 2005 Dec 5; 6:14.
32. Floege J and Feehally J. IgA nephropathy: recent developments. *J Am Soc Nephrol* 2000 Dec; 11 (12): 2395-403.
33. Appel GB, Waldman M. The IgA nephropathy treatment dilemma. *Kidney Int* 2006 Jun; 69 (11): 1939-44.
34. Kanno Y, Okada H, Yamaji Y, Nakazato Y, Suzuki H. Angiotensin-converting-enzyme inhibitors slow renal decline in IgA nephropathy, independent of tubulointerstitial fibrosis at presentation. *QJM* 2005 Mar; 98 (3): 199-203.
35. Samuels JA, Strippoli GF, Craig JC, Schena FP, Molony DA. Immunosuppressive treatments for immunoglobulin A nephropathy: a meta-analysis of randomized controlled trials. *Nephrology (Carlton)* 2004 Aug; 9 (4): 177-85.
36. Pozzi C, Bolasco PG, Fogazzi GB, Andrulli S, Altieri P, Ponticelli C, Locatelli F. Corticosteroids in IgA nephropathy: a randomized controlled trial. *Lancet* 1999 Mar 13; 353 (9156): 883-7.
37. Pozzi C, Andrulli S, Del Vecchio L, Melis P, Fogazzi GB, Altieri P, Ponticelli C, Locatelli F. Corticosteroid effectiveness in IgA nephropathy: long-term results of a randomized, controlled trial. *J Am Soc Nephrol* 2004 Jan; 15 (1): 157-63.
38. Chen X, Chen P, Cai G, Wu J, Cui Y, Zhang Y, Liu S, Tang L. [A randomized control trial of mycophenolate mofetil treatment in severe IgA nephropathy]. *Zhonghua Yi Xue Za Zhi* 2002 Jun 25; 82 (12): 796-801.
39. Maes BD, Oyen R, Claes K, Evenepoel P, Kuypers D, Vanwalleghem J, Van Damme B, Vanrenterghem YF. Mycophenolate mofetil in IgA nephropathy: results of a 3-year prospective placebo-controlled randomized study. *Kidney Int* 2004 May; 65 (5): 1842-9.
40. Tang S, Leung JC, Chan LY, Lui YH, Tang CS, Kan CH et al. Mycophenolate mofetil alleviates persistent proteinuria in IgA nephropathy. *Kidney Int* 2005 Aug; 68 (2): 802-12.
41. Frisch G, Lin J, Rosenstock J, Markowitz G, D'Agati V, Radhakrishnan J et al. Mycophenolate mofetil (MMF) vs placebo in patients with moderately advanced IgA nephropathy: a double-blind randomized controlled trial. *Nephrol Dial Transplant* 2005 Oct; 20 (10): 2139-45.
42. Dal Canton A, Amore A, Barbano G, Coppo R, Emma F, Grandaliano G, Klersy C, Perfumo F, Rizzoni G, Schena FP, Sepe V; Angiotensin Inhibition Mycophenolate mofetil IgA Nephropathy study investigators. One-year angiotensin-converting enzyme inhibition plus mycophenolate mofetil immunosuppression in the course of early IgA nephropathy: a multicenter, randomized, controlled study. *J Nephrol* 2005 Mar-Apr; 18 (2): 136-40.
43. Booth AD, Pusey CD and Jayne DR. Renal vasculitis —an update in 2004. *Nephrol Dial Transplant* 2004; 19 (8): 1964-8.
44. Jayne DR and Rasmussen N. Treatment of antineutrophil cytoplasm autoantibody-associated systemic vasculitis: initiatives of the European Community Systemic Vasculitis Clinical Trials Study Group. *Mayo Clin Proc* 1997 Aug; 72 (8): 737-47.
45. De Groot K, Adu D, Savage CO; EUVAS (European vasculitis study group). The value of pulse cyclophosphamide in ANCA-associated vasculitis: meta-analysis and critical review. *Nephrol Dial Transplant* 2001 Oct; 16 (10): 2018-27.
46. De Groot K, Jayne D. What is new in the therapy of ANCA-associated vasculitides? Take home messages from the 12<sup>th</sup> workshop on ANCA and systemic vasculitides. *Clin Nephrol* 2005 Dec; 64 (6): 480-4.
47. Nachman PH, Hogan SL, Jennette JC and Falk RJ. Treatment response and relapse in antineutrophil cytoplasmic autoantibody-associated microscopic polyangiitis and glomerulonephritis. *J Am Soc Nephrol* 1996; 7: 33-9.
48. De Groot K, Rasmussen N, Bacon PA, Tervaert JW, Feighery C, Gregorini G, Gross WL, Luqmani R, Jayne DR. Randomized trial of cyclophosphamide versus methotrexate for induction of remission in early systemic antineutrophil cytoplasmic antibody-associated vasculitis. *Arthritis Rheum* 2005 Aug; 52 (8): 2461-9.
49. Wegener's Granulomatosis Etanercept Trial (WGET) Research Group. Etanercept plus standard therapy for Wegener's granulomatosis. *N Engl J Med* 2005 Jan 27; 352 (4): 351-61.
50. Clatworthy MR and Jayne DR. Acquired hemophilia in association with ANCA-associated vasculitis: response to rituximab. *Am J Kidney Dis* 2006 Apr; 47 (4): 680-2.
51. Stassen PM, Cohen Tervaert JW, Stegeman CA. Induction of remission in active ANCA-associated vasculitis with mycophenolate mofetil (abstract). *Kidney Blood Press Res* 2003; 26 (4): 292.
52. Koukoulaki M and Jayne DR. Mycophenolate mofetil in anti-neutrophil cytoplasm antibodies-associated systemic vasculitis. *Nephron Clin Pract* 2005; 102: c100-7.
53. Joy MS, Hogan SL, Jennette JC, Falk RJ and Nachman PH. A pilot study using mycophenolate in relapsing or resistant ANCA small vessel vasculitis. *Nephrol Dial Transplant* 2005 Dec; 20 (12): 2725-32.
54. Jayne D, Rasmussen N, Andrassy K, Bacon P, Tervaert JW, Dadonienė J et al. European Vasculitis Study Group. A randomized trial of maintenance therapy for vasculitis associated with antineutrophil cytoplasmic autoantibodies. *N Engl J Med* 2003 Jul 3; 349 (1): 36-44.
55. Langford CA, Talar-Williams C, Sneller MC. Mycophenolate mofetil for remission maintenance in the treatment of Wegener's granulomatosis. *Arthritis Rheum* 2004 Apr 15; 51 (2): 278-83.
56. Nowack R, Gobel U, Klooker P, Hergesell O, Andrassy K, Van der Woude FJ. Mycophenolate mofetil for maintenance therapy of Wegener's granulomatosis and microscopic polyangiitis: a pilot study in 11 patients with renal involvement. *J Am Soc Nephrol* 1999; 10: 1965-71.
57. Meyrier A. Nephrotic focal segmental glomerulosclerosis in 2004: an update. *Nephrol Dial Transplant* 2004; 19: 2437-44.
58. Tryggvason K, Patrakka J, Wartiovaara J. Hereditary proteinuria syndromes and mechanisms of proteinuria. *N Engl J Med* 2006 Mar 30; 354 (13): 1387-401.
59. Troyanov S, Wall CA, Miller JA, Scholey JW, Cattran DC for the Toronto Glomerulonephritis Registry Group Focal and Segmental

- Glomerulosclerosis: Definition and Relevance of a Partial Remission. *J Am Soc Nephrol* 2005; 16: 1061-8.
60. Quereda C, Ballarín J, Galeano C, García López F and Praga M. Immunosuppressive therapy of primary focal sclerosing glomerulonephritis in the adult: a systematic review. *Nefrologia* 2007; 27 (3): 249-60.
  61. BM Tune and SA Mendoza. Treatment of the idiopathic nephrotic syndrome: regimens and outcomes in children and adults. *J Am Soc Nephrol* 1997; 8: 824-32.
  62. Choi MJ, Eustace JA, Giménez LF, Atta MG, Scheel PJ, Sothianathan R et al. Mycophenolate mofetil treatment for primary glomerular diseases. *Kidney Int* 2002 Mar; 61 (3): 1098-114.
  63. Day CJ, Cockwell P, Lipkin GW, Savage CO, Howie AJ and Adu D. Mycophenolate mofetil in the treatment of resistant idiopathic nephrotic syndrome. *Nephrol Dial Transplant* 2002 Nov; 17 (11): 2011-3.
  64. Montané B, Abitbol C, Chandar J, Strauss J and Zilleruelo G. Novel therapy of focal glomerulosclerosis with mycophenolate and angiotensin blockade. *Pediatr Nephrol* 2003 Aug; 18 (8): 772-7.
  65. Cattran DC, Wang MM, Appel G, Matalon A and Briggs W. Mycophenolate mofetil in the treatment of focal segmental glomerulosclerosis. *Clin Nephrol* 2004 Dec; 62 (6): 405-11.
  66. Waldman M, Crew RJ, Valeri A, Busch J, Stokes B, Markowitz G et al. Adult minimal-change disease: clinical characteristics, treatment, and outcomes. *Clin J Am Soc Nephrol* 2007 May; 2 (3): 445-53.
  67. Grimbirt P, Audard V, Remy P, Lang P and Sahali D. Recent approaches to the pathogenesis of minimal-change nephrotic syndrome. *Nephrol Dial Transplant* 2003 Feb; 18 (2): 245-8.
  68. Acharya B, Shirakawa T, Pungky A, Damanik P, Massi MN, Miyata M et al. Polymorphism of the interleukin-4, interleukin-13, and signal transducer and activator of transcription 6 genes in Indonesian children with minimal change nephrotic syndrome. *Am J Nephrol* 2005 Jan-Feb; 25 (1): 30-5.
  69. Ece A, Atamer Y, Gürkan F, Davutoglu M, Bilici M, Tutanç M et al. Paraoxonase, anti-oxidant response and oxidative stress in children with chronic renal failure. *Pediatr Nephrol* 2006 Feb; 21 (2): 239-45.
  70. Bargman JM. Management of minimal lesion glomerulonephritis: evidence-based recommendations. *Kidney Int Suppl* 1999 Jun; 70: S3-16.
  71. Noroña B, Valentín M, Gutiérrez E, Praga M. Treatment of steroid-dependent minimal change-nephrotic syndrome with mycophenolate mofetil. *Nefrologia* 2004; 24 (1): 79-82.
  72. Barletta GM, Smoyer WE, Bunchman TE, Flynn JT and Kershaw DB. Use of mycophenolate mofetil in steroid-dependent and -resistant nephrotic syndrome. *Pediatr Nephrol* 2003 Aug; 18 (8): 833-7.
  73. Pesavento TE, Bay WH, Agarwal G, Hernández RA Jr, Hebert LA. Mycophenolate therapy in frequently relapsing minimal change disease that has failed cyclophosphamide therapy. *Am J Kidney Dis* 2004 Mar; 43 (3): e3-6.
  74. Bagga A, Hari P, Moudgil A, Jordan SC. Mycophenolate mofetil and prednisolone therapy in children with steroid-dependent nephrotic syndrome. *Am J Kidney Dis* 2003 Dec; 42 (6): 1114-20.
  75. Ulinski T, Dubourg L, Saïd MH, Parchoux B, Ranchin B, Cochat P. Switch from cyclosporine A to mycophenolate mofetil in nephrotic children. *Pediatr Nephrol* 2005 Apr; 20 (4): 482-5.
  76. Moudgil A, Bagga A and Jordan SC. Mycophenolate mofetil therapy in frequently relapsing steroid-dependent and steroid-resistant nephrotic syndrome of childhood: current status and future directions. *Pediatr Nephrol* 2005 Oct; 20 (10): 1376-81.
  77. Novak I, Frank R, Vento S, Vergara M, Gauthier B, Trachtman H. Efficacy of mycophenolate mofetil in pediatric patients with steroid-dependent nephrotic syndrome. *Pediatr Nephrol* 2005 Sep; 20 (9): 1265-8.
  78. Mendizábal S, Zamora I, Berbel O, Sanahuja MJ, Fuentes J, Simon J. Mycophenolate mofetil in steroid/cyclosporine-dependent/resistant nephrotic syndrome. *Pediatr Nephrol* 2005 Jul; 20 (7): 914-9.
  79. Kwinta-Rybicka J, Wilkosz K, Wierzchowska-S\_owiacze EK, Ogarek I, Moczulska A, Stec Z, Pe\_kowska A, Sancewicz-Pach K, Pietrzyk JA. Mycophenolate mofetil in treatment of childhood nephrotic syndrome—preliminary report. *Przegl Lek* 2006; 63 Suppl 3:44-8.
  80. Fujinaga S, Ohtomo Y, Umino D, Takemoto M, Shimizu T, Yamashiro Y, Kaneko K. A prospective study on the use of mycophenolate mofetil in children with cyclosporine-dependent nephrotic syndrome. *Pediatr Nephrol* 2007 Jan; 22 (1): 71-6.
  81. Haas M, Meehan SM, Karrison TG, Spargo BH. Changing etiologies of unexplained adult nephrotic syndrome: a comparison of renal biopsy findings from 1976-1979 and 1995-1997. *Am J Kidney Dis* 1997 Nov; 30 (5): 621-31.
  82. Quigg RJ. Complement and autoimmune glomerular diseases. *Curr Dir Autoimmun* 2004; 7: 165-80.
  83. Appel G, Nachman P, Hogan SL, Rodhakrishnan J, Old C, Herbert L et al. Eculizumab (C5 complement inhibitor) in the treatment of idiopathic membranous nephropathy. *J Am Soc Nephrol* 2002; 13: 668A (abstr).
  84. Cattran DC. Management of membranous nephropathy: when and what for treatment. *J Am Soc Nephrol* 2005; 16: 1188-94.
  85. Du Buf-Vereijken PW, Branten AJ and Wetzels JF. Idiopathic membranous nephropathy: outline and rationale of a treatment strategy. *Am J Kidney Dis* 2005 Dec; 46 (6): 1012-29.
  86. Ponticelli C, Zucchelli P, Passerini P, Cesana B, Locatelli F, Pasquali S et al. A 10-year follow-up of a randomized study with methylprednisolone and chlorambucil in membranous nephropathy. *Kidney Int* 1995 Nov; 48 (5): 1600-4.
  87. Jha V, Ganguli A, Saha TK, Kohli HS, Sud K, Gupta KL et al. A randomized, controlled trial of steroids and cyclophosphamide in adults with nephrotic syndrome caused by idiopathic membranous nephropathy. *J Am Soc Nephrol* 2007; 18 (6): 1899-904.
  88. Troyanov S, Wall CA, Miller JA, Scholey JW, Cattran DC; Toronto Glomerulonephritis Registry Group. Idiopathic membranous nephropathy: definition and relevance of a partial remission. *Kidney Int* 2004 Sep; 66 (3): 1199-205.
  89. Perna A, Schieppati A, Zamora J, Giuliano GA, Braun N and Remuzzi G. Immunosuppressive treatment for idiopathic membranous nephropathy: a systematic review. *Am J Kidney Dis* 2004 Sep; 44 (3): 385-401.
  90. Miller G, Zimmerman R 3<sup>rd</sup>, Radhakrishnan J and Appel G. Use of mycophenolate mofetil in resistant membranous nephropathy. *Am J Kidney Dis* 2000 Aug; 36 (2): 250-6.
  91. Polenakovic M, Grcevska L, Dzikova S. Mycophenolate mofetil in treatment of idiopathic stages III-IV membranous nephropathy. *Nephrol Dial Transplant* 2003 Jun; 18 (6): 1233-4.
  92. Du Buf-Vereijken PW, Wetzels JF. Mycophenolate mofetil (MMF) versus cyclophosphamide (CP) in patients with idiopathic membranous nephropathy and renal insufficiency. *J Am Soc Nephrol* 2004; 14: A341 (abstr).
  93. Branten AJ, Du Buf-Vereijken PW, Vervloet M, Wetzels JF. Mycophenolate mofetil in idiopathic membranous nephropathy: a clinical trial with comparison to a historic control group treated with cyclophosphamide. *Am J Kidney Dis* 2007 Aug; 50 (2): 248-56.
  94. Remuzzi G, Chiurciu C, Abbate M, Brusegan V, Bontempelli M, Ruggenenti P. Rituximab for idiopathic membranous nephropathy. *Lancet* 2002 Sep 21; 360 (9337): 923-4.
  95. Ponticelli C, Passerini P, Salvadori M, Manno C, Viola BF, Pasquali S, Mandolfo S, Messa P. A randomized pilot trial comparing methylprednisolone plus a cytotoxic agent versus synthetic adrenocorticotropic hormone in idiopathic membranous nephropathy. *Am J Kidney Dis* 2006 Feb; 47 (2): 233-40.
  96. Wu X, Zha D, Xiang G, Zhang B, Xiao SY, Jia R. Combined MMF and insulin therapy prevents renal injury in experimental diabetic rats. *Cytokine* 2006 Dec; 36 (5-6): 229-36.
  97. Utimura R, Fujihara CK, Mattar AL, Malheiros DM, Noronha IL, Zatz R. Mycophenolate mofetil prevents the development of glomerular injury in experimental diabetes. *Kidney Int* 2003 Jan; 63 (1): 209-16.
  98. Tapia E, Franco M, Sánchez-Lozada LG, Soto V, Ávila-Casado C, Santamaría J, Quiroz Y, Rodríguez-Iturbe B, Herrera-Acosta J. Mycophenolate mofetil prevents arteriopathy and renal injury in subtotal ablation despite persistent hypertension. *Kidney Int* 2003 Mar; 63 (3): 994-1002.
  99. Remuzzi G, Zoja C, Gagliardini E, Corna D, Abbate M, Benigni A. Combining an antiproteinuric approach with mycophenolate mo-

- fetil fully suppresses progressive nephropathy of experimental animals. *J Am Soc Nephrol* 1999 Jul; 10 (7): 1542-9.
100. Romero F, Rodríguez-Iturbe B, Parra G, González L, Herrera-Acosta J, Tapia E. Mycophenolate mofetil prevents the progressive renal failure induced by 5/6 renal ablation in rats. *Kidney Int* 1999 Mar; 55 (3): 945-55.
  101. Takeda S, Takahashi M, Sado Y, Takeuchi K, Hakamata Y, Shimizu H, Kaneko T, Yamamoto H, Ito C, Ookawara S, Asano Y, Kusano E, Kobayashi E. Prevention of glomerular crescent formation in glomerulonephritis by mycophenolate mofetil in rats. *Nephrol Dial Transplant* 2004 Sep; 19 (9): 2228-36.
  102. Sahin GM, Sahin S, Kantarci G, Ergin H. Mycophenolate mofetil treatment for therapy-resistant glomerulopathies. *Nephrology (Carlton)* 2007 Jun; 12 (3): 285-8.
  103. García-Cantón C, Toledo A, Palomar R, Fernández F, López J, Moreno A, Esparza N, Suria S, Rossique P, Díaz JM, Checa D. Good-pasture's syndrome treated with mycophenolate mofetil. *Nephrol Dial Transplant* 2000 Jun; 15 (6): 920-2.