

Adult abdominal Burkitt lymphoma with isolated peritoneal involvement

Catarina Oliveira^{1*}, Hugo Matos¹, Paula Serra², Rui Catarino¹, Amélia Estevão¹

1. Medical Imaging Department and Faculty of Medicine, University Hospital of Coimbra, Portugal

2. Pathology Department, General Hospital, University Hospital of Coimbra, Portugal

* **Correspondence:** Dra. Catarina Oliveira, Serviço de Radiologia, Hospital Geral - Centro Hospitalar e Universitário de Coimbra, Quinta dos vales, 3041- 801 São Martinho do Bispo, Coimbra, Portugal
(✉ kat.catarina@gmail.com)

Radiology Case. 2014 Jan; 8(1):27-33 :: DOI: 10.3941/jrcr.v8i1.1400

ABSTRACT

Burkitt lymphoma is a fast-growing high grade B-cell neoplasm that rarely affects adults. Three clinical variants are described in the World Health Organization classification: endemic, sporadic, and immunodeficiency-associated. The non-endemic form typically presents as an abdominal mass in children. Symptoms usually occur due to mass effect or direct intestinal involvement. We describe a very unusual presentation of a sporadic Burkitt lymphoma case in a 61-year-old male with diffuse peritoneal and omental involvement, without lymphadenopathies, mimicking peritoneal carcinomatosis.

CASE REPORT

CASE REPORT

A 61-year-old Caucasian male, with no relevant medical or surgical history, presented to the emergency department with progressive increase in abdominal volume and loss of weight in the past 3 days. No other clinical signs were reported. There was no history of fever. He denied nausea, vomiting or changes in bowel habits. No hepatic, renal or cardiovascular disease history was reported.

Physical examination: The patient was somnolent, but stable, with no signs of respiratory distress. The only finding was the presence of a large palpable mass occupying the upper quadrants of the abdomen. Abdominal rebound and rigidity were absent and bowel sounds were normal.

Laboratorial findings: hematocrit was normal, WBC count was $10,1 \times 10^3/uL$ (N: $4-10 \times 10^3/uL$), total bilirubin was $22\mu mol/L$ (N: $<22\mu mol/L$); alanine aminotransferase was $47U/L$ (N: $13-69U/L$); alkaline phosphatase was $93U/L$ (N: $38-126U/L$), creatinine was $93,5 \mu mol/L$ (N: $58,0 - 110,0 \mu mol/L$). There was a slight elevation in aspartate aminotransferase: $76U/L$ (N: $15-46U /L$) and urea: $10,5 \text{ mmol/L}$ (N: $3,2-7,1 \text{ mmol/L}$) and a very high lactate dehydrogenase (LDH): $2198 U/L$ (N: $313,0 - 618,0 U/L$).

There was a high suspicion of abdominal neoplasm due to these findings.

Imaging workup: Abdominal ultrasound (US) revealed moderate anechoic effusion filling all the peritoneal recesses and diffuse nodular heterogeneous thickening of the abdominal wall (Fig. 1a and 1b). The liver had a regular contour and homogeneous parenchyma. There were no significant findings in the gallbladder, spleen, and kidneys. No evident bowel dilatation or mural thickening was noted.

A plain and contrast enhanced computed tomography (CT) of the thorax, abdomen and pelvis, with oral contrast, was subsequently performed. The abdominal and pelvic study revealed diffuse nodular peritoneal thickening, with heterogeneous enhancement. Peritoneal thickening was more prominent in the lesser sac, which was also filled with fluid (Fig. 2a-2d). Diffuse thickening of the greater omentum was also noted, resulting in a mass-like appearance with caking effect; no intestinal involvement was noted. Free low attenuation peritoneal effusion was also present (Fig. 3a-3d, 4a and 4b). There was no evidence of lymph node enlargement along the retroperitoneal, mesenteric or pelvic regions. The thoracic study revealed a small right pleural effusion, without

pleural thickening. Pulmonary parenchyma had no changes. No other prominent findings were evident on the CT.

Considering these changes, there was a high suspicion of metastatic disease due to a gastrointestinal tract neoplasm.

The patient underwent an upper digestive endoscopy, which showed small esophageal varices, antral erosive gastritis, and decreased gastric distension probably related to extrinsic compression. Biopsies were performed, revealing only chronic antral gastritis with mild atrophy and complete intestinal metaplasia (without dysplasia). Mild *Helicobacter pylori* colonization was also present.

Later laboratorial investigations included some tumor markers: carcinoembryonic antigen (CEA), carbohydrate antigen 19-9 (CA 19.9), alpha-fetoprotein (AFP) and prostate-specific antigen (PSA), all within normal levels. Serological HIV (type 1 and 2) study was also negative.

A diagnostic laparotomy was performed, permitting the nodular peritoneal thickening biopsy, as well as the removal of a great gastric curvature ganglion for histological evaluation.

Pathologic evaluation: Microscopic examination of the biopsy revealed a malignant neoplasm with diffuse growth pattern. The neoplastic cells were of intermediate size, with round nuclei and small nucleoli. Several mitotic and apoptotic figures were identified, as well as numerous macrophages containing cellular debris, giving a 'starry sky' appearance (Fig. 5). Neoplastic cells were strongly immunoreactive for LCA and CD20; BCL6 was positive in about 50% and Ki67 in more than 90% of neoplastic cells (Fig. 6a to 6c). These features were consistent with the diagnosis of Burkitt lymphoma.

The greater curvature ganglion examination showed edema, sinus histiocytosis, and perinodal adipose tissue infiltration by the neoplastic cells described above.

A bone marrow biopsy was performed for staging, revealing no involvement by the neoplastic cells.

Cytostatic treatment with COPADM protocol was initialized with good clinical and analytic response. The patient was then transferred to the Department of Hematology of a local oncologic institute.

DISCUSSION

Burkitt lymphoma (Table 1) is a very aggressive B-cell neoplasm. The endemic form occurs in African children, usually involving the jaw and other facial bones. The immunodeficiency-associated form usually occurs in patients with HIV/AIDS and commonly presents as diffuse lymphadenopathy. Sporadic Burkitt lymphoma occurs worldwide (usually in children and young adults), being more frequent in males [1]. It accounts only for 1%-2% of lymphoma in adults in the U.S. and Western Europe [1, 2].

Clinical presentation depends on the site of involvement, the most common being the abdomen.

Mesenteric and retroperitoneal lymph node involvement commonly presents as abdominal and pelvic masses [4, 5]. These masses may be large, single or multiple. Some masses may have necrotic centers containing fluid or, in rare cases, air [6, 7]. Calcification of mesenteric and retroperitoneal masses has been reported in aggressive types of non-Hodgkin's lymphoma and, specifically, in Burkitt lymphoma. Ascites is a common finding and the diagnosis of Burkitt lymphoma can often be made by paracentesis [5].

Extranodal involvement is very common, usually occurring in the gastrointestinal tract, but solid organs can also be affected, most frequently the spleen, liver, kidneys, pancreas, adrenal glands, and testes [3].

Lymphomatosis involvement of the peritoneum is not frequent, and it is usually associated with diffuse B-cell lymphoma [8, 9]. CT findings include peritoneal thickening, usually in a linear rather than nodular pattern, with heterogeneous enhancement following administration of intravenous contrast. Peritoneal masses and ascites are commonly associated. Omental involvement can result in a large mass-like effect with caking or confluent nodules [9]. When diffuse peritoneal disease is present, it is usually associated with focal gastrointestinal masses and/or significant retroperitoneal or mesenteric lymphadenopathies that may be very large with a mass-like appearance [8, 9]. Liver and spleen enlargement can also be concomitant findings. Isolated peritoneal involvement is rare, and it has been described only in young adults and children [10, 11].

Differential diagnosis (Table 2):

1) Peritoneal carcinomatosis: This is by far the most common diagnosis of diffuse peritoneal involvement, especially in older patients. It usually results from the secondary spread of primary mucinous tumors - ovarian and colonic origin being the most common. In children and adolescents, desmoplastic small round cell tumor is the most frequent primary origin [4]. Imaging findings are nonspecific. Neoplastic peritoneal involvement presents at CT as a soft-tissue process (tumorous or infiltrative) that may have prominent enhancement, with or without associated ascites. Omental involvement is frequent. Some authors claim that an irregular outer contour of the infiltrated omentum is more suggestive of carcinomatosis [12]. Cystic or fat component, necrosis or calcifications may be additional findings. A primary known neoplasm also favors the diagnosis. In the lack of known neoplasm, an occult gastrointestinal, ovarian or other organ neoplasm should be initially favored, especially in older patients [13].

2) Malignant peritoneal mesothelioma. This is a very rare entity. In contrast to pleural mesothelioma, not all of the cases of peritoneal mesothelioma have a history of significant asbestos exposure. They are two major patterns of disease: a "dry" appearance, consisting in peritoneal masses that may be confluent, and a "wet" appearance, consisting of ascites and nodular or diffuse peritoneal thickening. Scalloping of

adjacent abdominal organs may be found. Calcifications are uncommon [13].

3) Tuberculous peritonitis can also mimic the tumoral pattern of peritoneal involvement and should be considered, especially if there is a clinical suspicion. There are different patterns of disease described according to the amount of peritoneal fluid [14]. Peritoneal fluid usually is heterogeneous with multiple septa and loculations. On CT, peritoneal effusion typically has high attenuation values (25-45 HU). Diffuse peritoneal thickening usually has a smoother and more regular contour. It may also have a fine nodular aspect with tiny nodules (less than 5 mm). Omental involvement may have a smudge or cake appearance. Lymphadenopathies are commonly seen; enhancement varies with the degree of caseation, but peripheral enhancement with a low-attenuation center is the most characteristic pattern [14].

Even though CT findings of diffuse peritoneal and omental lymphomatosis are undistinguishable from those seen in other etiologies, non-loculated ascites and enlarged lymph nodes have been described by some authors as helpful differential signs [9].

Burkitt lymphoma isn't a prevalent cause of peritoneal and omental disease, but its accurate diagnosis is of utmost importance, regarding its non-surgical treatment [9]. It has a high responsive rate (>70%) to current chemotherapy protocols [1]. Despite the importance of noninvasive imaging techniques, definitive diagnosis always requires histological evaluation, peripheral blood analysis and other laboratory tests [3].

We present a very unusual case of Burkitt lymphoma with isolated peritoneal involvement. Neither enlarged lymph nodes nor other extranodal involvement were noted. There was also a very profuse involvement of the omentum, causing "omental cake" appearance, an imaging finding not yet described in the adult population for isolated lymphoma involvement. The patient's age is also a very uncommon feature: an older patient (61 years old), with no immunocompromised status, making lymphoma diagnosis less likely and peritoneal carcinomatosis more probable.

TEACHING POINT

When diffuse peritoneal disease is present in an adult, peritoneal Burkitt lymphoma can mimic peritoneal carcinomatosis and should be included in the differential diagnosis even in the absence of enlarged lymph nodes.

REFERENCES

1. Ferry JA. Burkitt's lymphoma: clinicopathologic features and differential diagnosis. *Oncologist* 2006 Apr; 11(4):375-83. PMID: 16614233
2. Blum KA, Lozanski G, Byrd JC. Adult Burkitt leukemia and lymphoma. *Blood* 2004 Nov 15;104(10):3009-20. PMID: 15265787
3. Leite NP, Kased N, Hanna RF, Brown MA, Pereira JM, Cunha R, Sirlin CB. Cross-sectional imaging of extranodal involvement in abdominopelvic lymphoproliferative malignancies. *Radiographics*. 2007 Nov-Dec;27(6):1613-34. PMID: 18025507
4. Dunnick NR, Reaman GH, Head GL, Shawker TH, Ziegler JL. Radiographic manifestations of Burkitt's lymphoma in American patients. *AJR Am J Roentgenol*. 1979 Jan;132(1):1-6. PMID: 103382
5. Biko DM, Anupindi SA, Hernandez A, Kersun L, Bellah R, Childhood Burkitt lymphoma: abdominal and pelvic imaging findings. *AJR Am J Roentgenol*. 2009 May;192(5):1304-15. PMID: 19380555
6. Fishman EK, Kuhlman JE, Jones RJ. Radiographics. CT of lymphoma: spectrum of disease. 1991 Jul;11(4):647-69. PMID:1887120
7. Sheth S, Horton KM, Garland MR, Fishman EK. Mesenteric neoplasms: CT appearances of primary and secondary tumors and differential diagnosis. *Radiographics*. 2003 Mar-Apr;23(2):457-73; quiz 535-6. PMID: 12640160
8. Kim Y, Cho O, Song S, Lee H, Rhim H, Koh B, Peritoneal lymphomatosis: CT findings. *Abdom Imaging*. 1998 Jan-Feb; 23(1):87-90. PMID: 9437071
9. Karaosmanoglu D, Karcaaltincaba M, Oguz B, Akata D, Ozmen M, Akhan O. CT findings of lymphoma with peritoneal, omental and mesenteric involvement: peritoneal lymphomatosis. *Eur J Radiol*. 2009 Aug; 71(2):313-7. Epub 2008 May 29. PMID: 18513906
10. Toma P, Granata C, Rossi A, Garaventa A. Multimodality imaging of Hodgkin disease and non-Hodgkin lymphomas in children. *Radiographics*. 2007 Sep-Oct;27 (5):1335-54. PMID: 17848695
11. Wong S, Sanchez TR, Swischuk LE, Huang FS. Diffuse peritoneal lymphomatosis: atypical presentation of Burkitt lymphoma. *Pediatr Radiol*. 2009 Mar;39(3):274-6. Epub 2008 Nov 20. PMID: 19020870
12. Yoo E, Kim J H, Kim MJ, Yu JS, Chung JJ, Yoo HS, Kim KW. Greater and Lesser Omenta: Normal Anatomy and Pathologic Processes. *RadioGraphics* 2007; 27:707-720. PMID: 17495288
13. Pickhardt PJ, Bhalla S. Primary Neoplasms of Peritoneal and Subperitoneal Origin: CT Findings. *RadioGraphics* 2005; 25:983-995. PMID:16009819
14. Vanhoenacker FM, Backer AI, Op de Beeck B, Maes M, Van Altena R, Van Beckevoort D, Kersemans P, De Schepper, AM. Imaging of gastrointestinal and abdominal tuberculosis. *Eur Radiol* (2004) 14:E103-E115. PMID:11870428

FIGURES

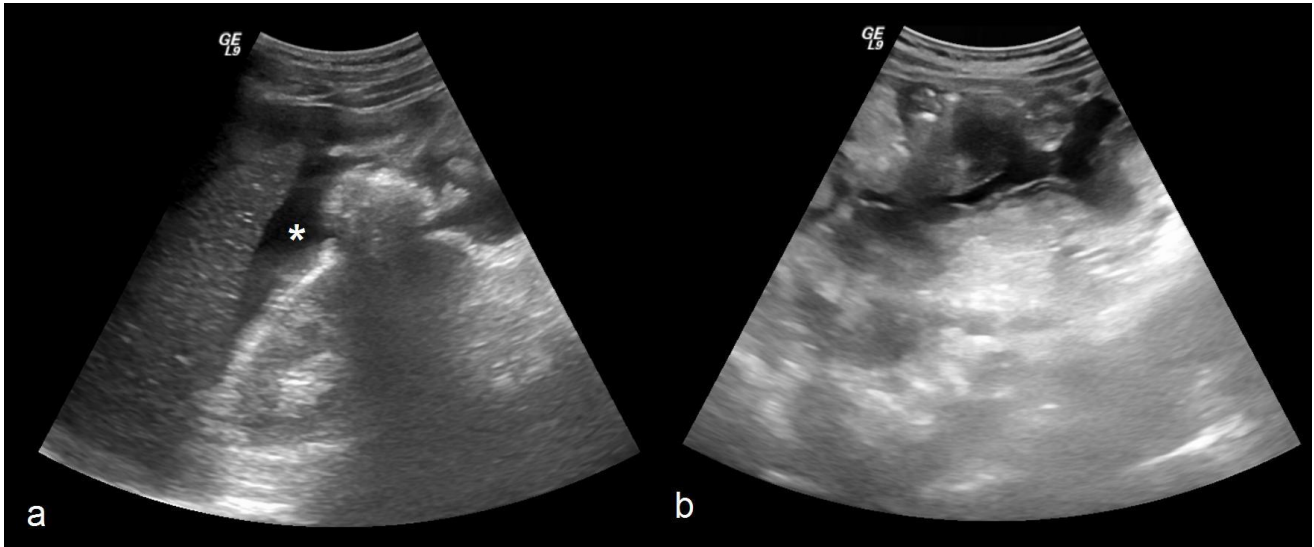


Figure 1. Sixty-one-year-old male with Burkitt lymphoma. Upper abdominal ultrasound using a curve probe (3-5 MHz). a) Longitudinal scan of the right hypochondrium shows peritoneal anechoic effusion in the Morison pouch (asterisk); b) Transversal scan of the epigastric region demonstrates heterogeneous nodular thickening of the anterior abdominal wall.

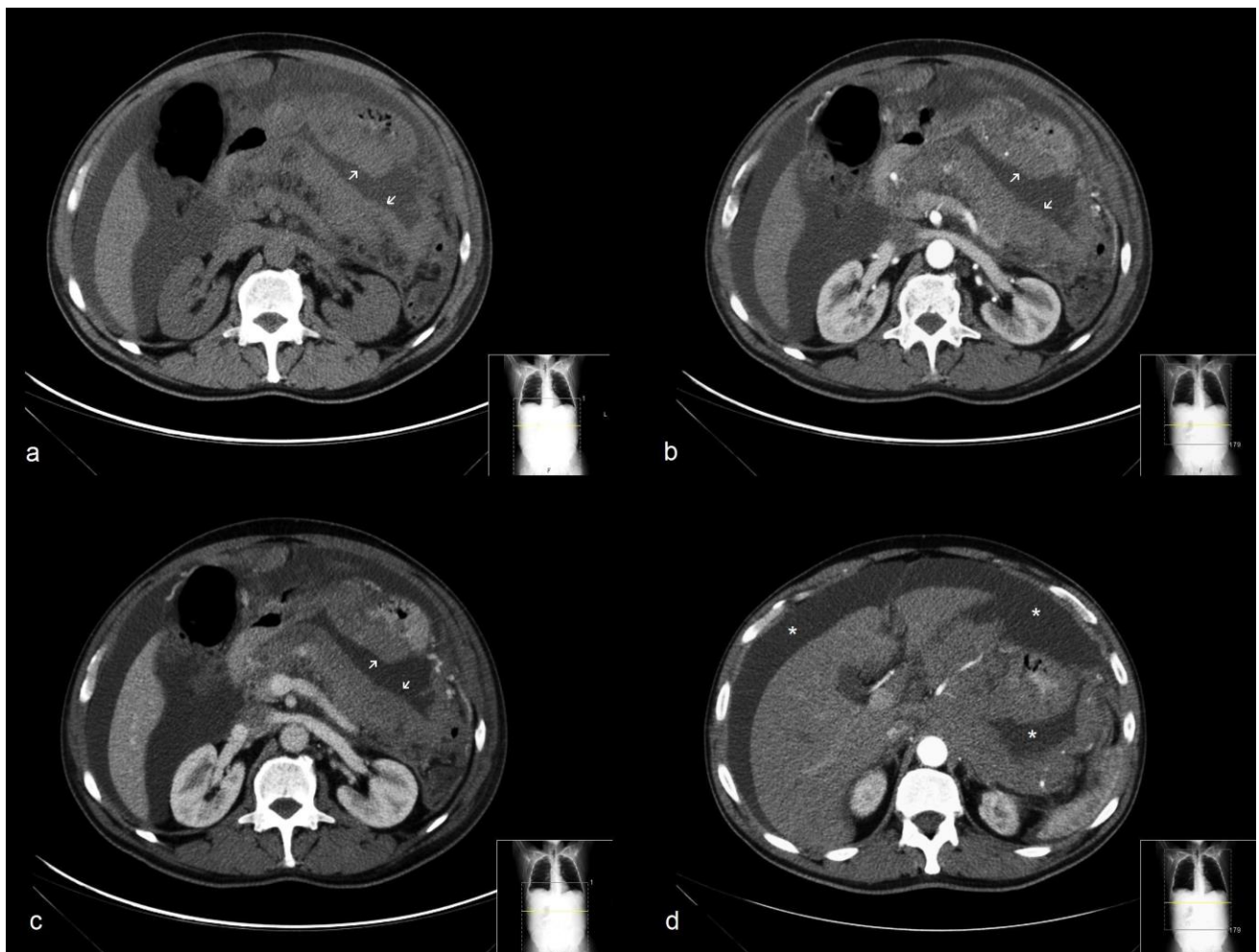


Figure 2. Sixty-one-year-old male with Burkitt lymphoma. Plain and contrast enhanced CT of the abdomen (Scanner: Multidetector CT Philips Brilliance 16- slices®. Protocol: 250mAs, 120kV, 5mm slice thickness, 100ml iobitridol Xenetix® (350 mg Iodine/ml)). a) Axial plain CT shows diffuse nodular thickening of the peritoneum in the lesser sac (arrows). At the same level, axial contrast enhanced CT in the arterial b) and portal phase c) shows heterogeneous enhancement of the nodular peritoneal thickening (arrows); d) Axial contrast enhanced CT, at a more cranial level, demonstrates low attenuation free peritoneal effusion also filling the lesser sac (asterisk).

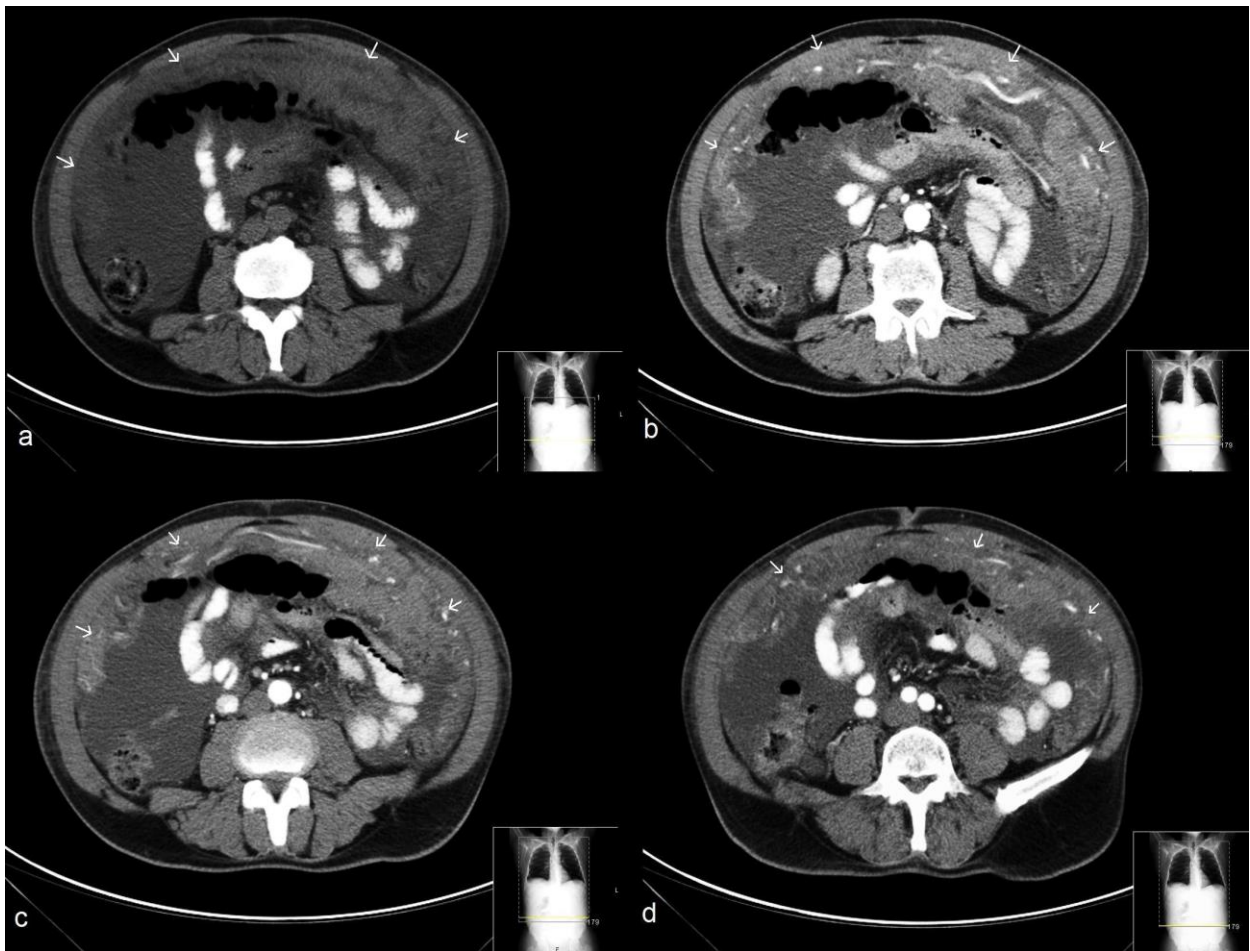


Figure 3. Sixty-one-year-old male with Burkitt lymphoma. Axial and plain contrast enhanced CT of the abdomen (Scanner: Multidetector CT Philips Brilliance 16- slices®. Protocol: 250mAs, 120kV, 5mm slice thickness, 100ml iobitridol Xenetix® (350 mg Iodine/ml)); a) Plain axial CT demonstrates diffuse thickening of the greater omentum, resulting in a large mass-like appearance with caking effect (arrows). Contrast enhanced CT in the arterial phase at different levels b), c) and d) reveals heterogeneous enhancement and a diffuse vascular net (arrows).

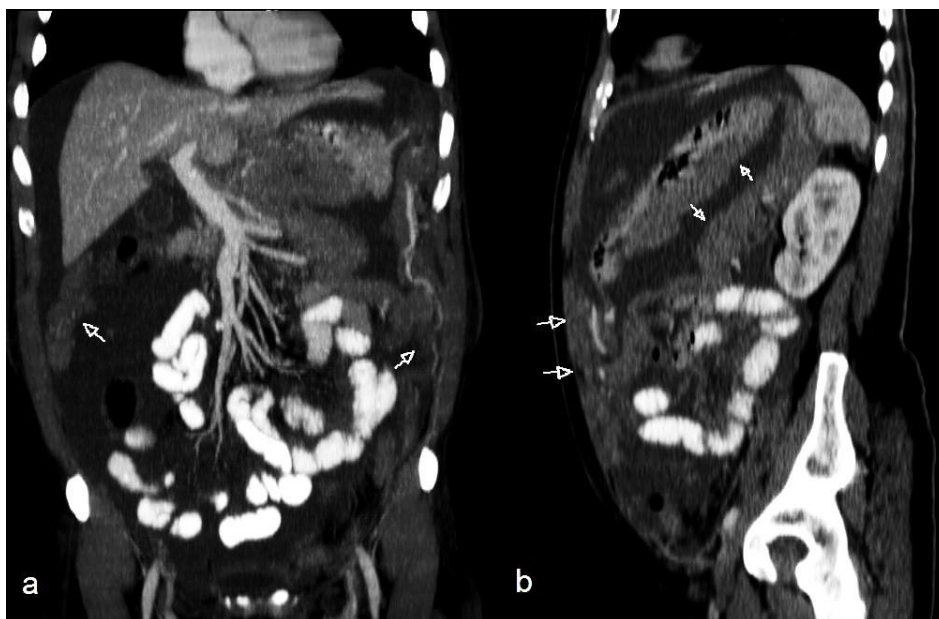


Figure 4. Sixty-one-year-old male with Burkitt lymphoma. Multiplanar reconstruction in the coronal a) and sagittal b) plan of a contrast enhanced CT of the abdomen and pelvis in the portal phase (Scanner: Multidetector CT Philips Brilliance 16-slices®. Protocol: 250mAs, 120kV, 5mm slice thickness, 100ml iobitridol Xenetix® (350 mg Iodine/ml)). There is a diffuse nodular heterogeneous thickening of the peritoneum (arrows) and low attenuation free peritoneal effusion; no enlarged lymph nodes were noted.

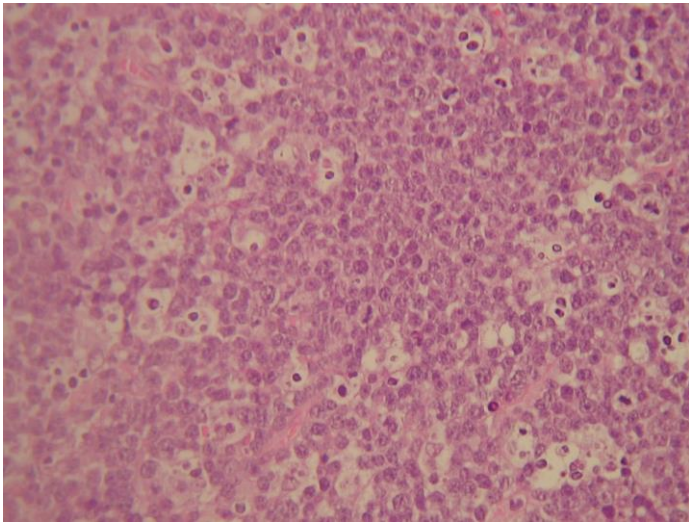
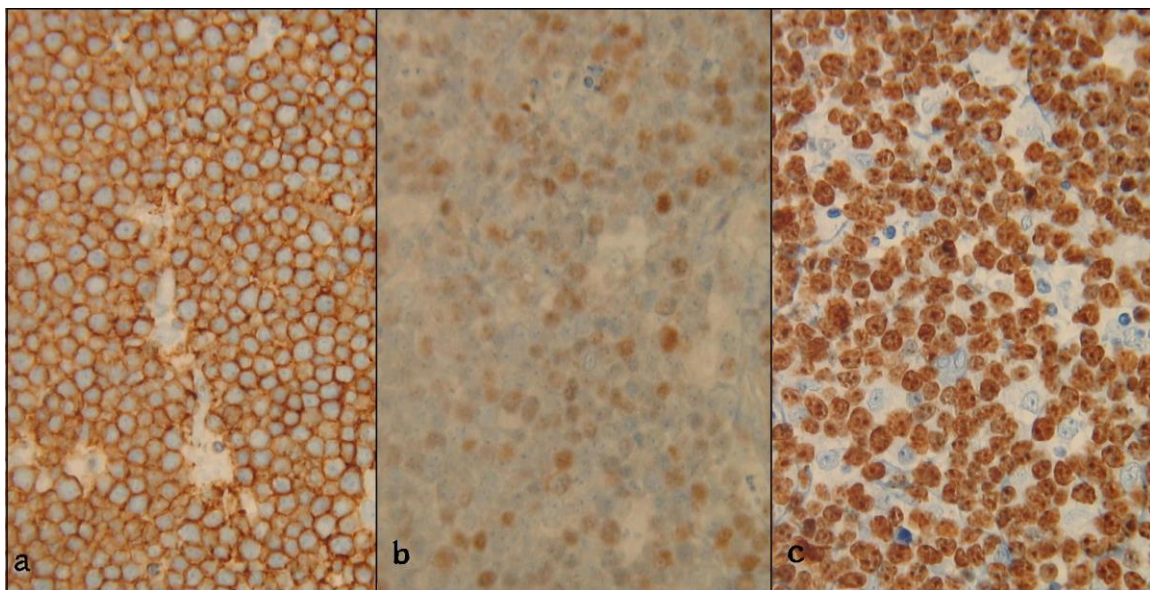


Figure 5 (left). Hematoxylin & Eosin high power view (x400) of the peritoneal thickening biopsy shows sheets and cords of intermediate size lymphocytes. They have round nuclei and small nucleoli with high nuclear/cytoplasm ratio, hyperchromasia and apoptotic bodies. Several mitotic figures were identified as well as numerous macrophages containing cellular debris giving 'starry sky' appearance, a typical feature of Burkitt lymphoma.

Figure 6 (bottom). Immunoreactivity high power view (x400) of the peritoneal thickening biopsy. a) Using antibody against CD20 - there was intense positive immunoreactivity; b) Using antibody against BCL6 - positive immunoreactivity occurred in about 50% of the neoplastic cells c) Using antibody against Ki-67 - there is intense positive immunoreactivity in the neoplastic cells (expressed in >90%), characteristic features of Burkitt lymphoma.



Etiology	Unknown.
Incidence	1%–2% of lymphoma in adults in the U.S. and Western Europe.
Gender ratio	Ratio 2:1 (male: female).
Age predilection	Childhood and young adults.
Risk factors	EBV infection (present in 25-30% of the cases).
Treatment	Chemotherapy.
Prognosis	Good. Above 70% of complete response to treatment.
Findings on imaging	<ul style="list-style-type: none"> • Mesenteric and retroperitoneal lymph nodes enlargement, usually presenting as abdominal and pelvic masses. Masses may have necrotic centers containing fluid or, in rare cases, air; calcifications may be present; • Extranodal involvement is very common, usually occurring in the gastrointestinal tract, but solid organs can also be affected, most frequently the spleen, liver, kidneys, pancreas, adrenal glands and testes; • Lymphomatosis involvement of the peritoneum is unusual; imaging findings include peritoneal thickening, usually in a linear rather than nodular pattern, with heterogeneous enhancement; omental involvement can result in mass-like effect with <i>caking</i> or confluent nodules; ascites is a common finding, usually without septa or loculations; • Isolated peritoneal involvement is rare, but it has been described in young adults and children.

Table 1: Summary table of key findings in Sporadic Burkitt Lymphoma

	Patient history	X-Ray	US	CT	Pattern of contrast enhancement
Peritoneal lymphomatosis	More common in children and young adults.	<ul style="list-style-type: none"> • Signs of peritoneal effusion. • Abnormal abdominal calcifications may be found. 	<ul style="list-style-type: none"> • Echogenic heterogeneous abdominal wall mass. • Retroperitoneal or mesenteric mass-like lymphadenopathies. • Free anechoic peritoneal effusion. • Spleen or/and liver enlargement. 	<ul style="list-style-type: none"> • Diffuse linear peritoneal thickening or mass. • Omental involvement with <i>caking</i> or confluent nodules. • Retroperitoneal or mesenteric mass-like lymphadenopathies. • Free peritoneal effusion. • Spleen or/and liver enlargement. 	Heterogeneous.
Peritoneal carcinomatosis	Known organ-based malignancy.	<ul style="list-style-type: none"> • Signs of peritoneal effusion. • Abnormal abdominal calcifications may be found. 	<ul style="list-style-type: none"> • Echogenic heterogeneous abdominal wall mass with irregular outer contour. • With or without associated peritoneal effusion. 	<ul style="list-style-type: none"> • Tumorous or infiltrative peritoneal mass; may have cystic component, necrosis or calcifications. • Omental involvement is frequent and can result in omental <i>caking</i> or confluent nodules with irregular contour. • With or without associated peritoneal effusion. 	Heterogeneous (may be prominent).
Tuberculous peritonitis	Clinical suspicion	<ul style="list-style-type: none"> • Signs of peritoneal effusion. • Abnormal abdominal calcifications may be found. 	<ul style="list-style-type: none"> • Smooth, mild abdominal wall thickening. • Peritoneal effusion with multiple, fine mobile strands of fibrin and debris - <i>lattice-like</i> appearance. • Hypoechoic lymph nodes that may have calcifications. 	<ul style="list-style-type: none"> • Smooth, mild peritoneal thickening. • Omental involvement with <i>caking</i> or smudge appearance. • Peritoneal effusion with high attenuation values, internal septa and loculations. • Lymph nodes with low density center; may have calcifications. 	<ul style="list-style-type: none"> • Heterogeneous. • Lymph nodes with peripheral enhancement and low-density center.
Malignant peritoneal mesothelioma	Asbestos exposure history (not always).	<ul style="list-style-type: none"> • Signs of peritoneal effusion. 	<ul style="list-style-type: none"> • Abdominal wall mass. • Peritoneal effusion (“wet” form). 	<ul style="list-style-type: none"> • Peritoneal mass or diffuse nodular peritoneal thickening. • Scalloping of adjacent abdominal organs. • Peritoneal effusion (“wet” form). • Calcifications are uncommon. 	Heterogeneous

Table 2: Differential diagnosis table for diffuse peritoneal disease

ABBREVIATIONS

AFP = Alpha-fetoprotein
 AIDS = Acquired immunodeficiency syndrome.
 BCL6 = B-cell CLL/lymphoma 6
 CA 19.9 = Carbohydrate antigen 19-9
 CD20 = Cluster of differentiation 19
 CEA = Carcinoembryonic antigen
 COPADM = Cyclophosphamide, Vincristine and Methylprednisolone
 CT = Computed tomography
 HIV = Human immunodeficiency virus
 Ki67 = Antigen KI-67
 LCA = Leukocyte common antigen
 LDH = Lactate dehydrogenase
 PSA = Prostate-specific antigen
 US = Ultrasound
 WBC = White blood cell

KEYWORDS

Burkitt lymphoma; multidetector computed tomography; omental caking; peritoneal neoplasm

Online access

This publication is online available at:
www.radiologycases.com/index.php/radiologycases/article/view/1400

Peer discussion

Discuss this manuscript in our protected discussion forum at:
www.radiolopolis.com/forums/JRCR

Interactivity

This publication is available as an interactive article with scroll, window/level, magnify and more features.
 Available online at www.RadiologyCases.com

Published by EduRad



www.EduRad.org