

# EUROPEAN JOURNAL OF CARDIO-THORACIC SURGERY

## **When the sky falls on one's head**

Manuel J. Antunes, Luís Eugénio and J. Ferrão de Oliveira  
*Eur J Cardiothorac Surg* 2007;31:1135-  
DOI: 10.1016/j.ejcts.2007.03.010

**This information is current as of December 2, 2008**

The online version of this article, along with updated information and services, is located on the World Wide Web at:

<http://ejcts.ctsnetjournals.org/cgi/content/full/31/6/1135>

The European Journal of Cardio-thoracic Surgery is the official Journal of the European Association for Cardio-thoracic Surgery and the European Society of Thoracic Surgeons. Copyright © 2007 by European Association for Cardio-Thoracic Surgery. Published by Elsevier. All rights reserved. Print ISSN: 1010-7940.

Images in cardio-thoracic surgery  
**When the sky falls on one's head**

Manuel J. Antunes<sup>\*</sup>, Luís Eugénio, J. Ferrão de Oliveira

*Cardiothoracic Surgery, University Hospital, Coimbra, Portugal*

Received 22 January 2007; received in revised form 1 March 2007; accepted 6 March 2007; Available online 6 April 2007

**Keywords:** Chest; Chest wall; Trauma

A bunch of steel rods fell over a building-construction worker. One (diameter 25 mm) penetrated his right eyebrow and entered the neck and left chest and upper abdominal

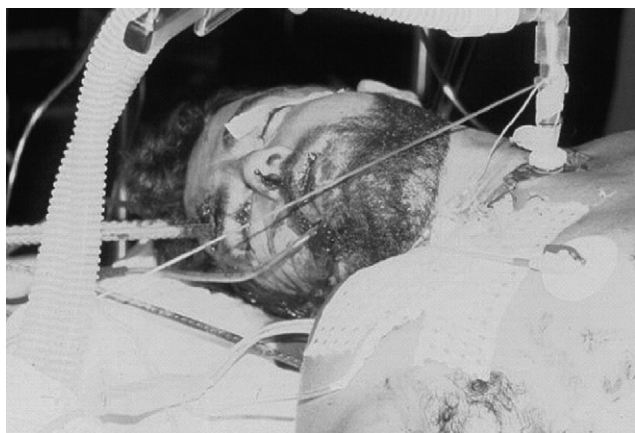

Fig. 1. Immediate preoperative photograph of the patient. One rod (diameter 30 mm) penetrated just above his right eyebrow.

cavities. Another penetrated through the right shoulder and chest (Figs. 1 and 2). He was discharged the sixth day after surgery with mild diplopia.

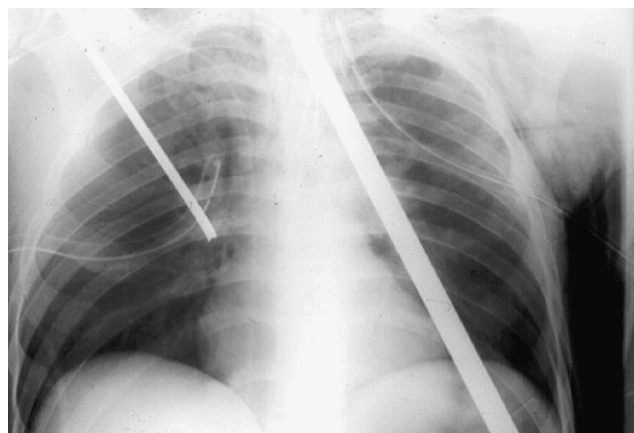


Fig. 2. Chest X-ray showing the steel bars, one in the neck and left chest and upper abdominal cavities, and the other in the right chest. During surgery, both were carefully removed under vision. The larger one had injured the distal anterior wall of the trachea, which was simply sutured. No other significant organ injury was identified.

<sup>\*</sup> Corresponding author. Address: Cirurgia Cardiorácica, Hospitais da Universidade, 3000-075 Coimbra, Portugal. Tel.: +351 239400418; fax: +351 239829674.

E-mail address: [antunes.cct.huc@sapo.pt](mailto:antunes.cct.huc@sapo.pt) (M.J. Antunes).

**When the sky falls on one's head**  
Manuel J. Antunes, Luís Eugénio and J. Ferrão de Oliveira  
*Eur J Cardiothorac Surg* 2007;31:1135-  
DOI: 10.1016/j.ejcts.2007.03.010

**This information is current as of December 2, 2008**

<b>Updated Information &amp; Services</b>	including high-resolution figures, can be found at: <a href="http://ejcts.ctsnetjournals.org/cgi/content/full/31/6/1135">http://ejcts.ctsnetjournals.org/cgi/content/full/31/6/1135</a>
<b>Subspecialty Collections</b>	This article, along with others on similar topics, appears in the following collection(s): <b>Mediastinum</b> <a href="http://ejcts.ctsnetjournals.org/cgi/collection/mediastinum">http://ejcts.ctsnetjournals.org/cgi/collection/mediastinum</a> <b>Chest wall</b> <a href="http://ejcts.ctsnetjournals.org/cgi/collection/chest_wall">http://ejcts.ctsnetjournals.org/cgi/collection/chest_wall</a>
<b>Permissions &amp; Licensing</b>	Information about reproducing this article in parts (figures, tables) or in its entirety can be found online at: <a href="http://ejcts.ctsnetjournals.org/misc/Permissions.shtml">http://ejcts.ctsnetjournals.org/misc/Permissions.shtml</a>
<b>Reprints</b>	Information about ordering reprints can be found online: <a href="http://ejcts.ctsnetjournals.org/misc/reprints.shtml">http://ejcts.ctsnetjournals.org/misc/reprints.shtml</a>

# EUROPEAN JOURNAL OF CARDIO-THORACIC SURGERY