



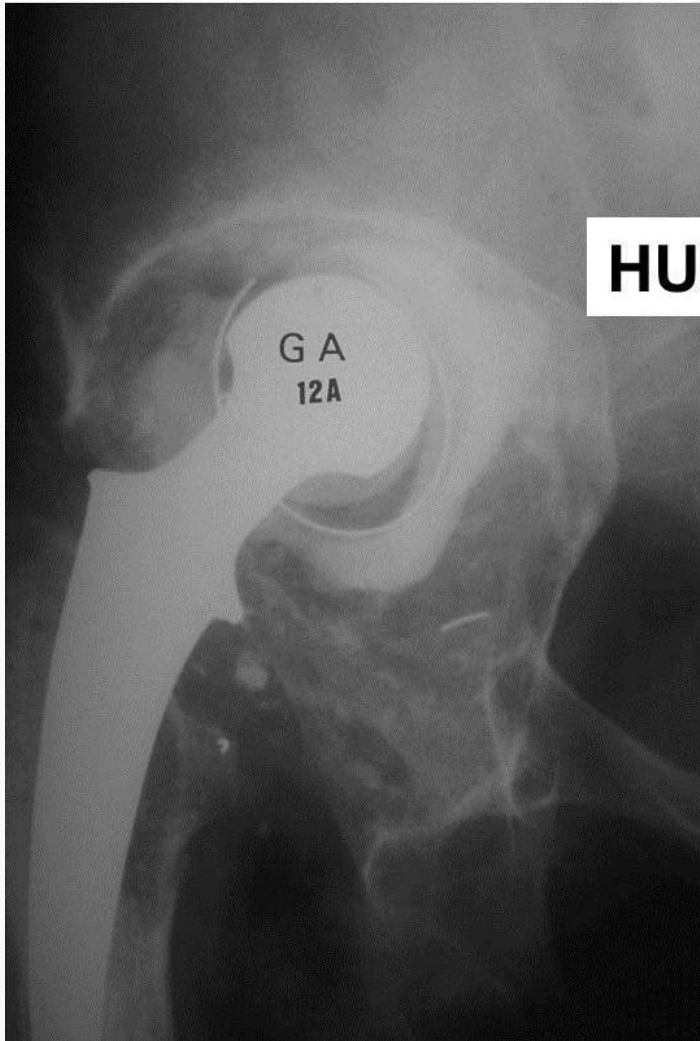
Revision hip arthroplasty: principles of management and surgical techniques.

Fernando Judas, Francisco Lucas, Luís Maximino.

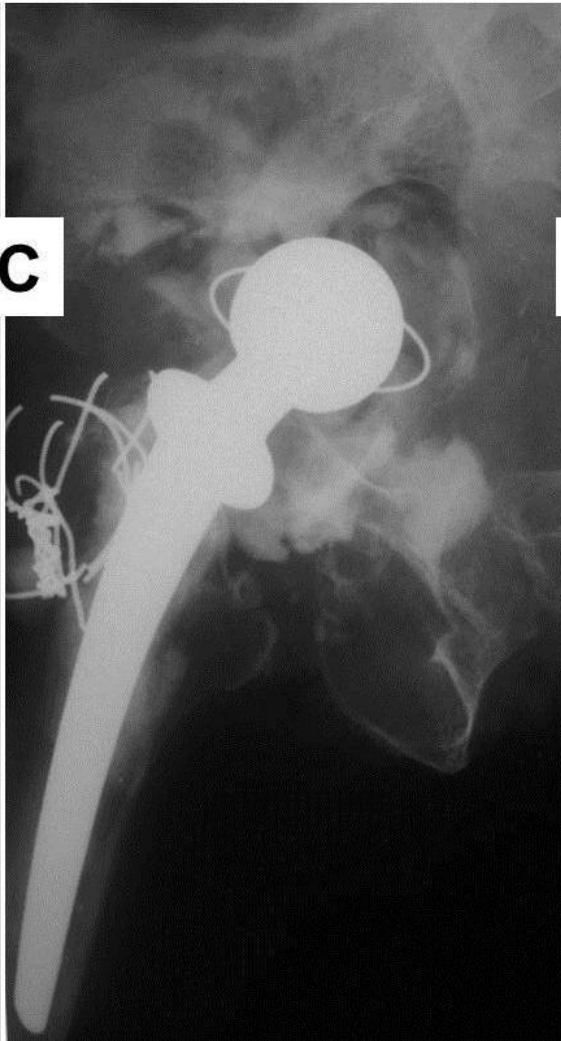
Faculty of Medicine, University of Coimbra.

University Clinic of Orthopaedics, Coimbra University Hospitals.

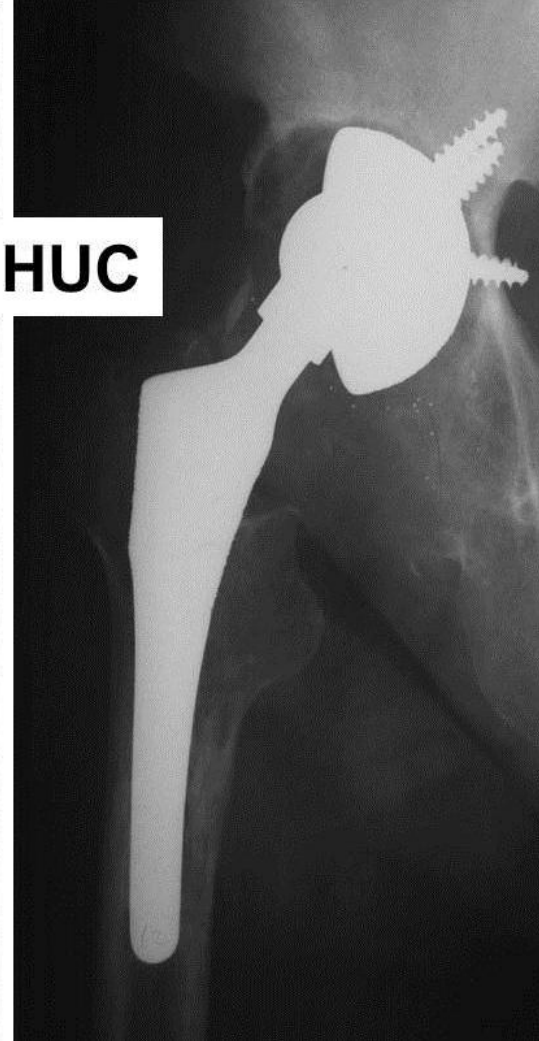
The problem: osteolysis, bone loss.



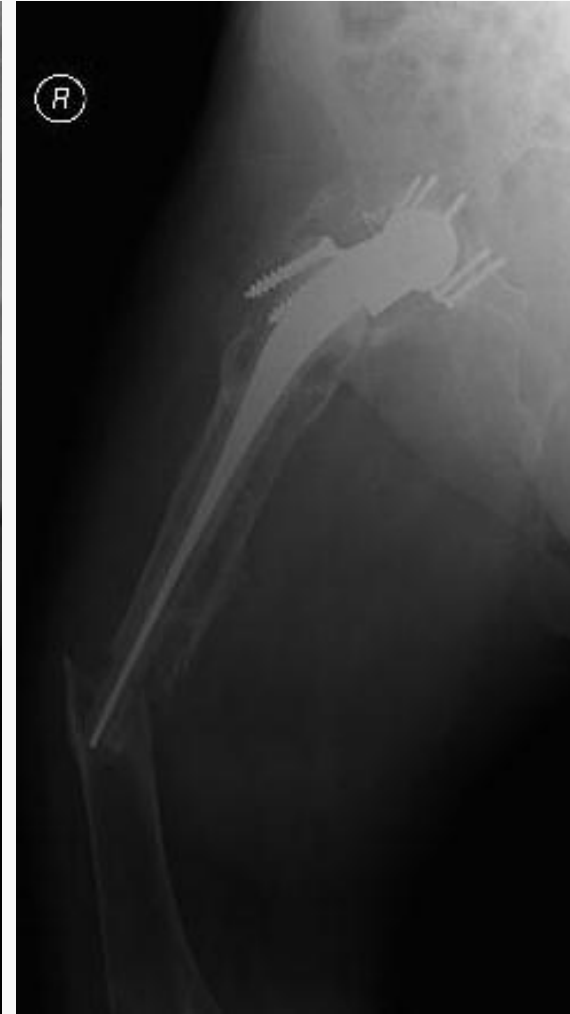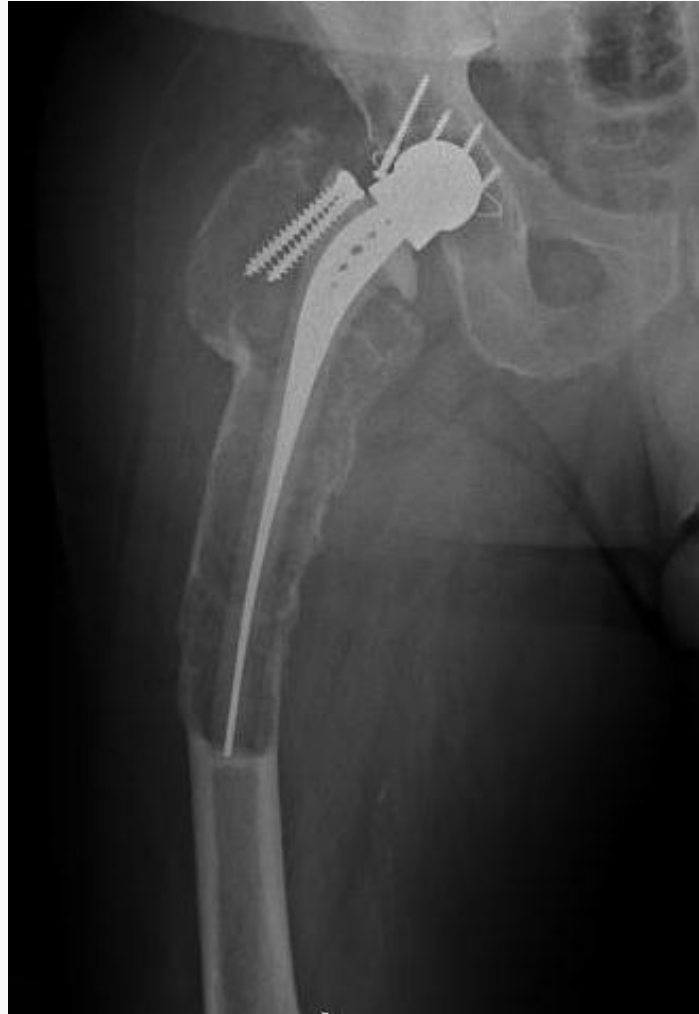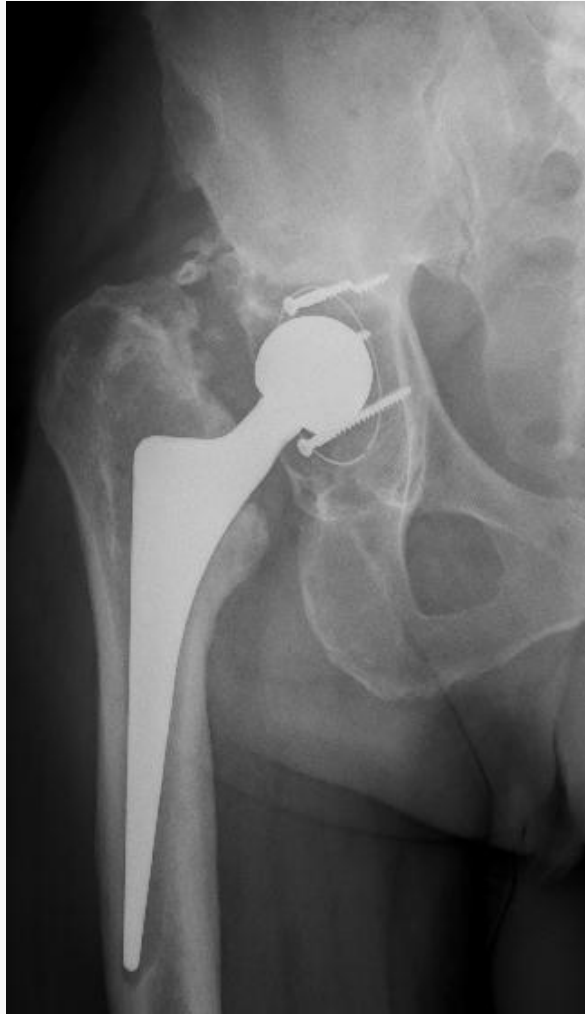HUC



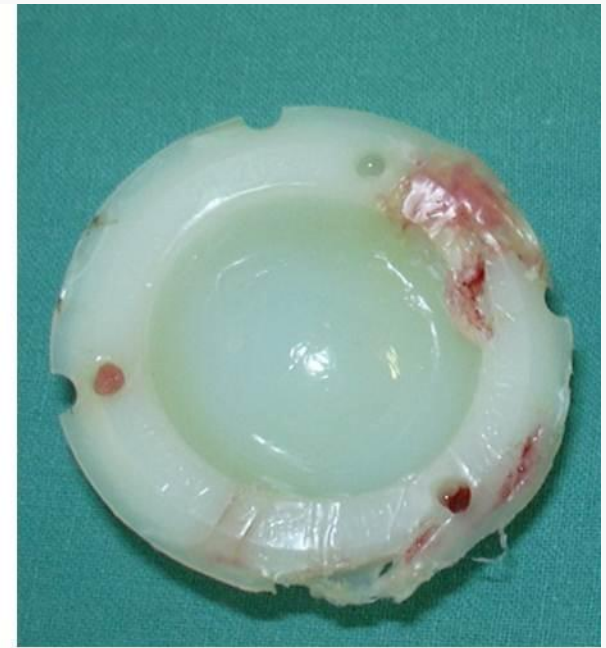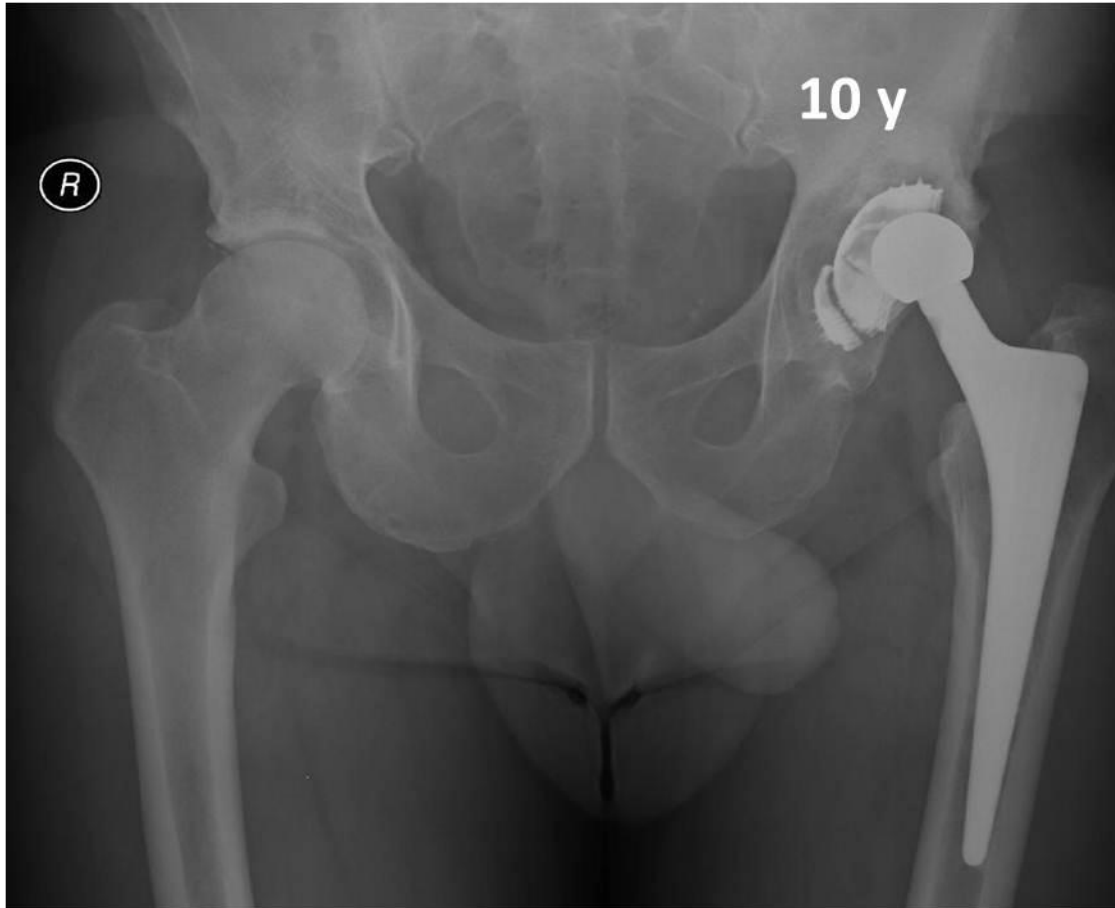
HUC



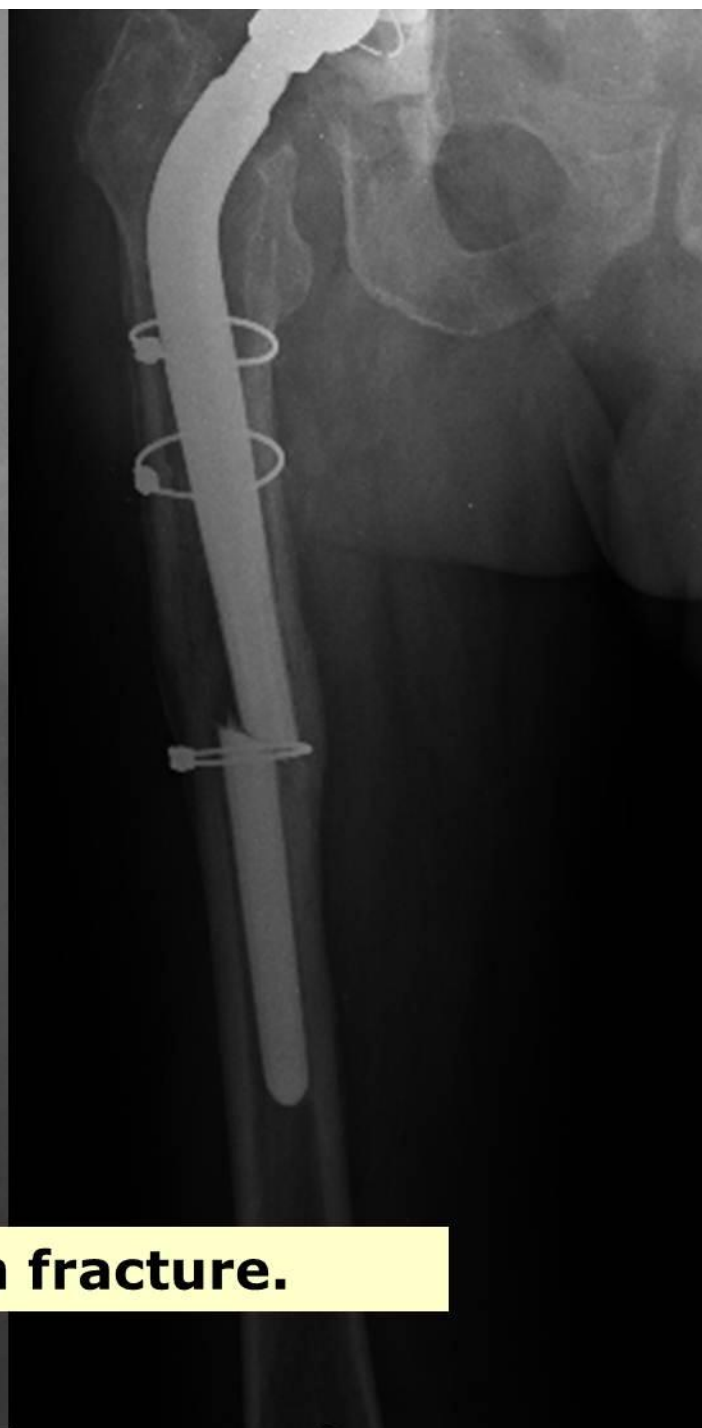
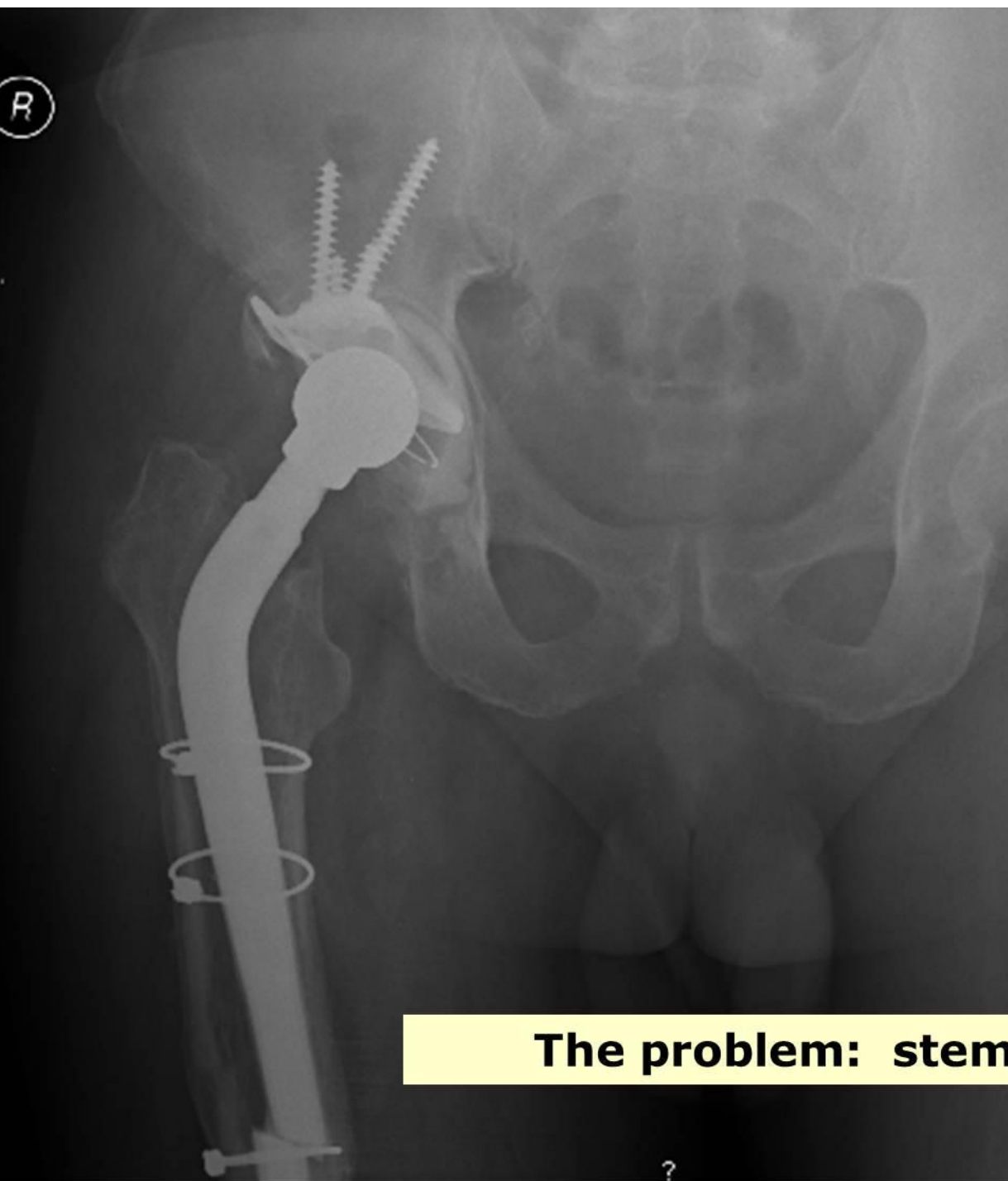
The problem: osteolysis, bone loss.



The problem

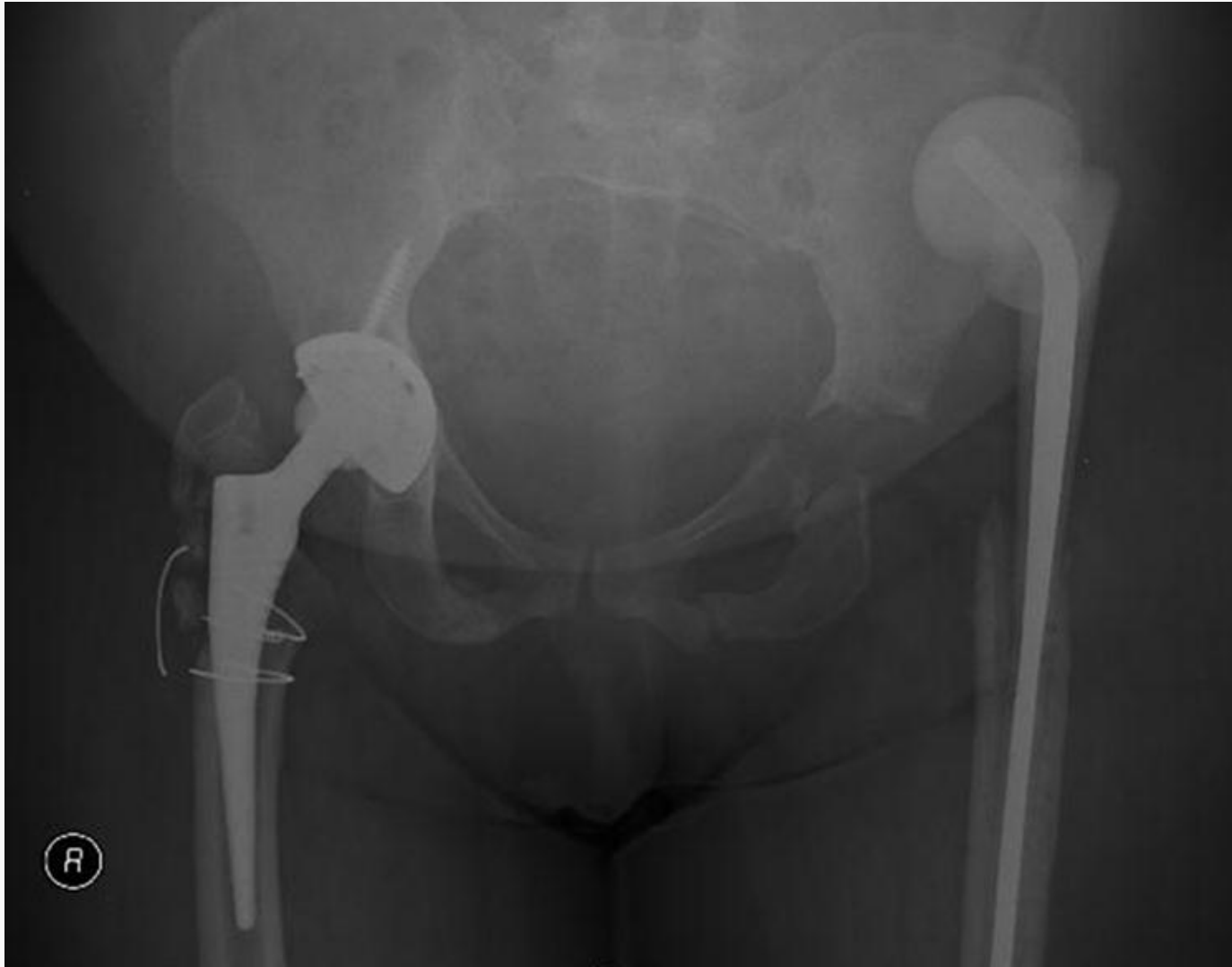

Polyethylene wear and fracture of the acetabular cup



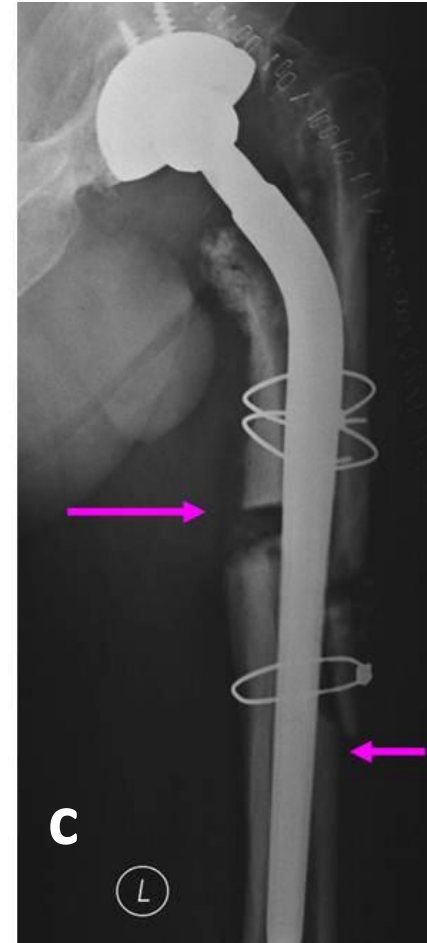
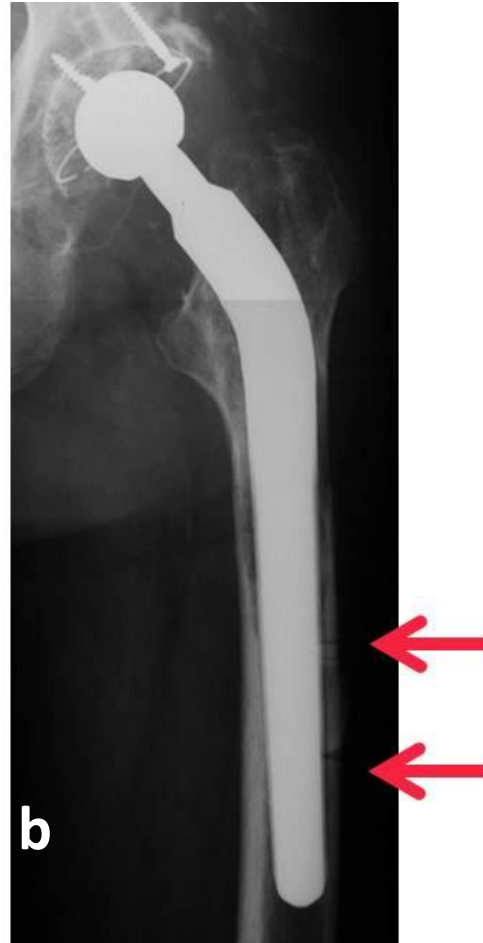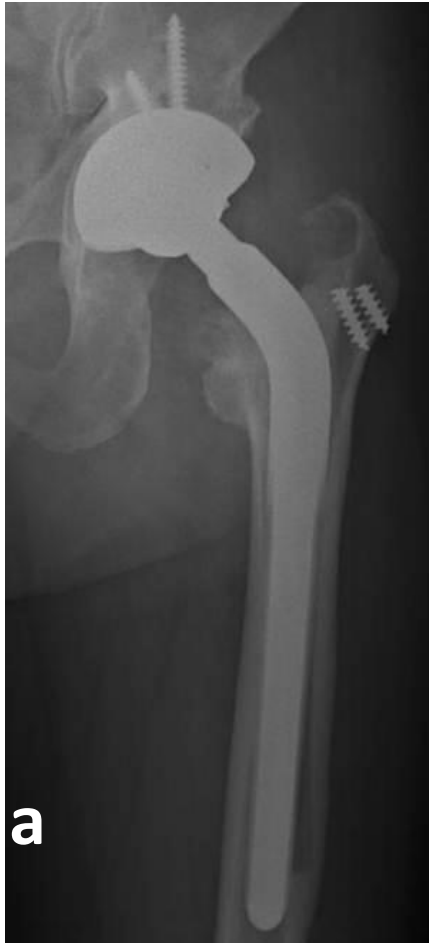The problem: stem fracture.

The problem: osteolysis, bone loss, infection.



Surgical strategy

- Posterolateral approach
- Femoral access route: (a) endofemoral; (b) bone "window"; (c) transfemoral (femoral flap)



Surgical strategy

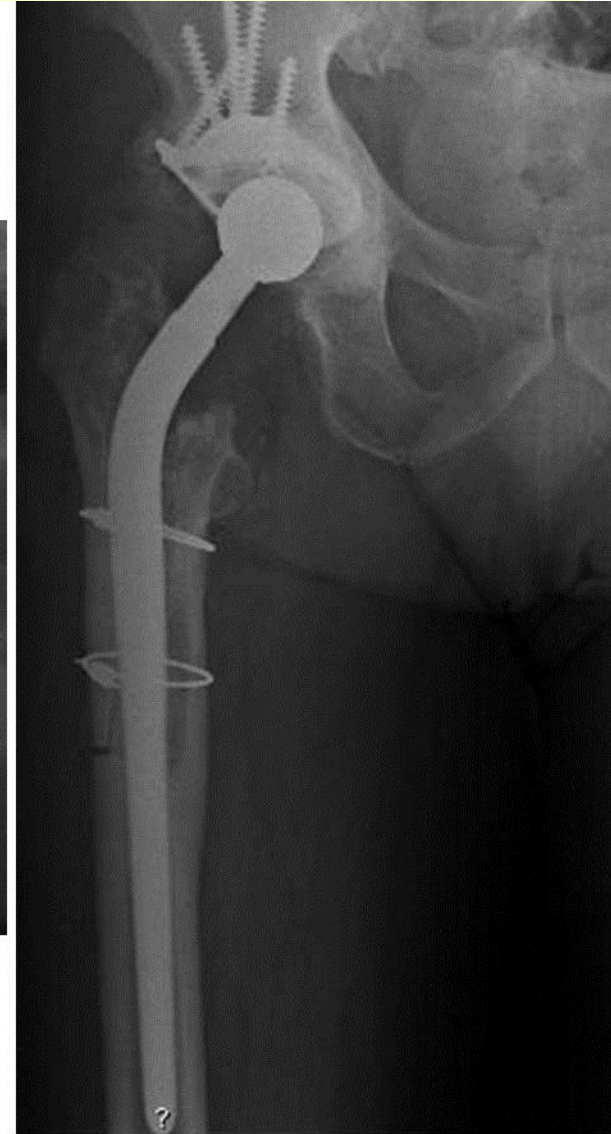
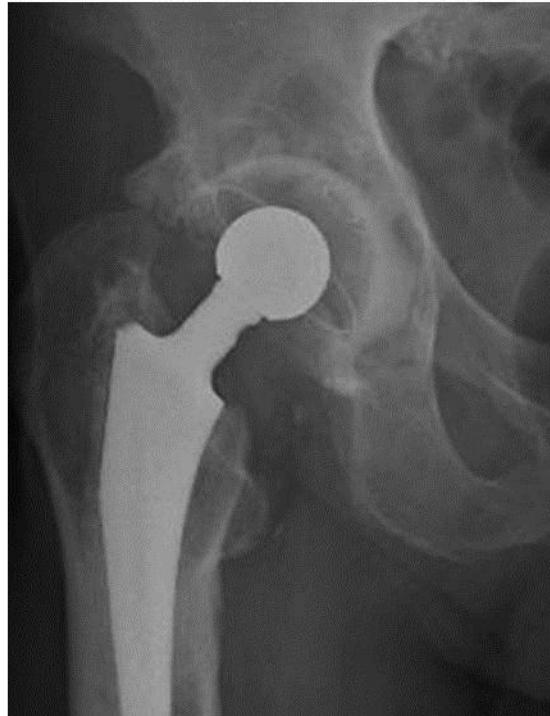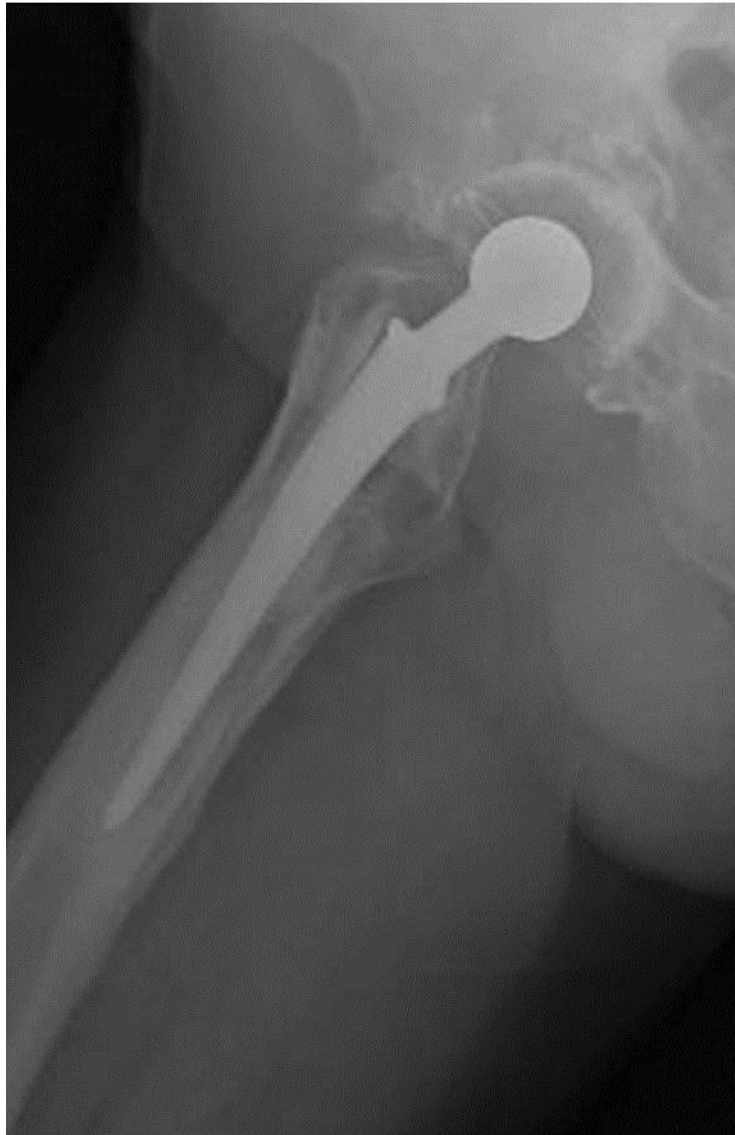Hip reconstruction: implants + bone allografts or Bone graft substitutes

Metallic roof reinforcement ring, conical cementless stem, (diaphyseal fixation), particulate cancellous bone allograft – **the most commonly used** -

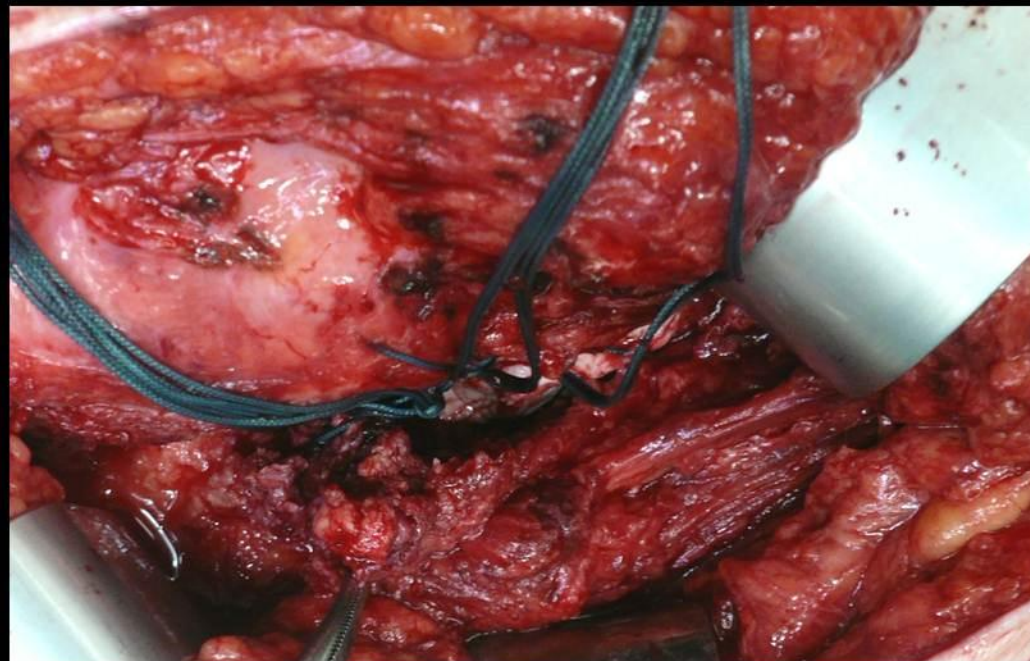
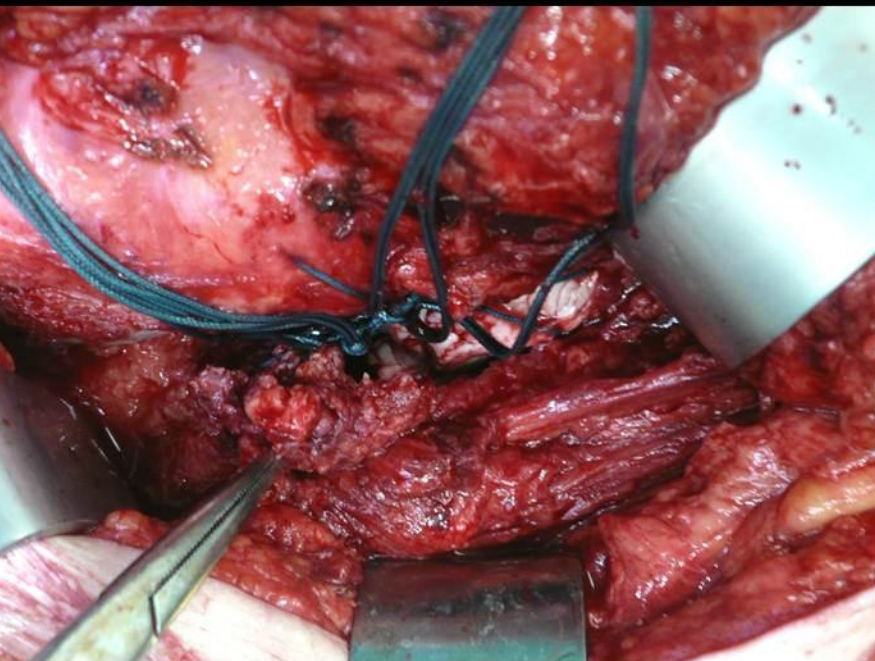
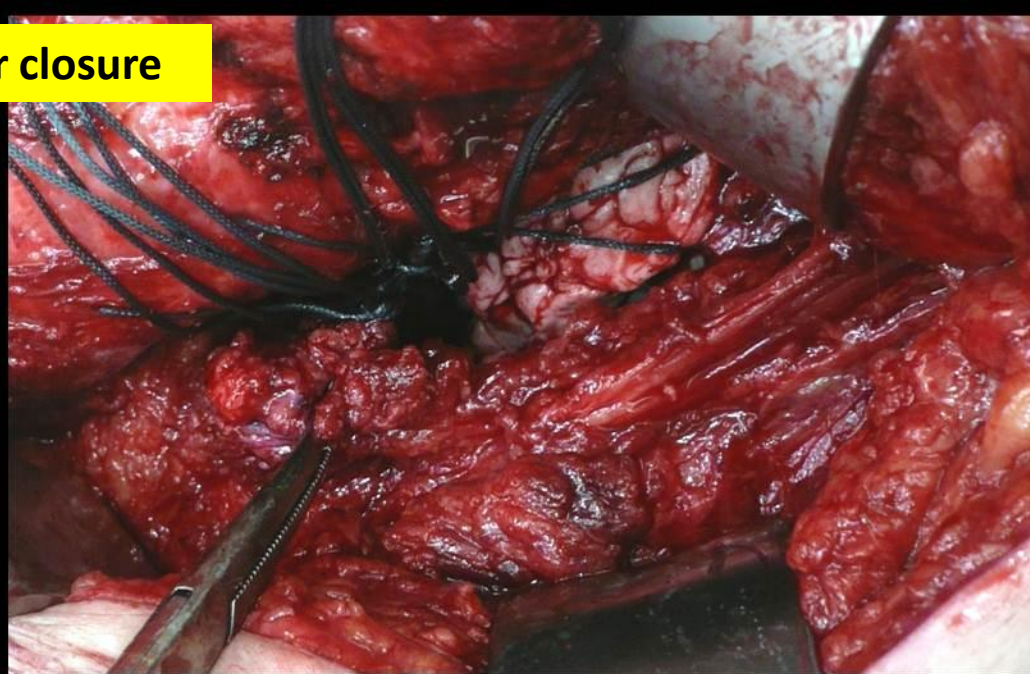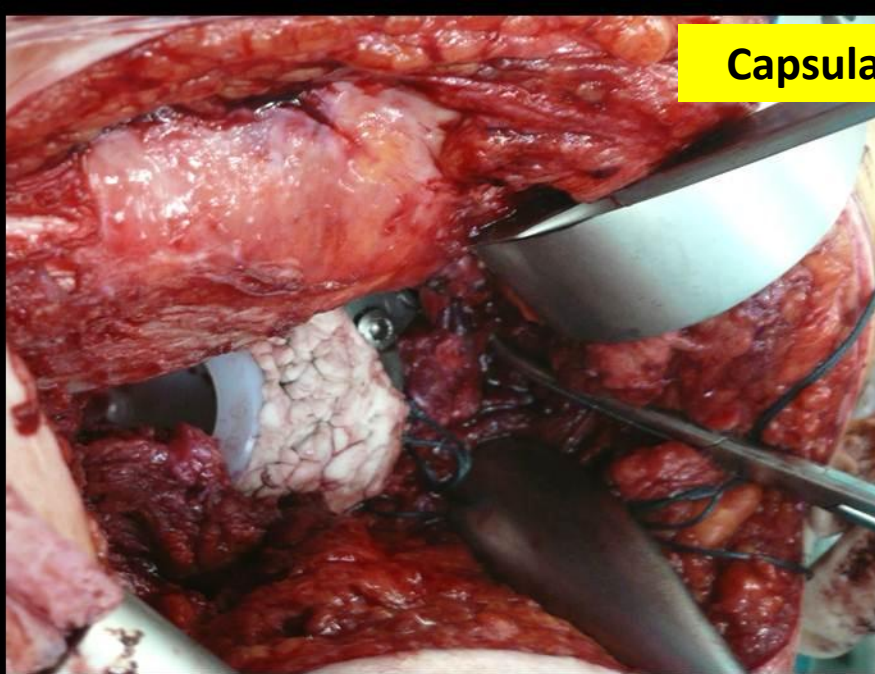
Trabecular metal acetabular cup + particulate/morselized cancellous bone allograft

Metallic antiprotusio/ilioischial cage (Burch-Schneider) + particulate cancellous bone allograft and/or massive bone allograft

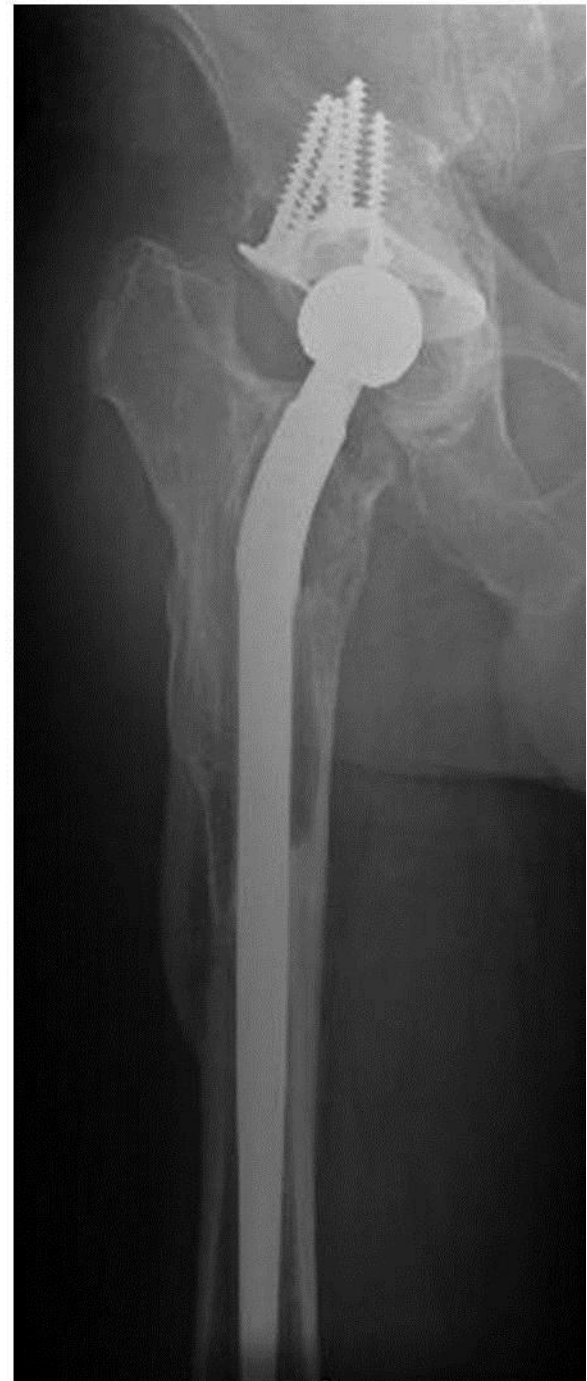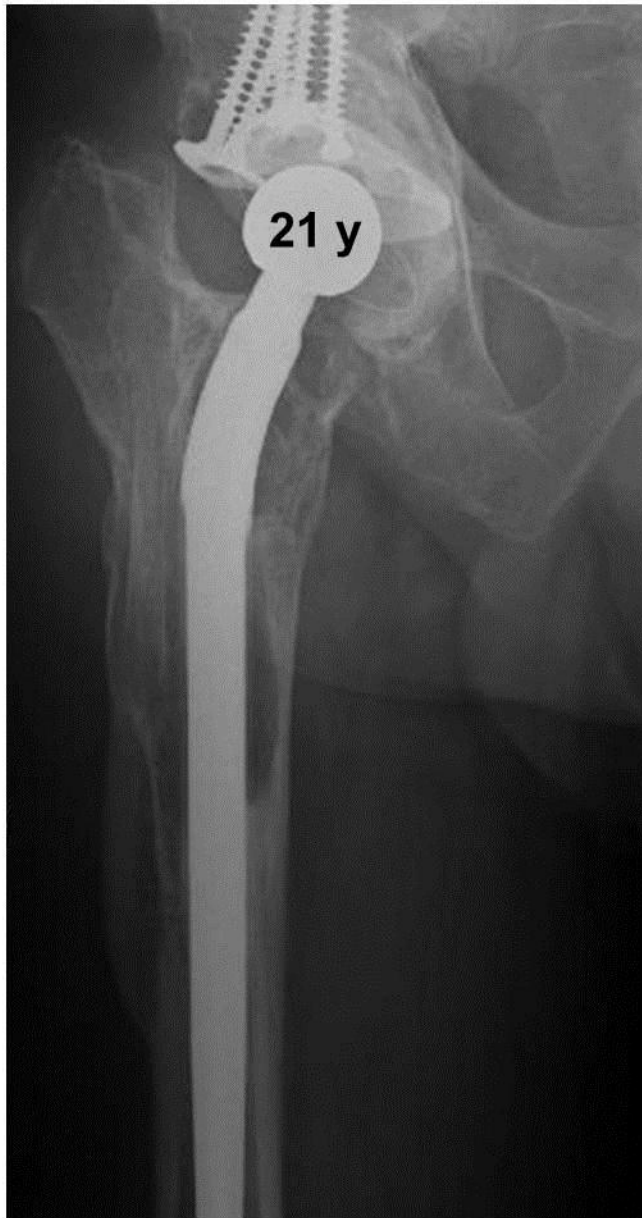The most commonly used reconstruction technique: transfemoral approach, metallic reinforcement ring, conical stem, cancellous bone allograft.

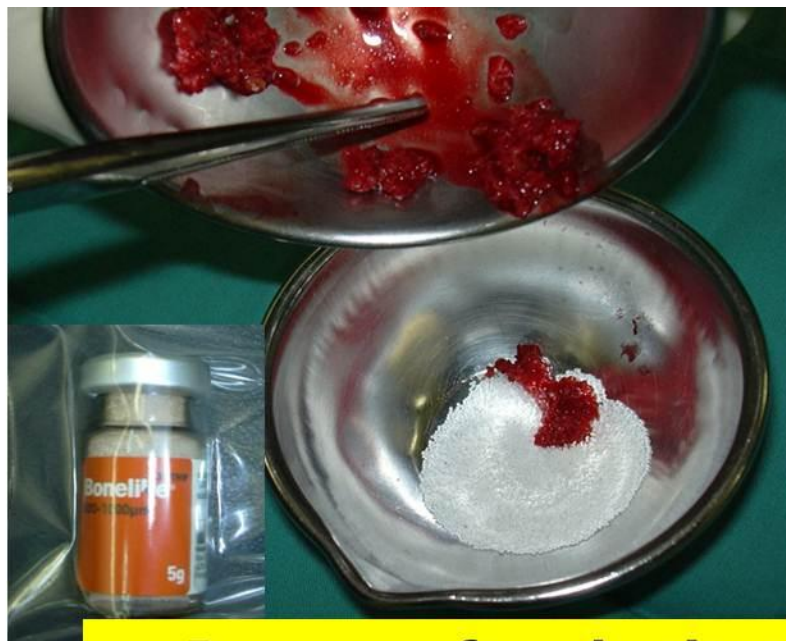
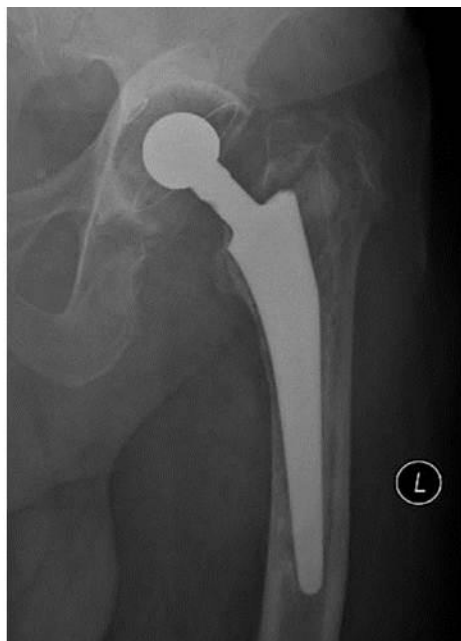
Capsular closure

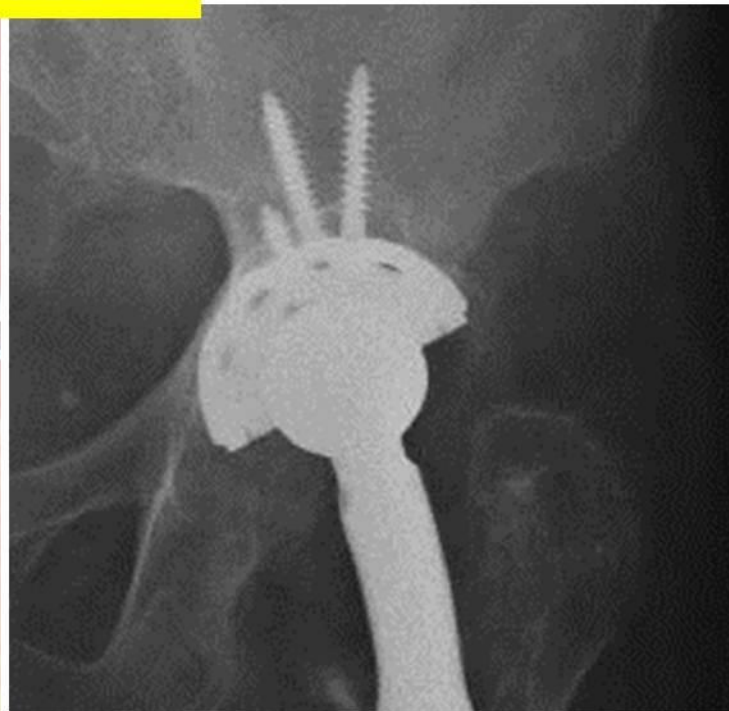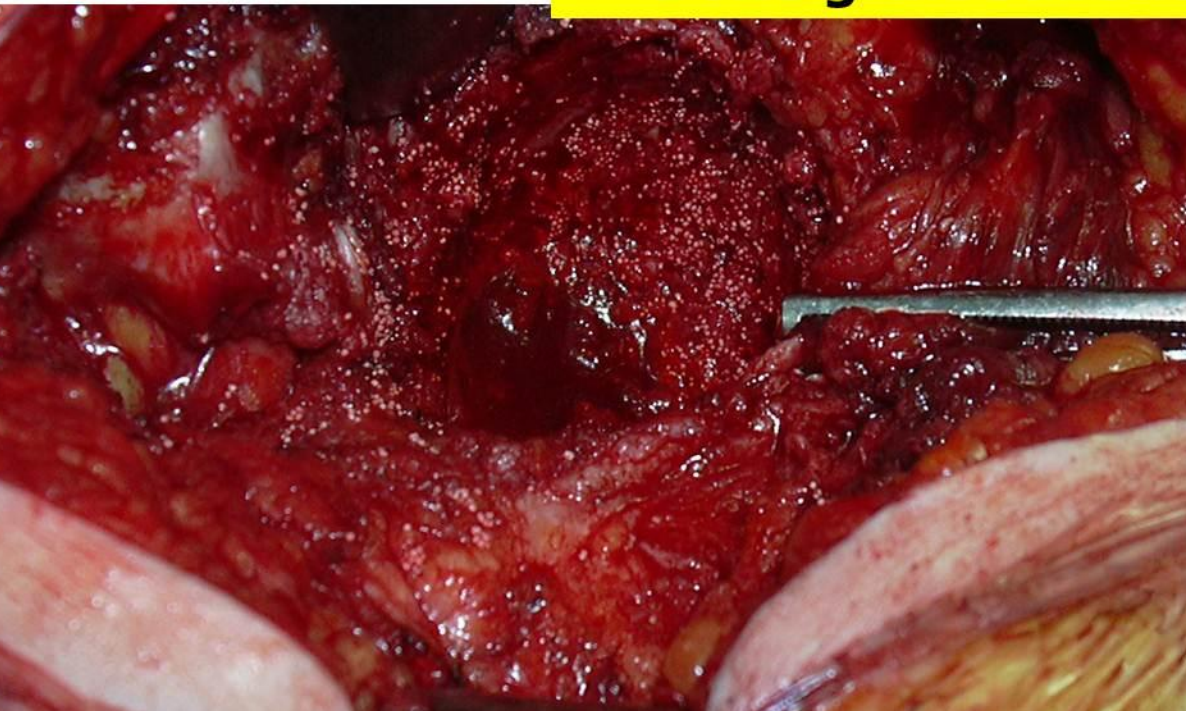



PU 1937..... 2012....good function



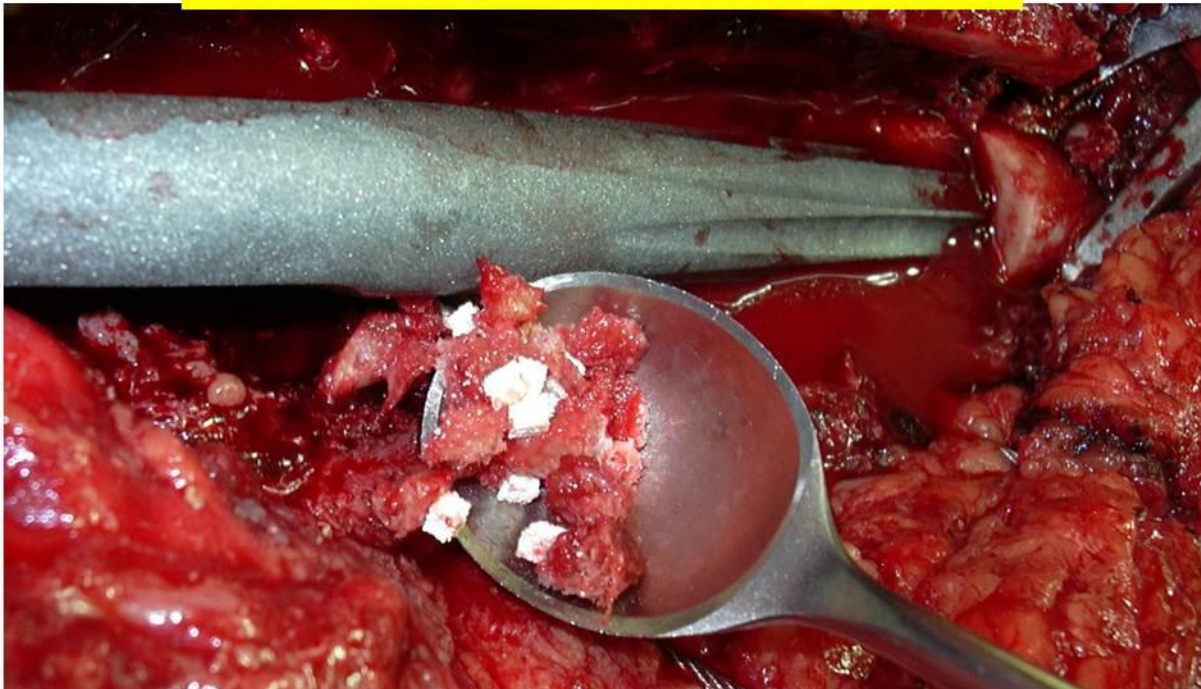

Bone graft substitute



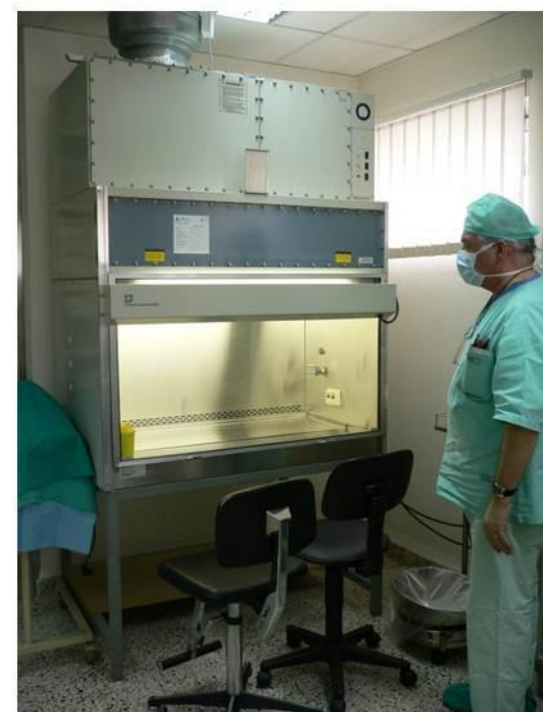

Bone graft substitute

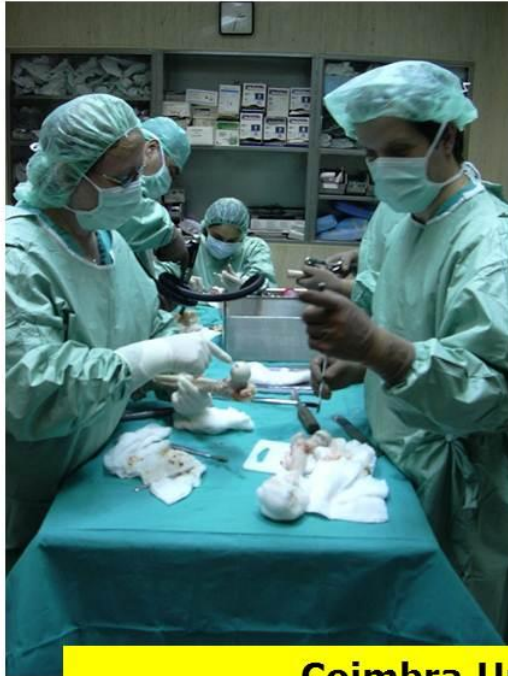



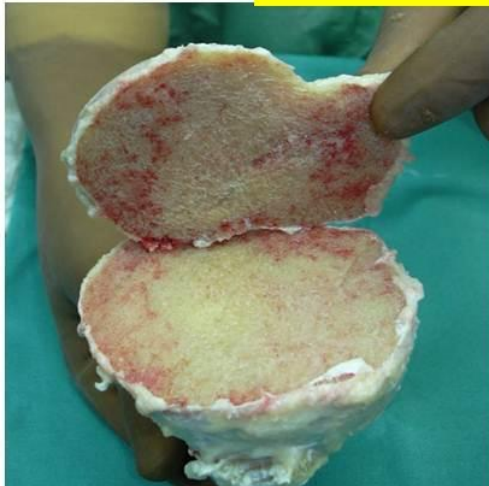Coimbra University Hospitals Tissue Bank



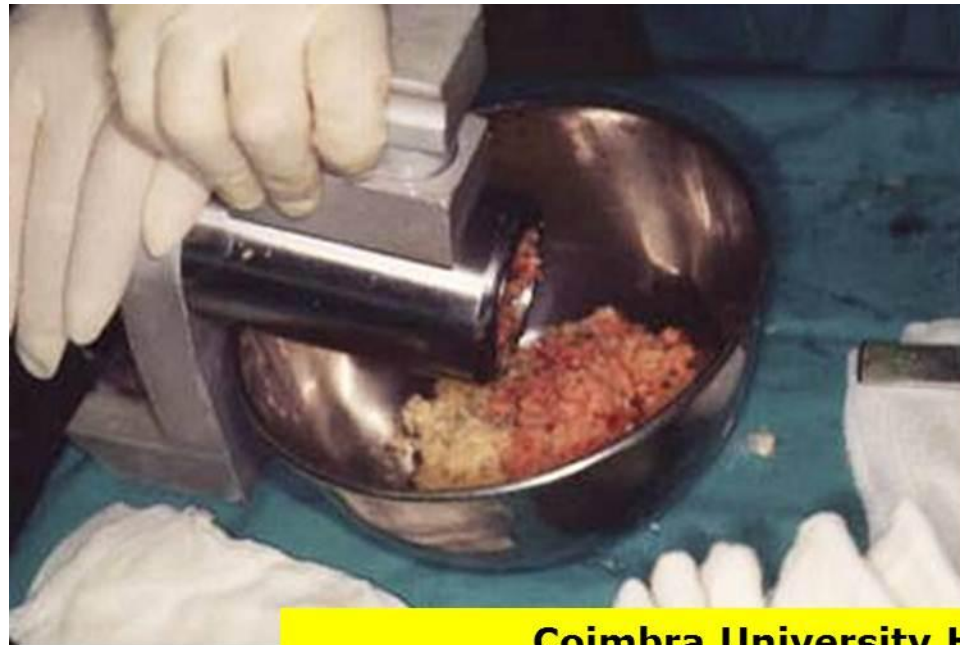
Cryopreserved cancellous bone allografts



Coimbra University Hospitals Tissue Bank



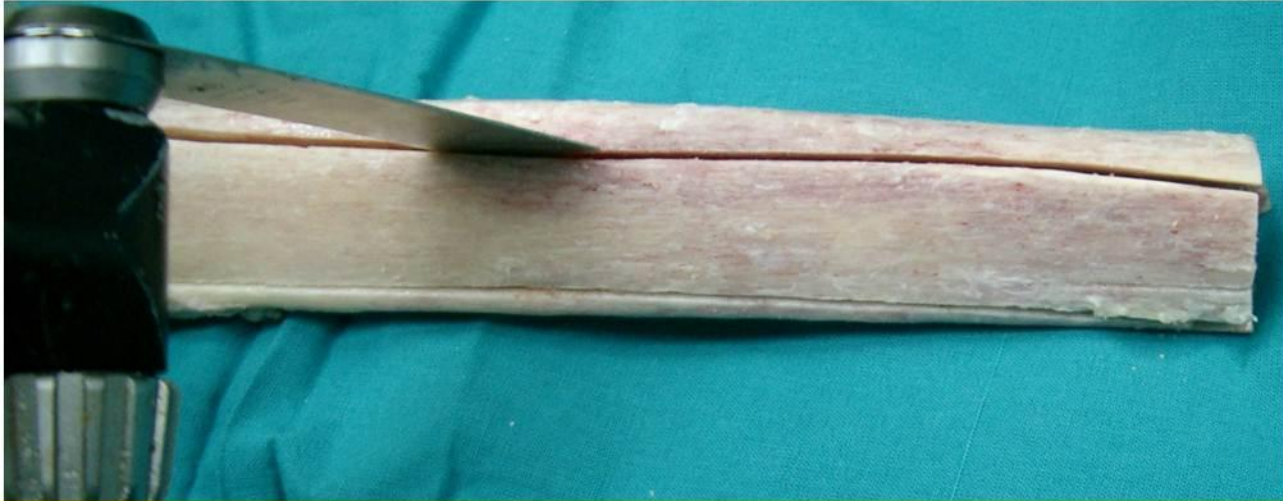Particulate/morselized cancellous bone allografts



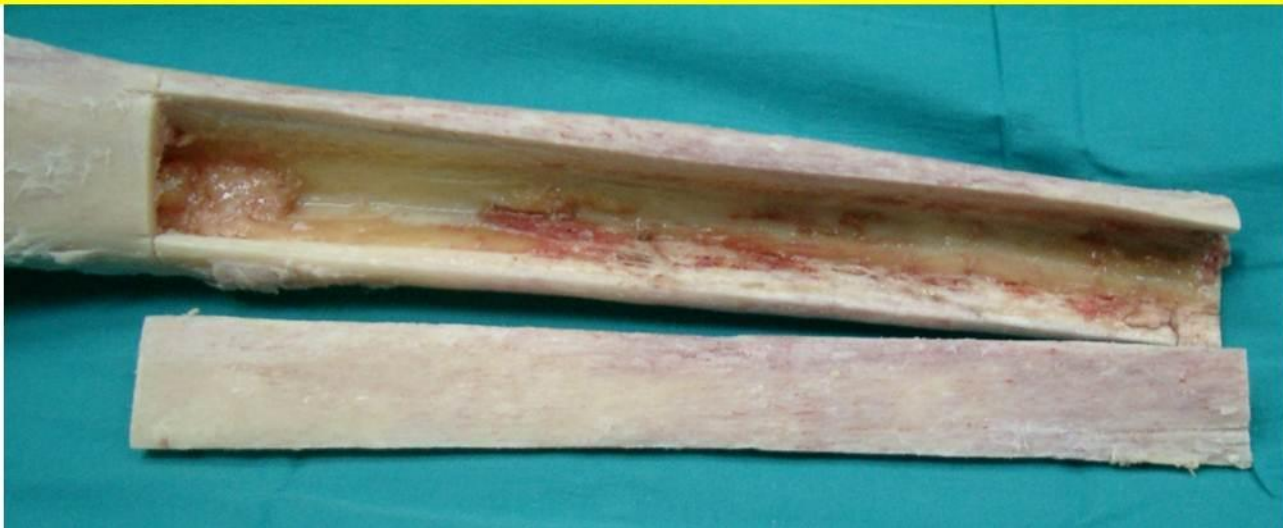Coimbra University Hospitals Tissue Bank

Bone mill

Cortical strut (biological plate)



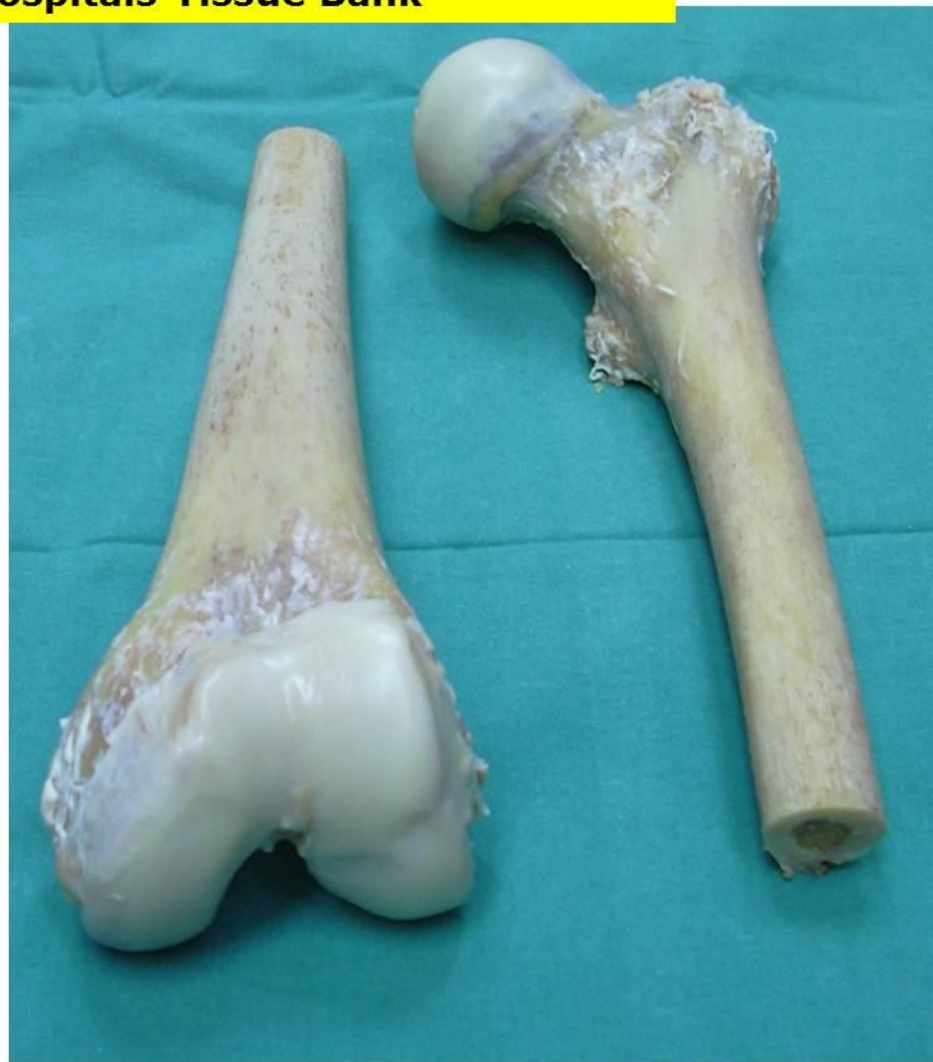Coimbra University Hospitals Tissue Bank



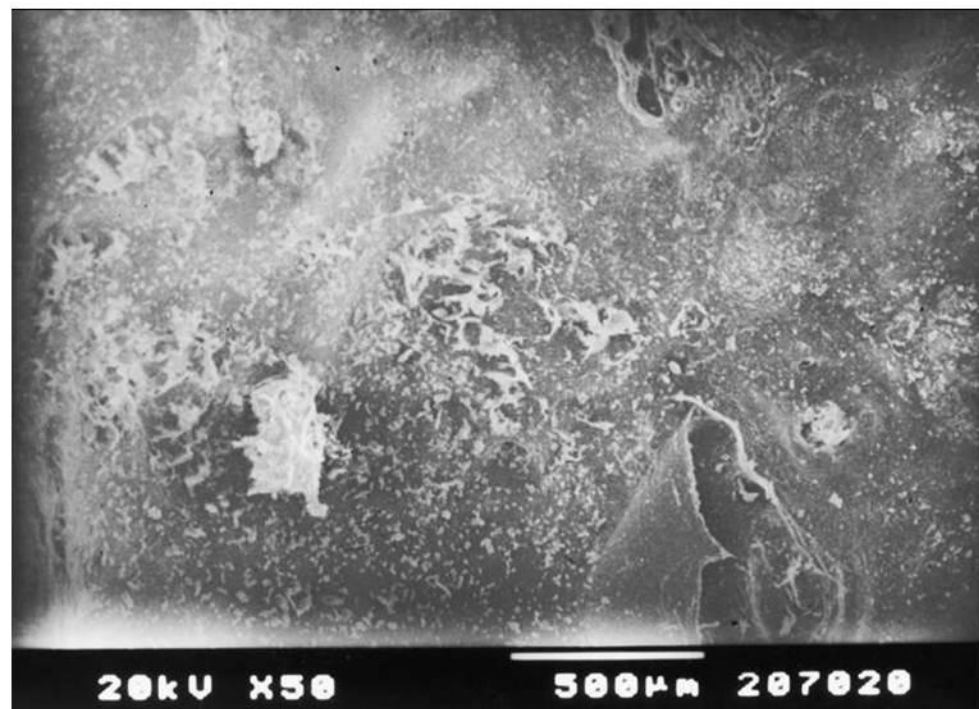
Coimbra University Hospitals Tissue Bank



Cortical bone allograft



Osteoarticular and osteochondral allografts

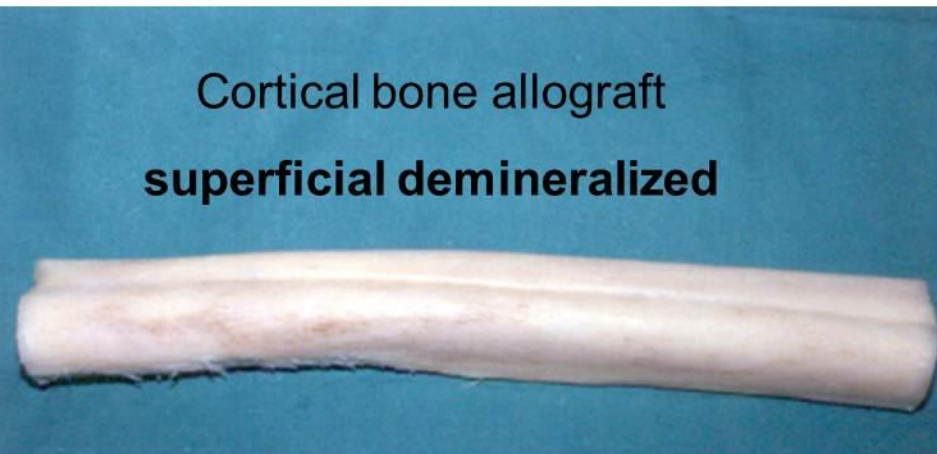


20kV X50

500µm 207020



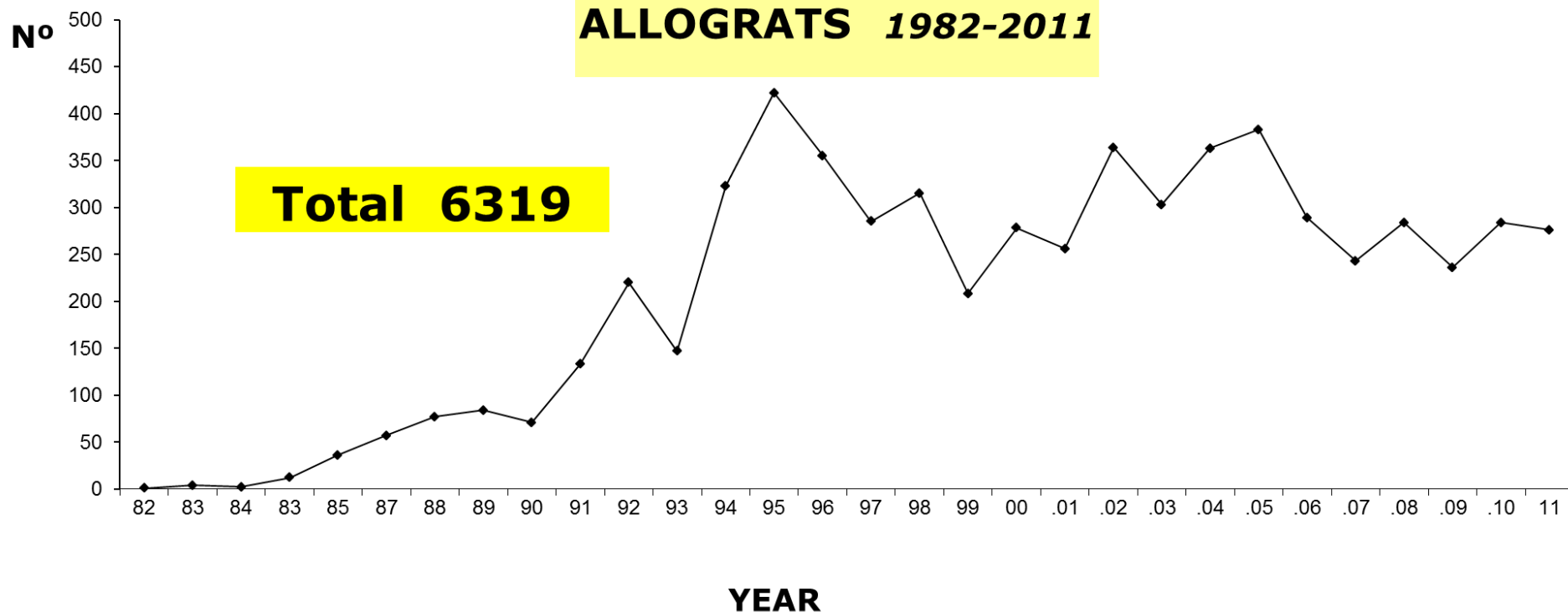
Demineralized bone matrix (DBM)
Cryopreserved



Cortical bone allograft
superficially demineralized

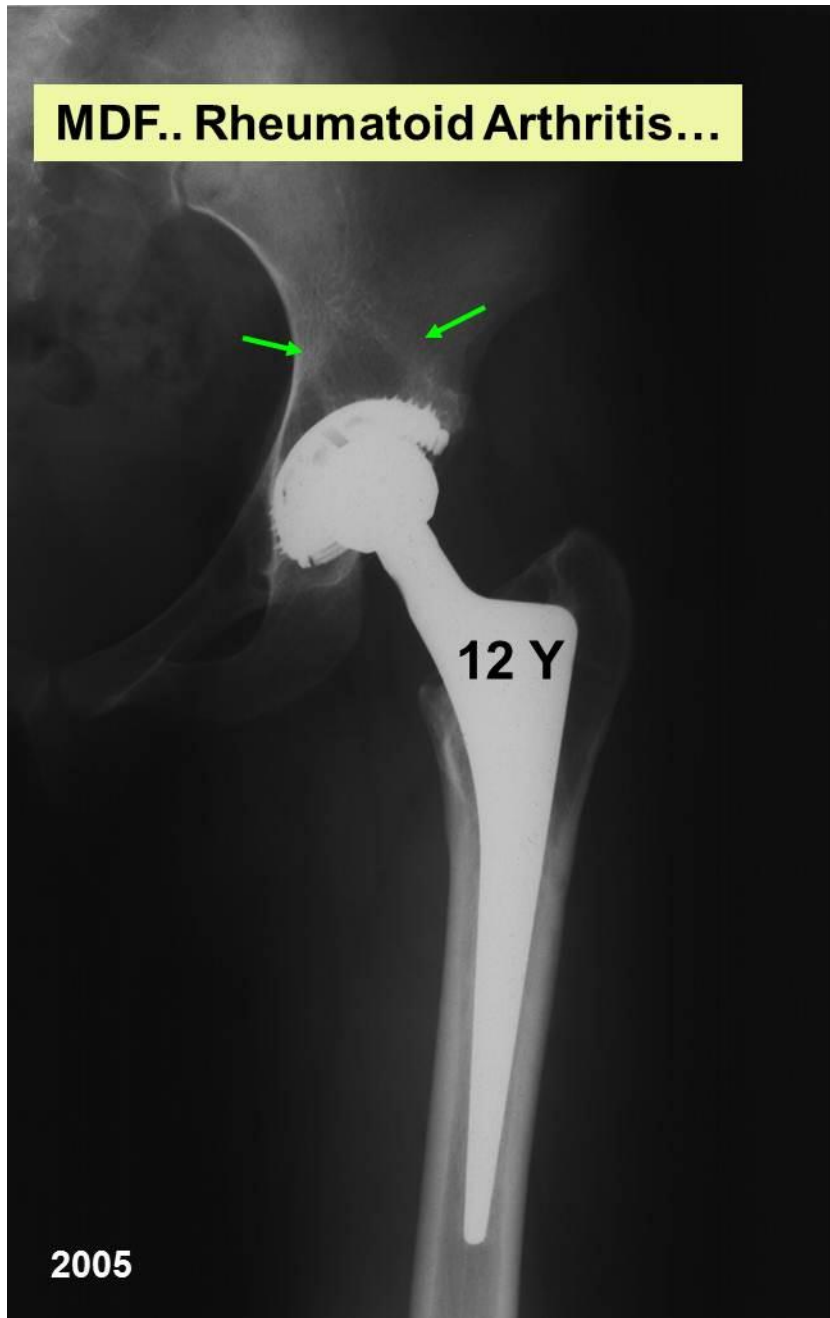
**DBM is the only osteoinductive
bone allograft material (BMP)**

Coimbra University Hospitals Tissue Bank



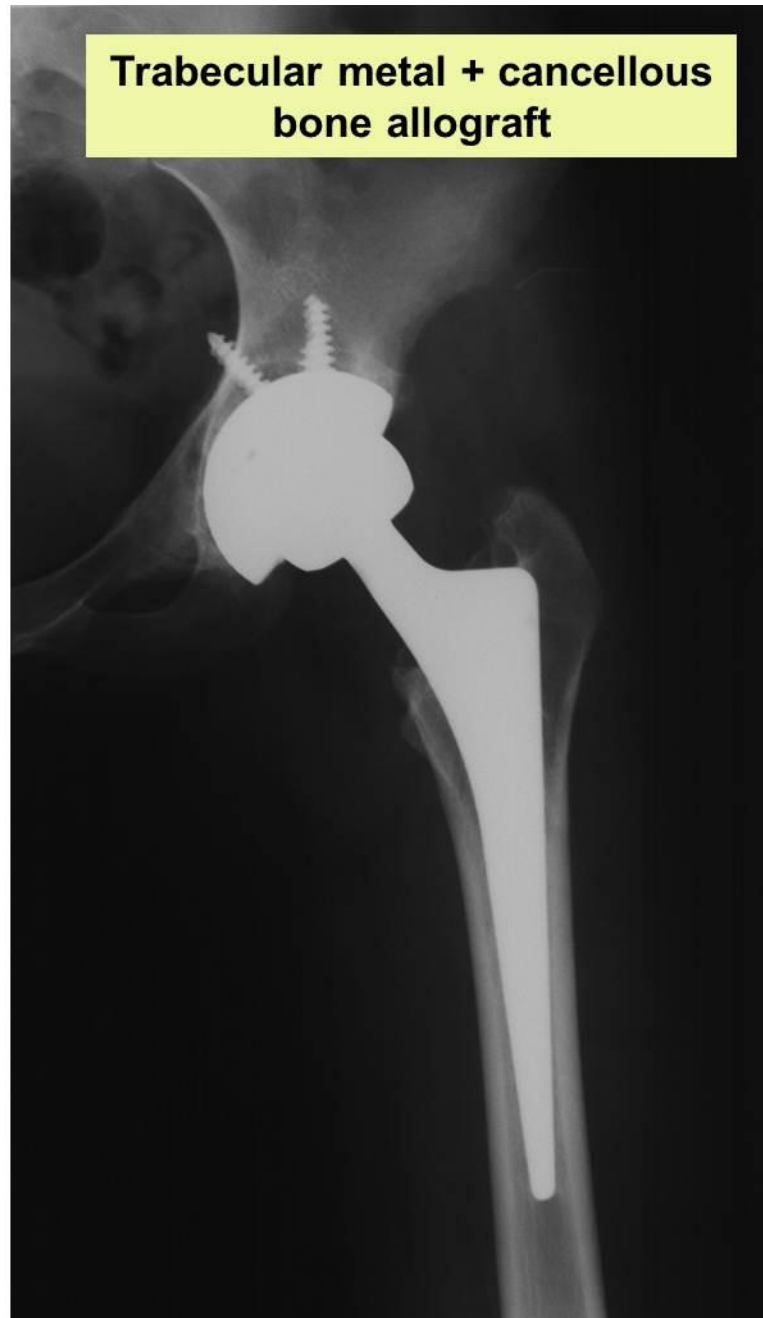1982-1	83-4	84-2	85-12	86-38	87-57	88-37	89-84	90-71	91-133
92-220	93-147	94-323	95-422	96-355	97-285	98-315	99-208	00-278	01-256
02-364	03-303	04-363	05-383	06-289	07-243	08-284	09-236	10-284	11-276

MDF.. Rheumatoid Arthritis...

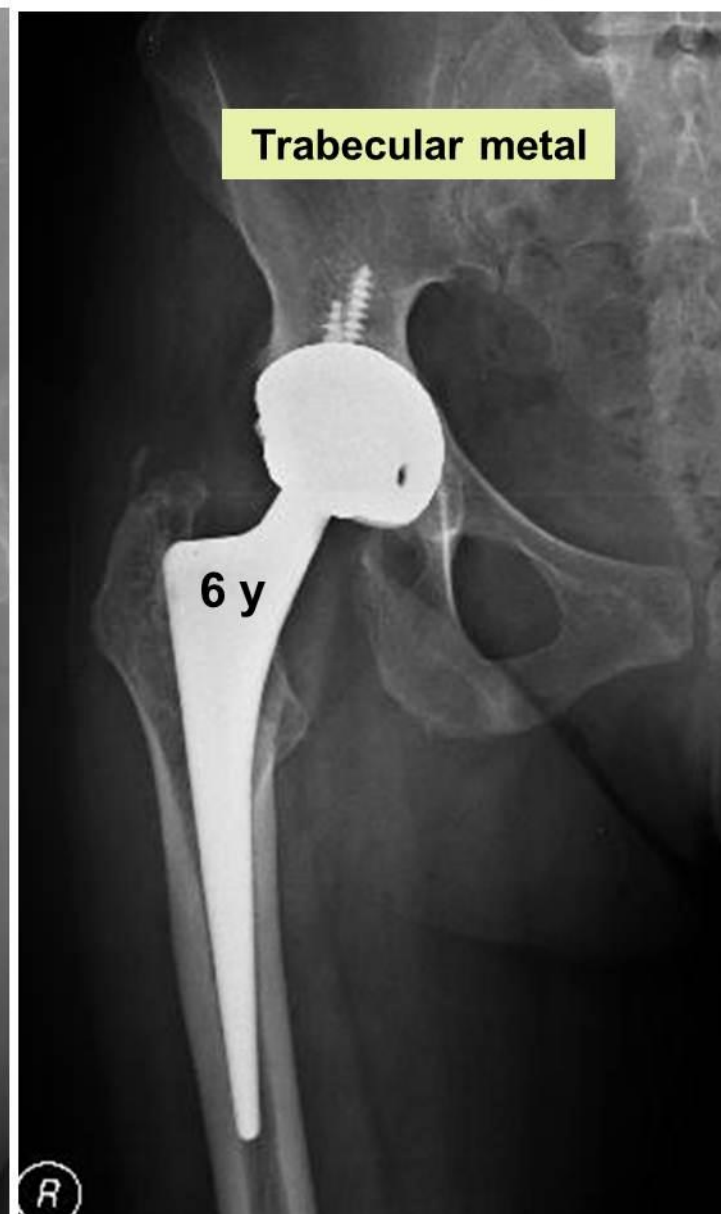
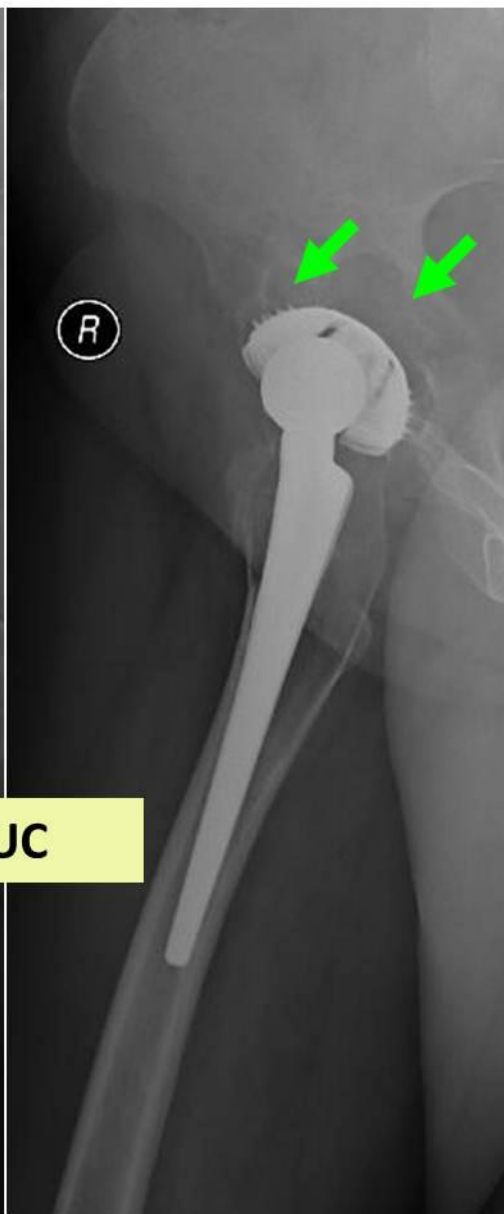
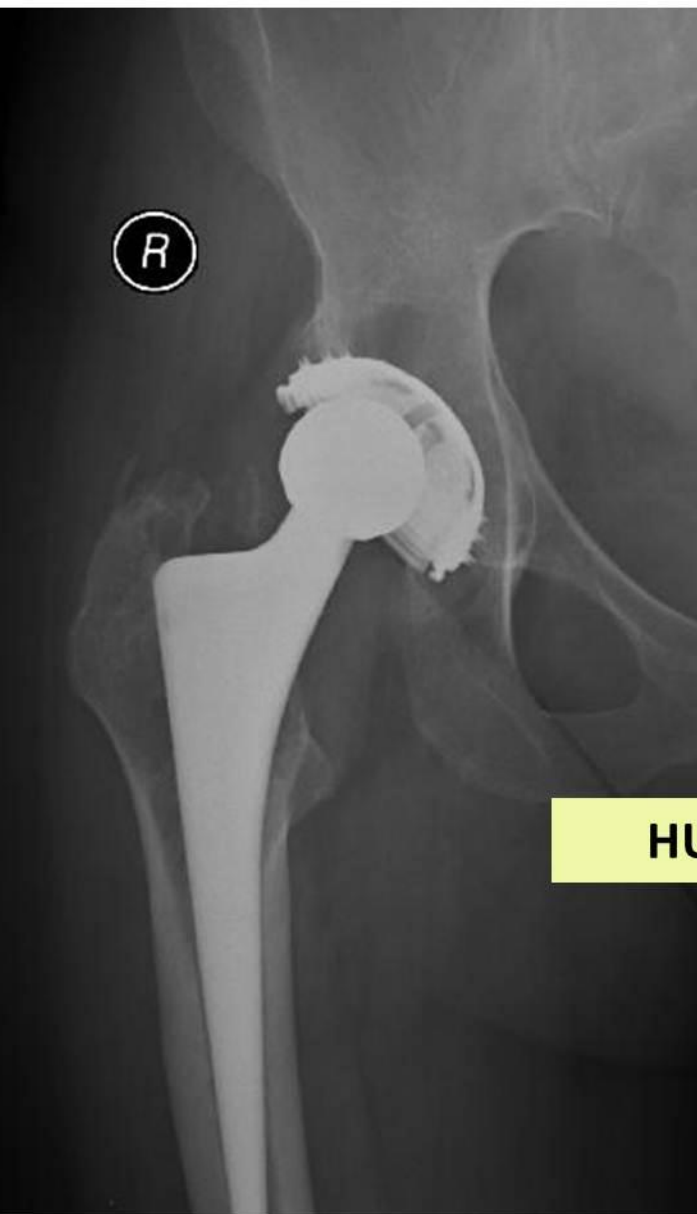
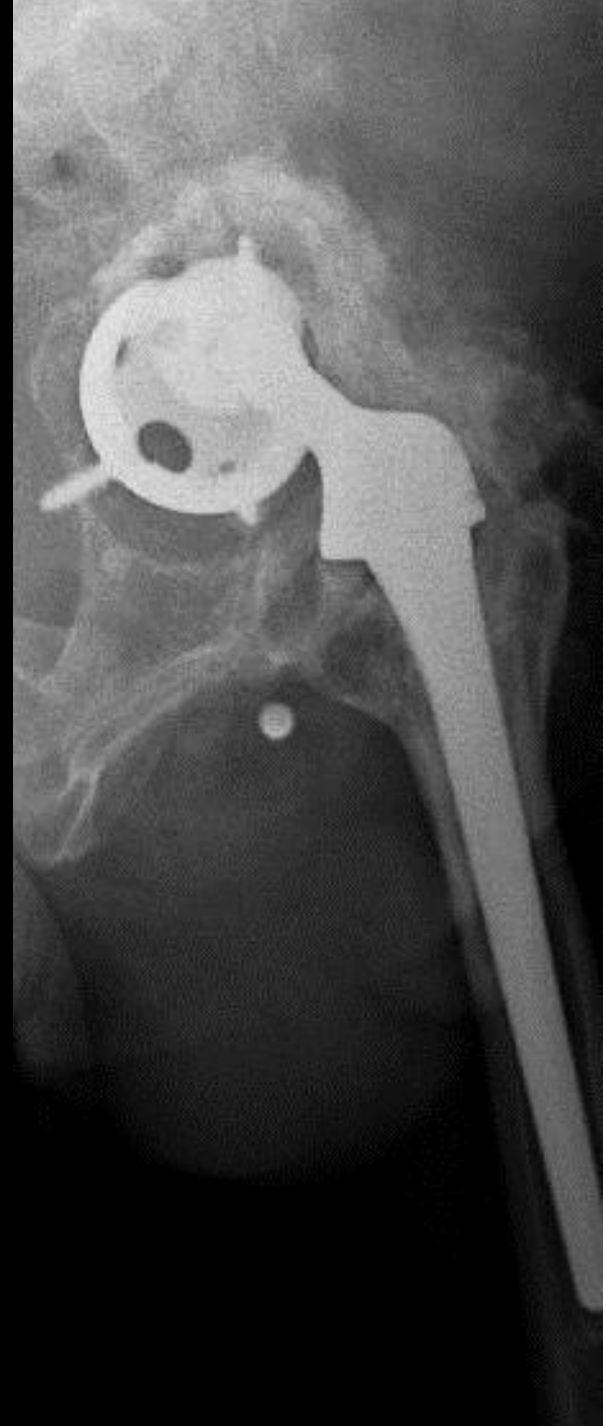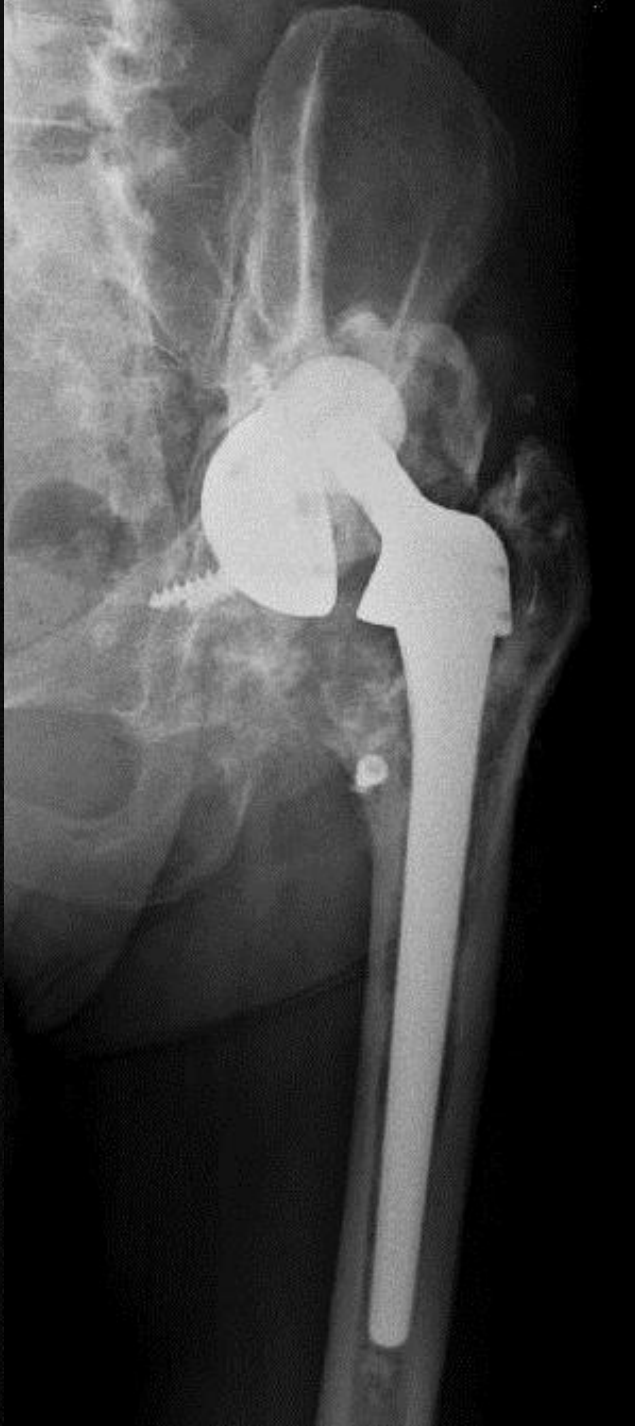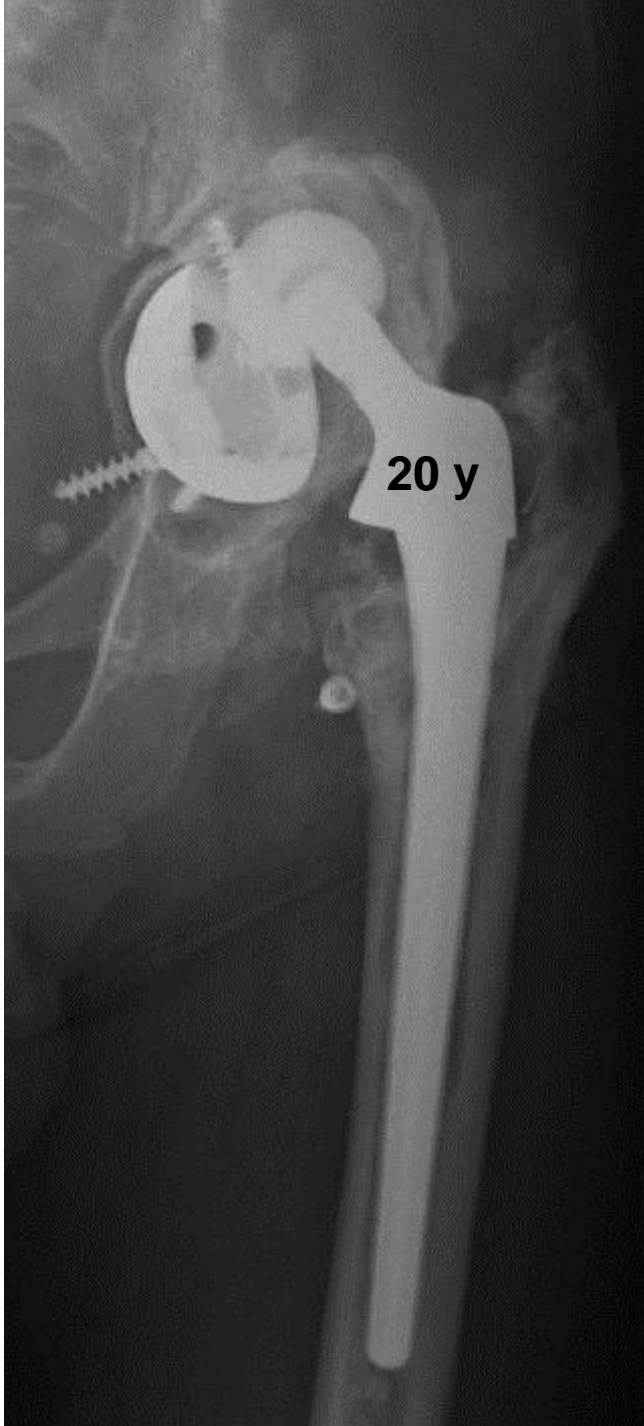2005

**Trabecular metal + cancellous
bone allograft**



Cancellous bone allograft

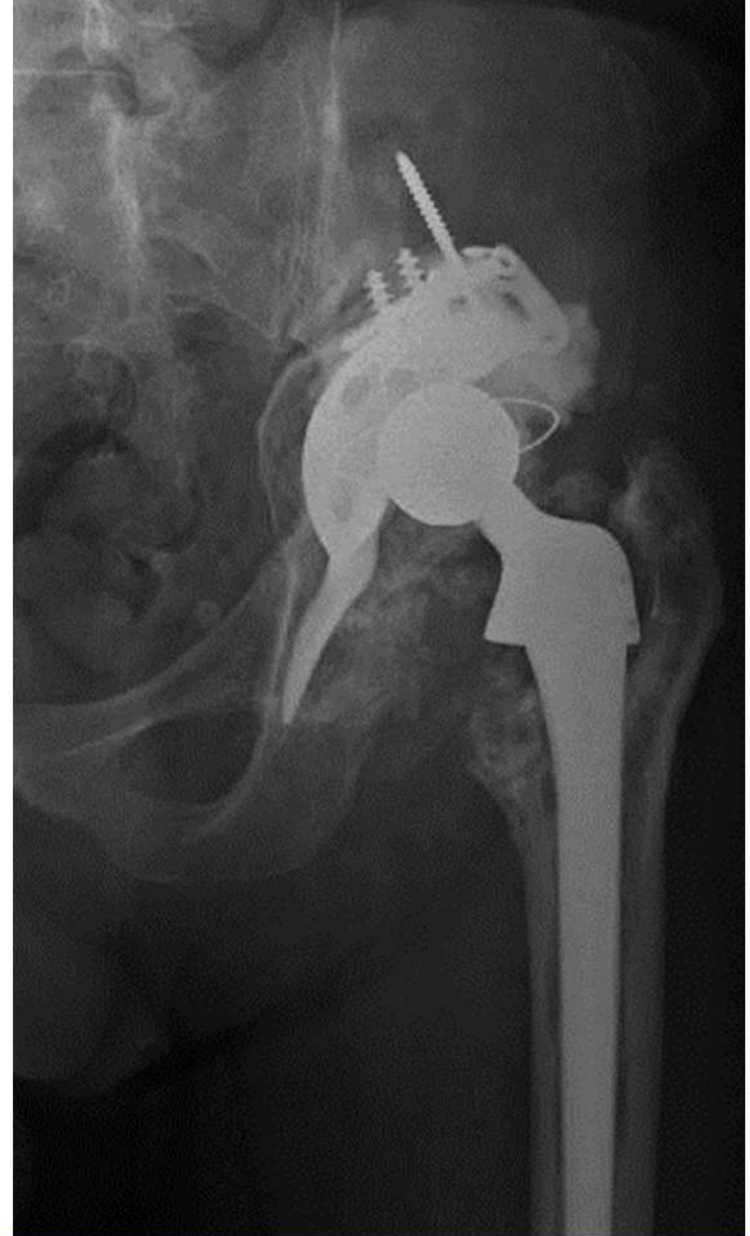



1957.....

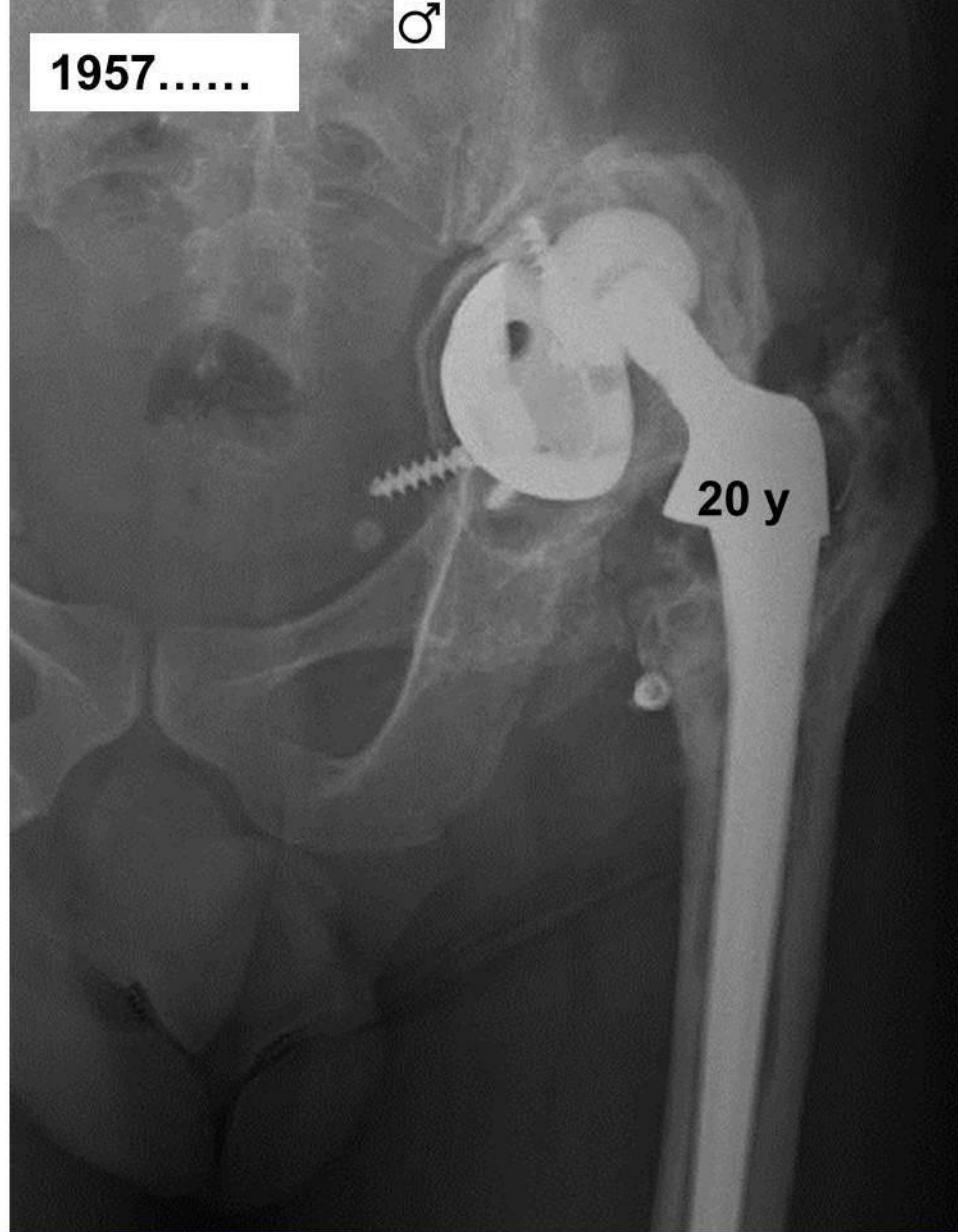
♂

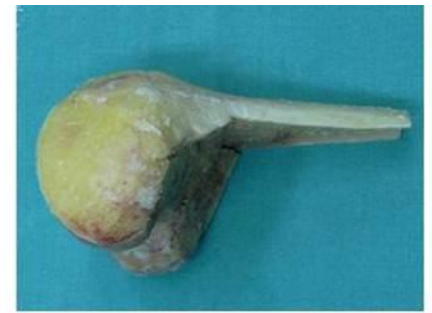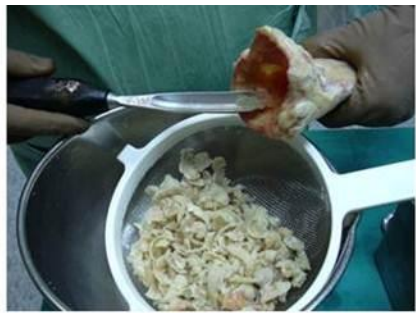20 y



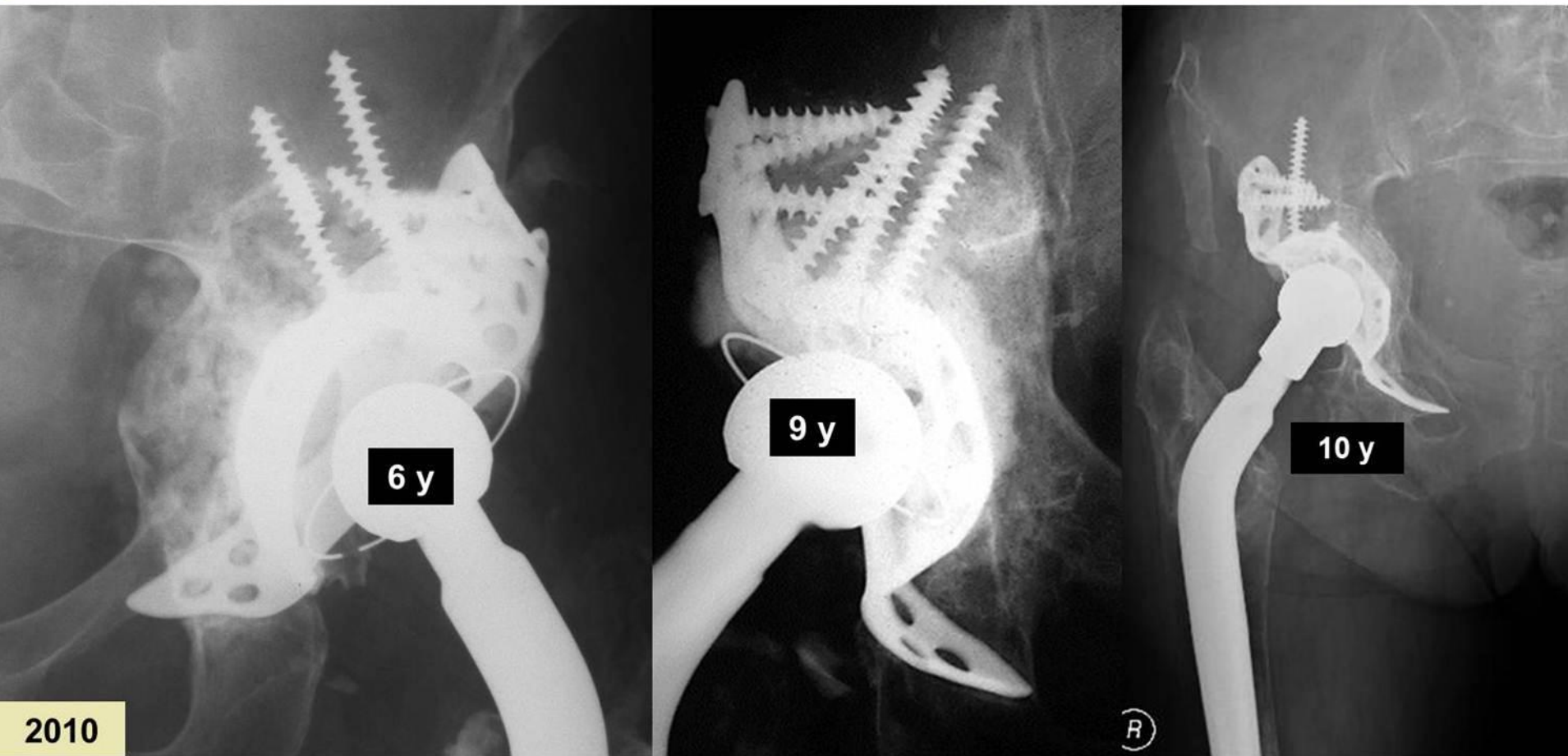
Metallic antiprotusio/ilioischial cage + particulate cancellous bone allograft

2009





Metallic antiprotusio/ilioischial cage + bone allograft



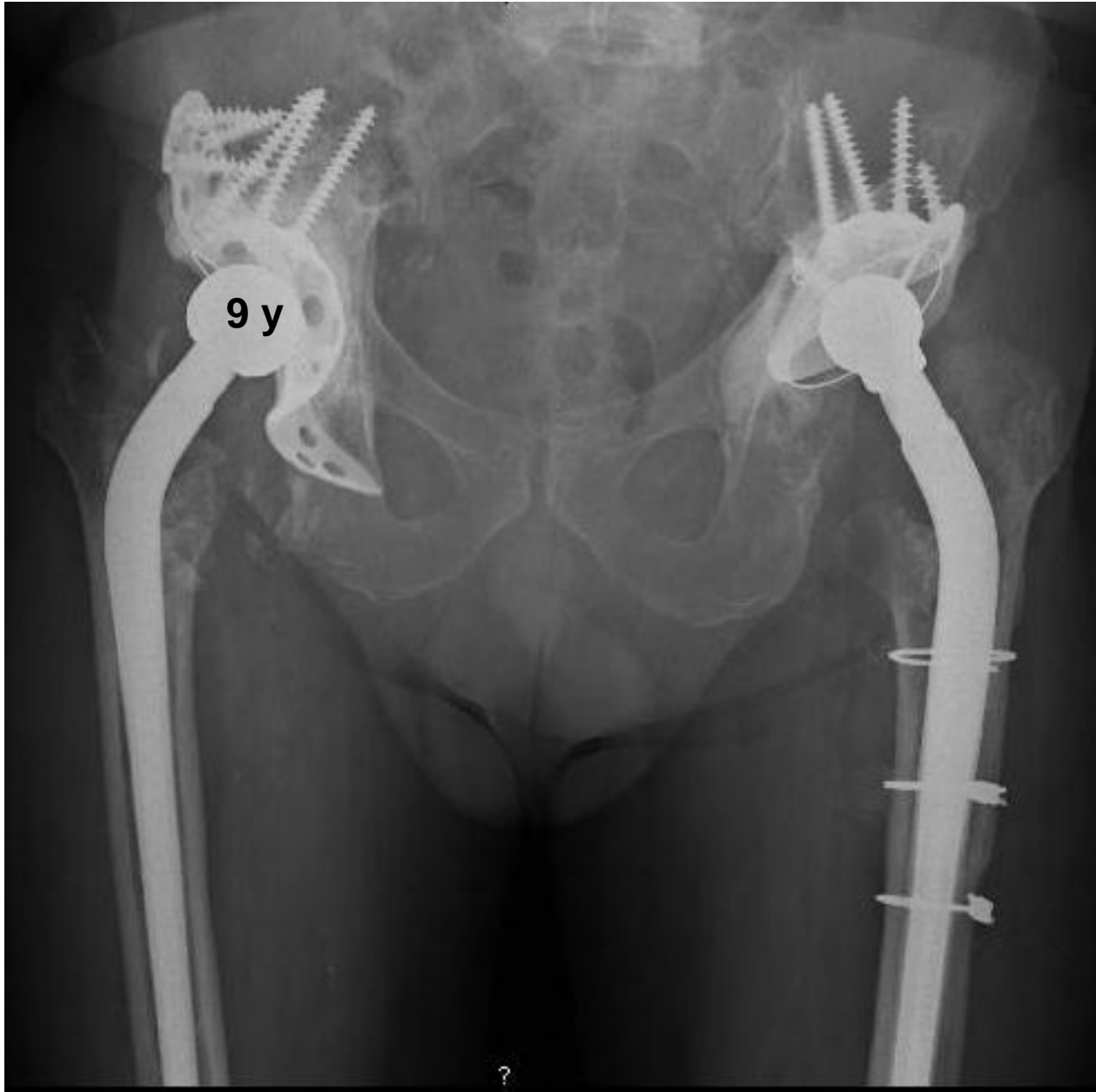2010

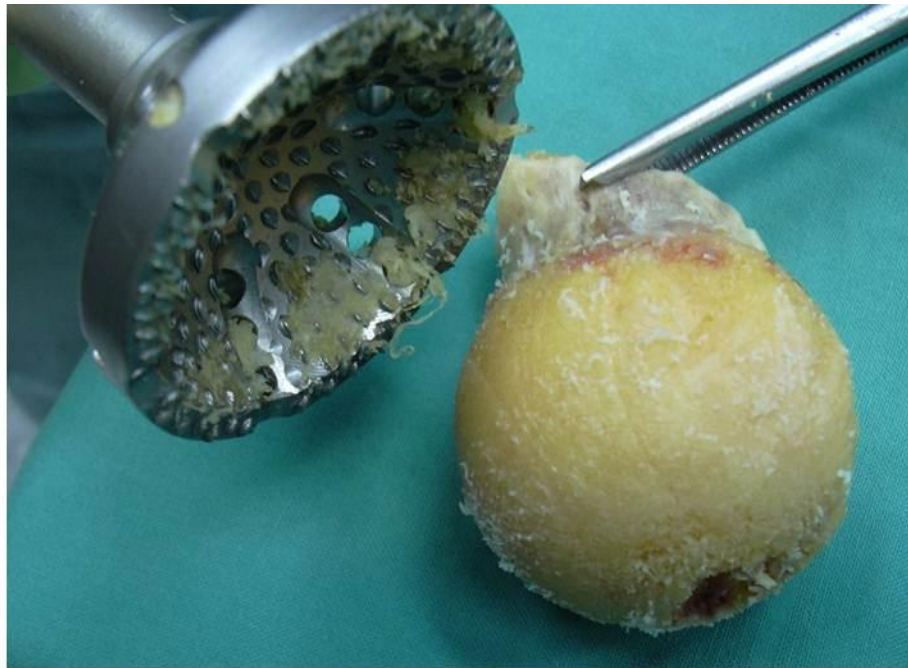
6 y

9 y

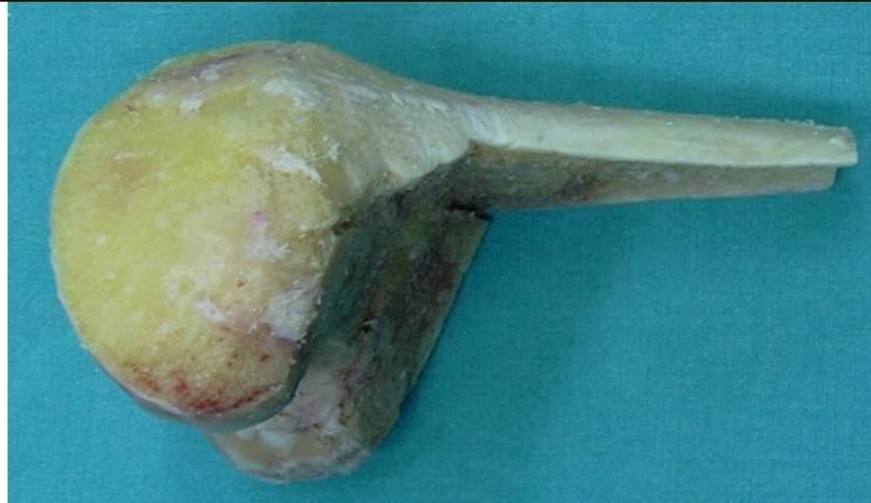10 y

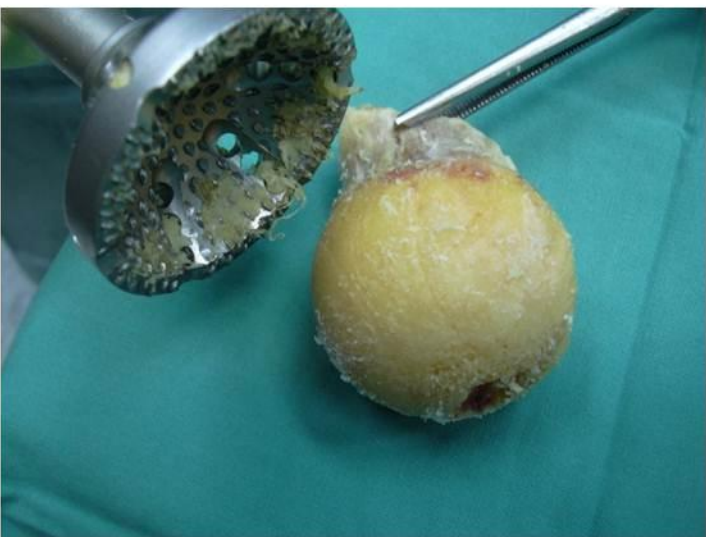
R



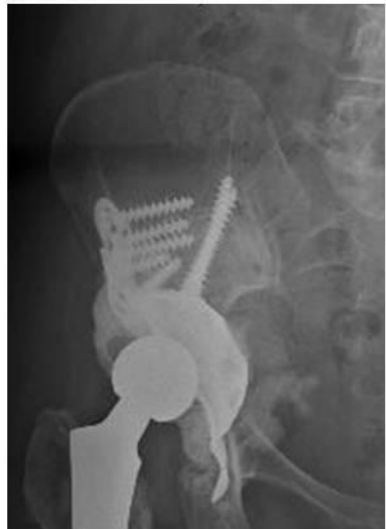
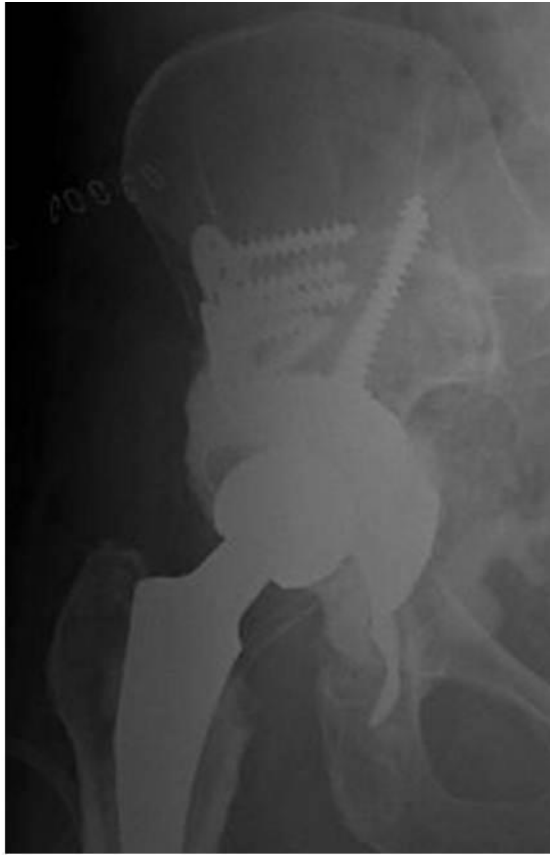
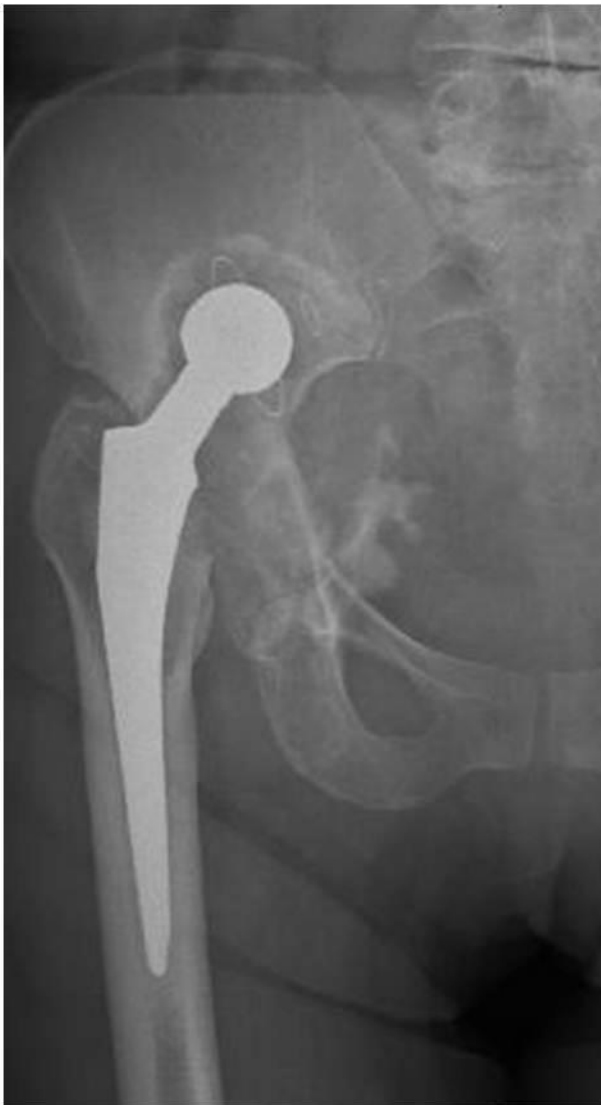Bone allografts: femoral head, femoral condyles (HUC)

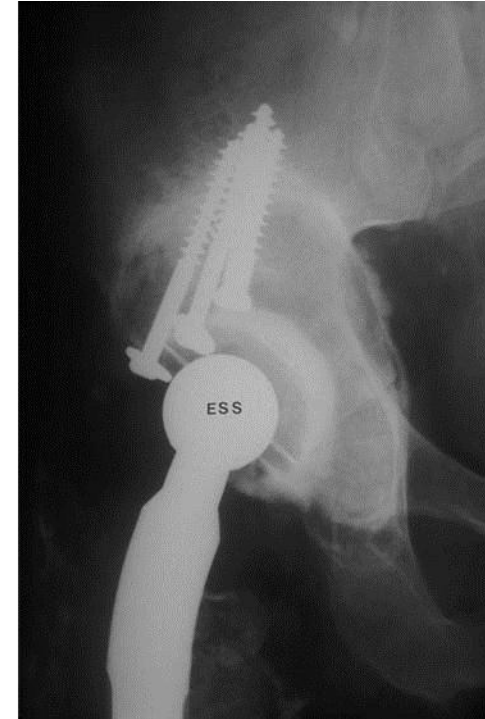
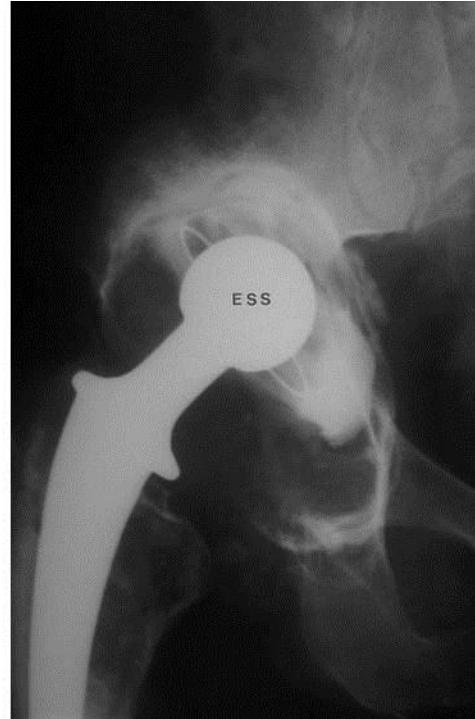
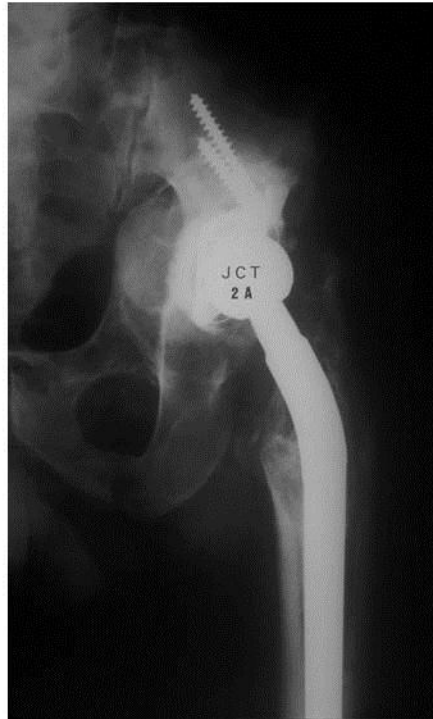
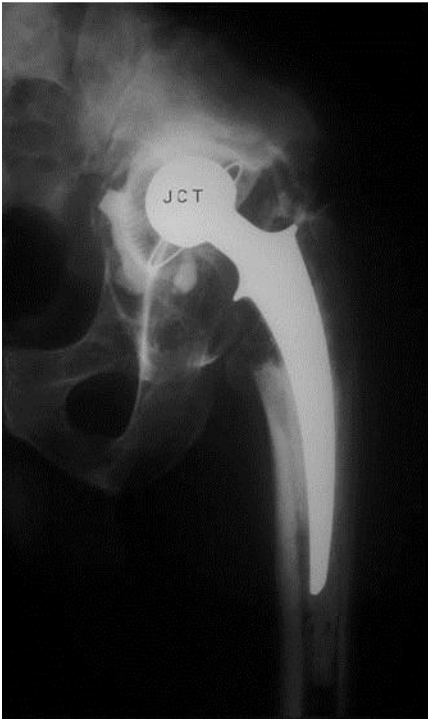


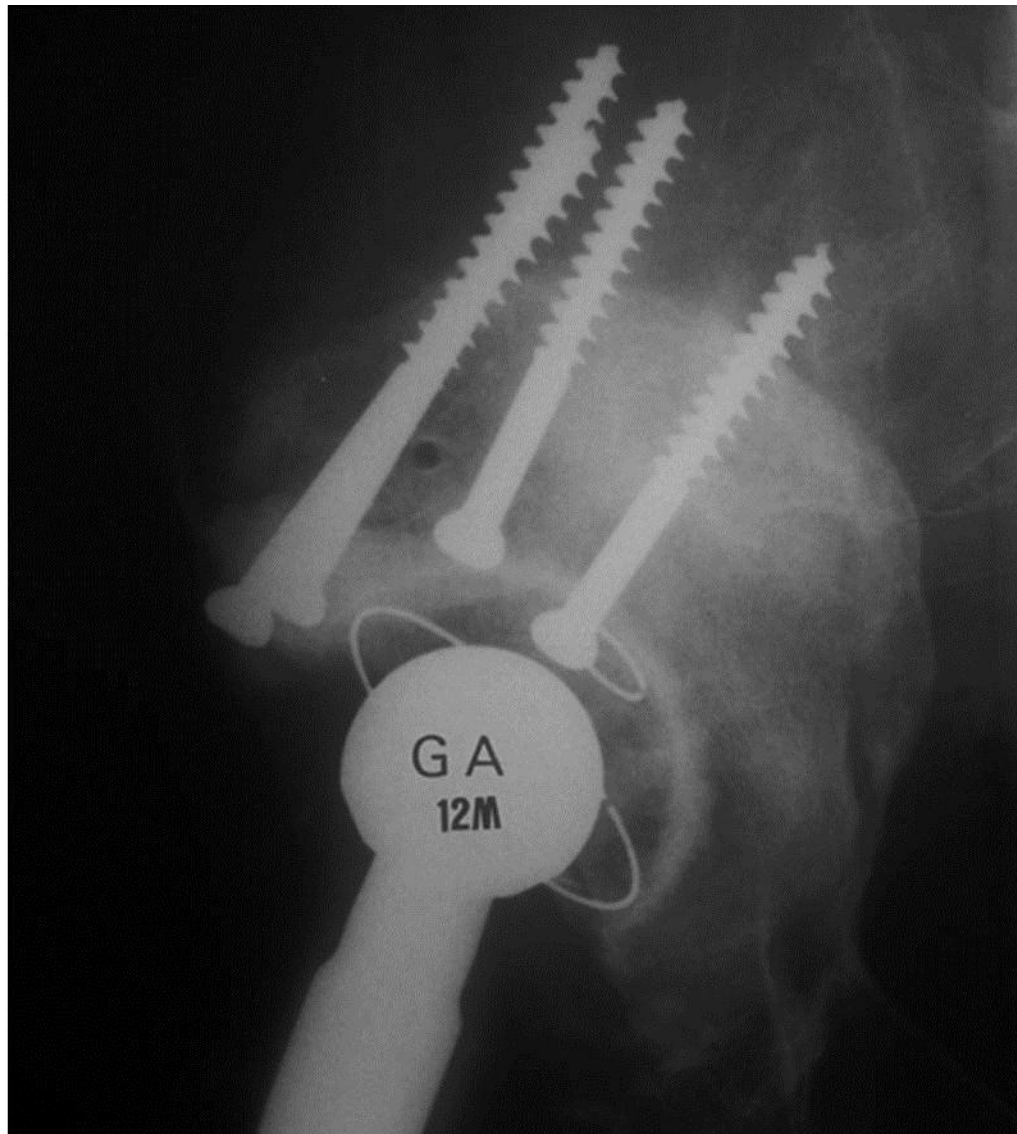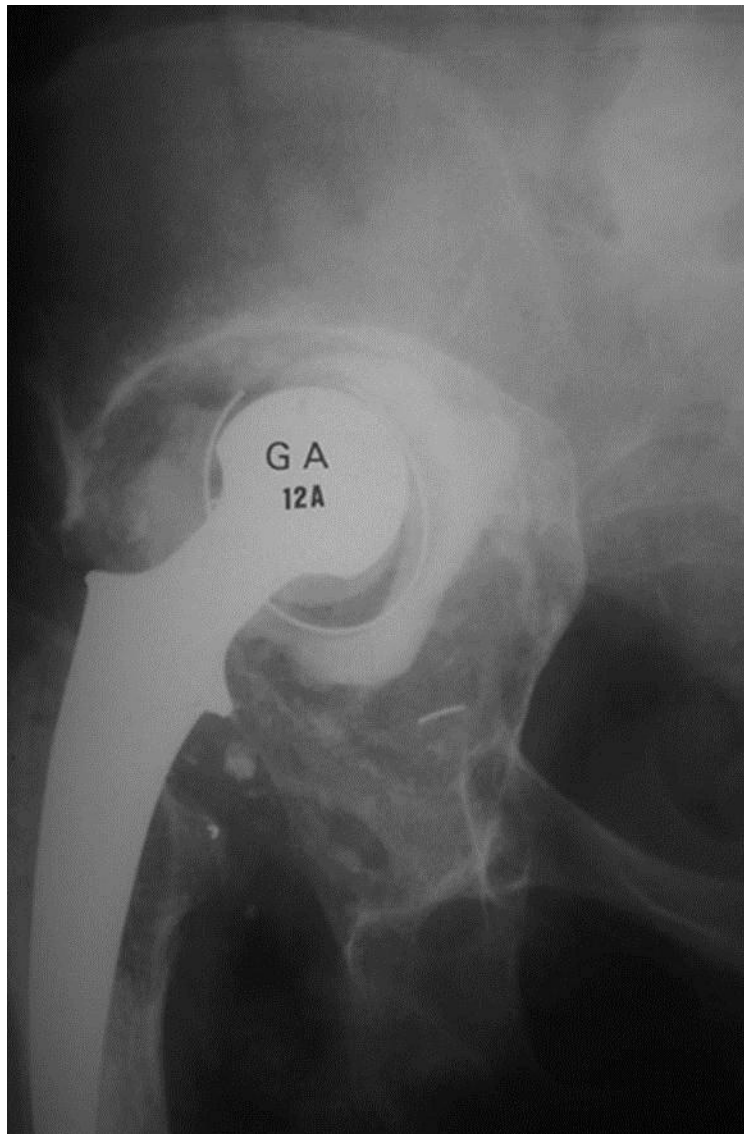
HUC



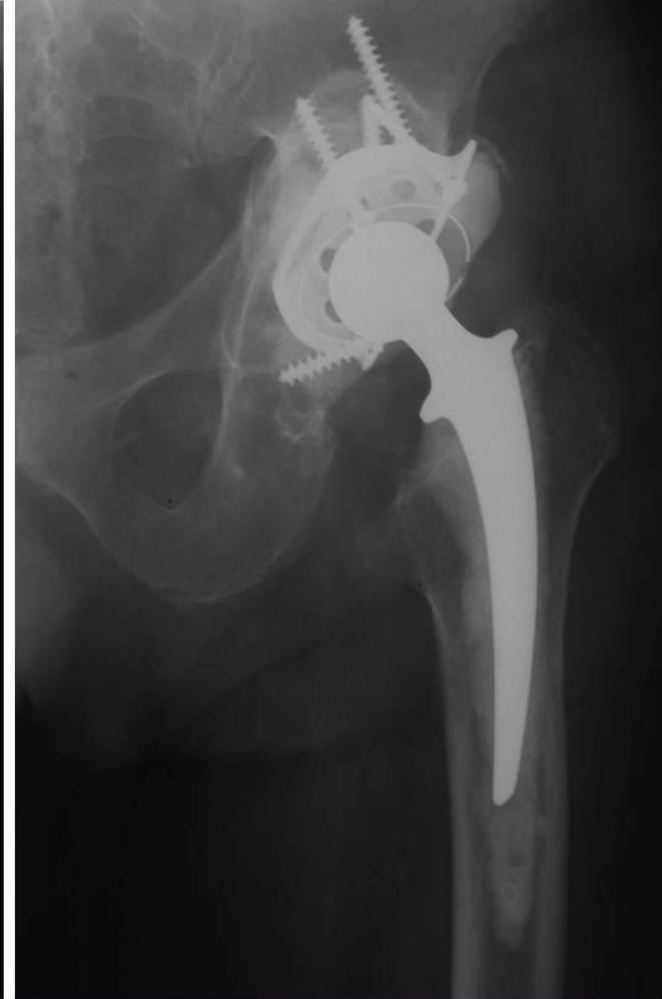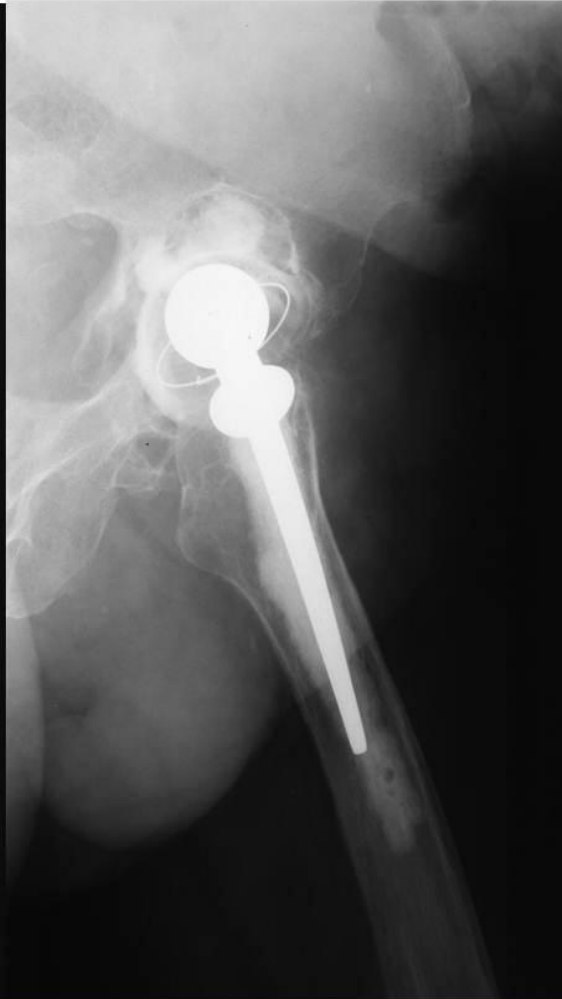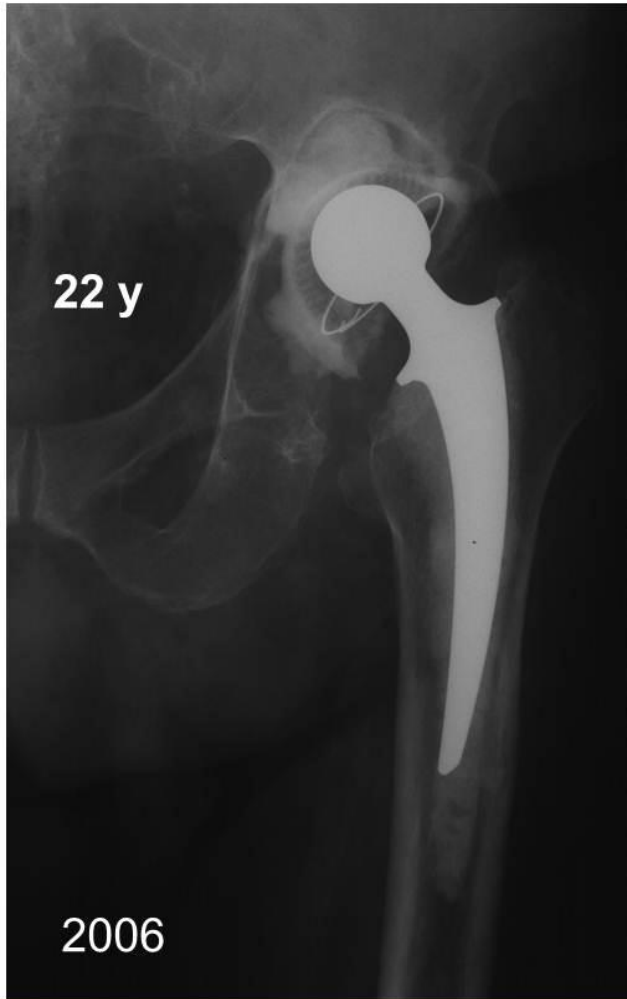Acetabular reconstruction with a massive allograft (femoral condyles)



Acetabular reconstruction with a massive allograft (femoral condyles)



JFP 1916..... 90 y, cardiac risk



Cement-within-cement femoral arthroplasty revision

Cement-within-cement femoral arthroplasty revision

Indications

cement mantle is intact

the stem is broken

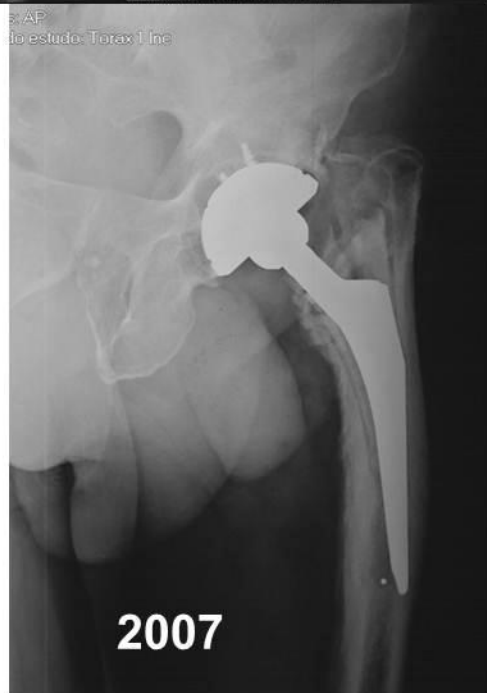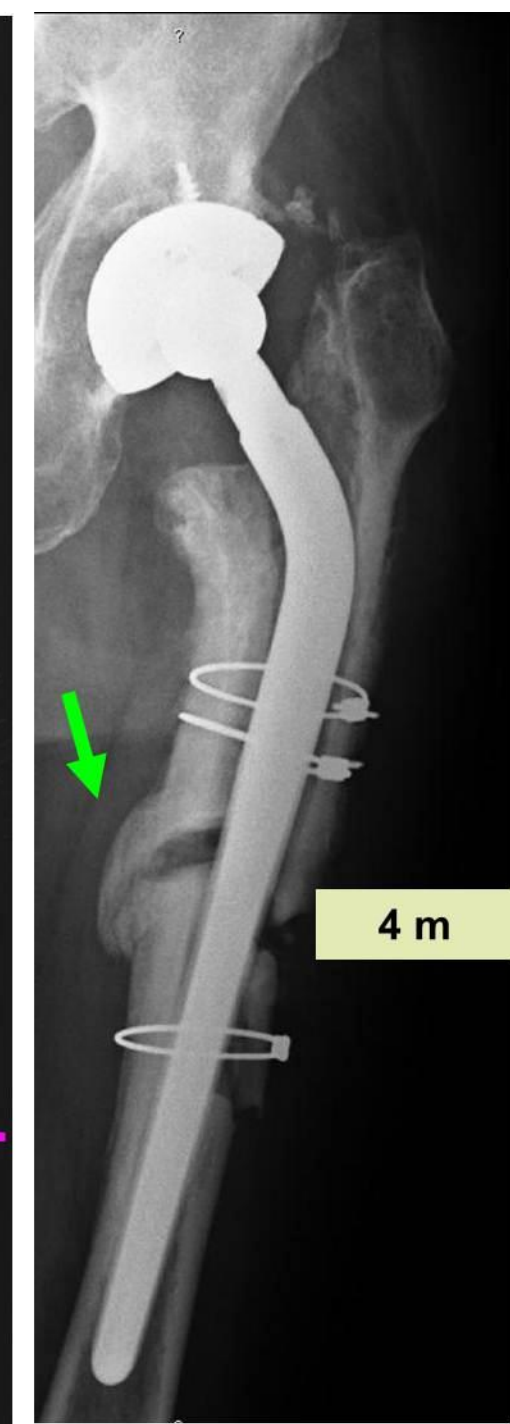
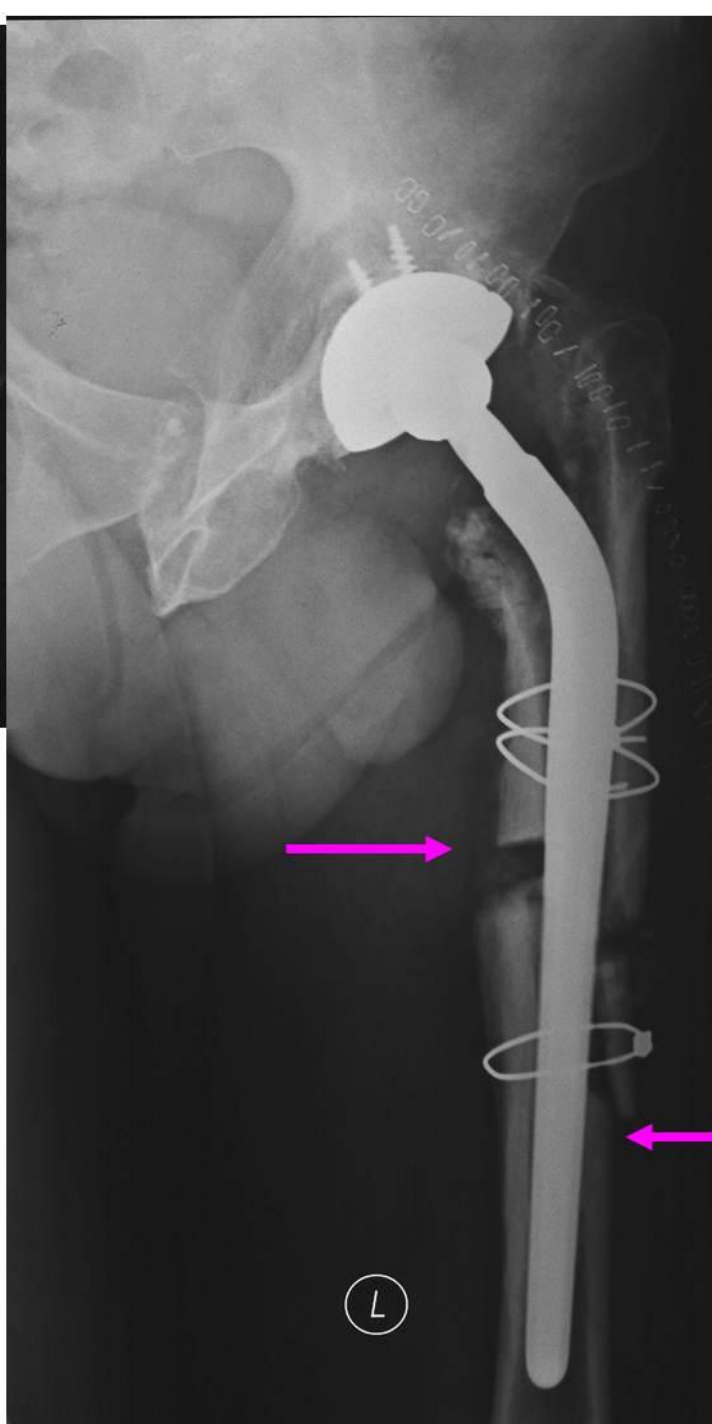
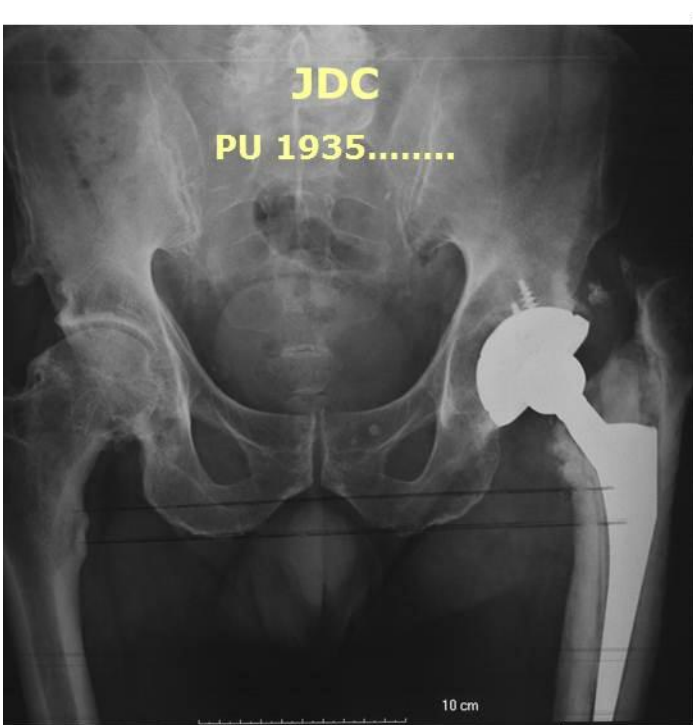
to improve exposure for an acetabular

revision, increase femoral offset or femoral

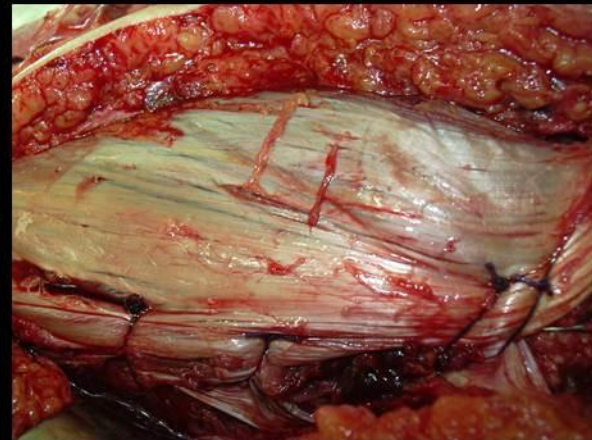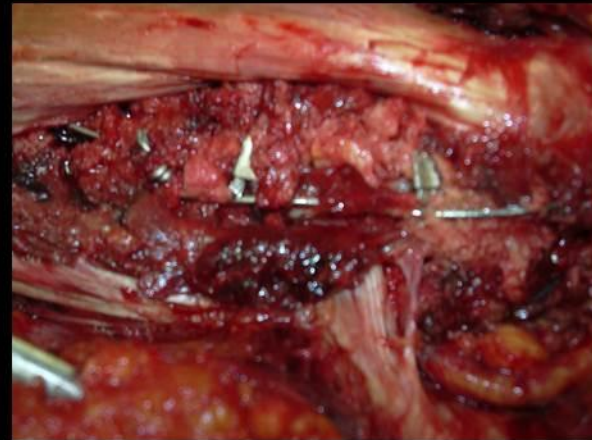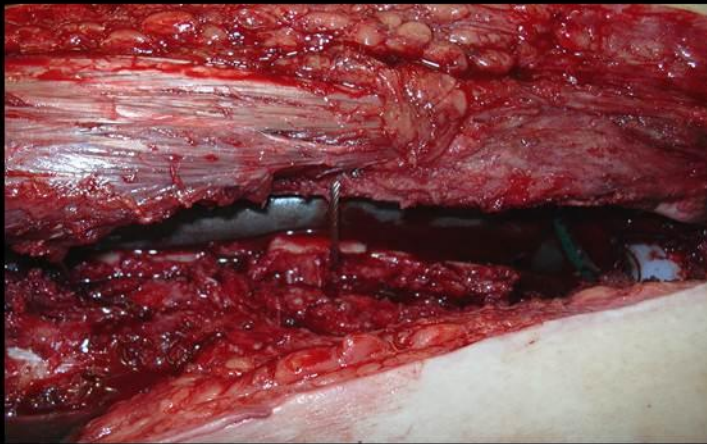
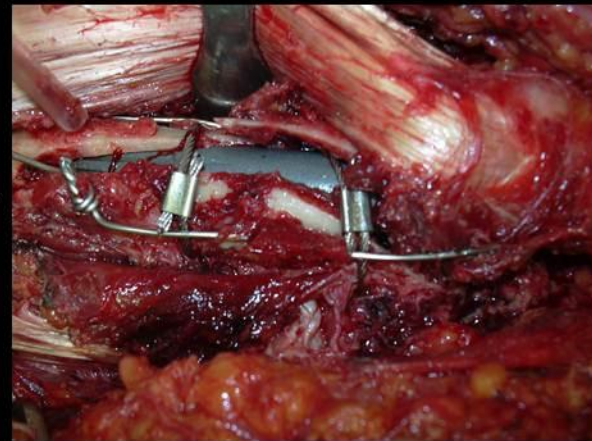
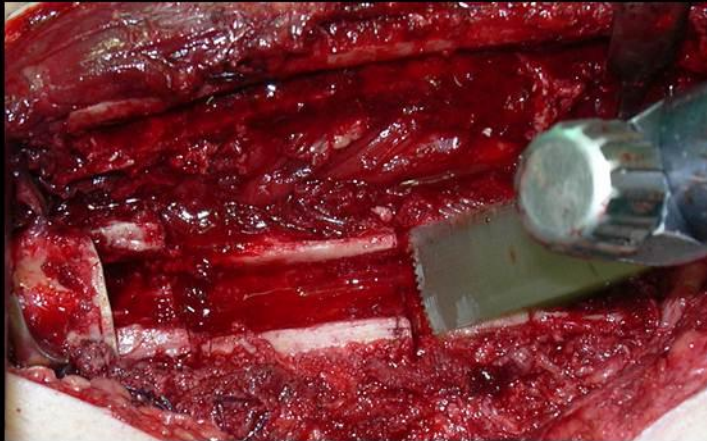
head diameter, or place a new bearing

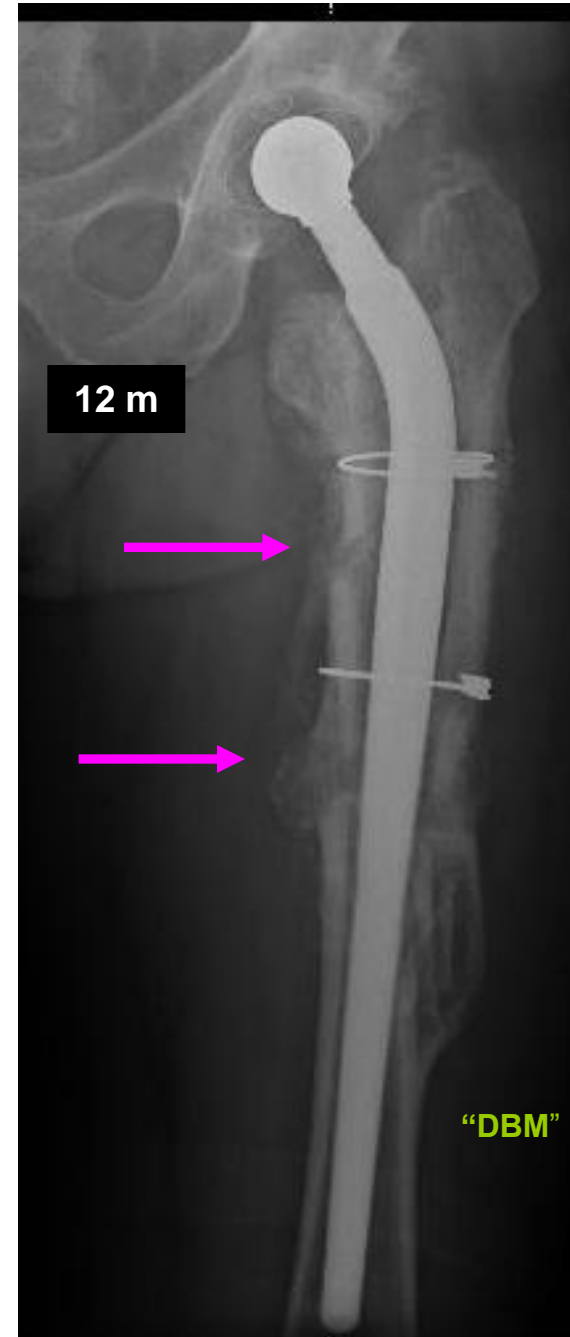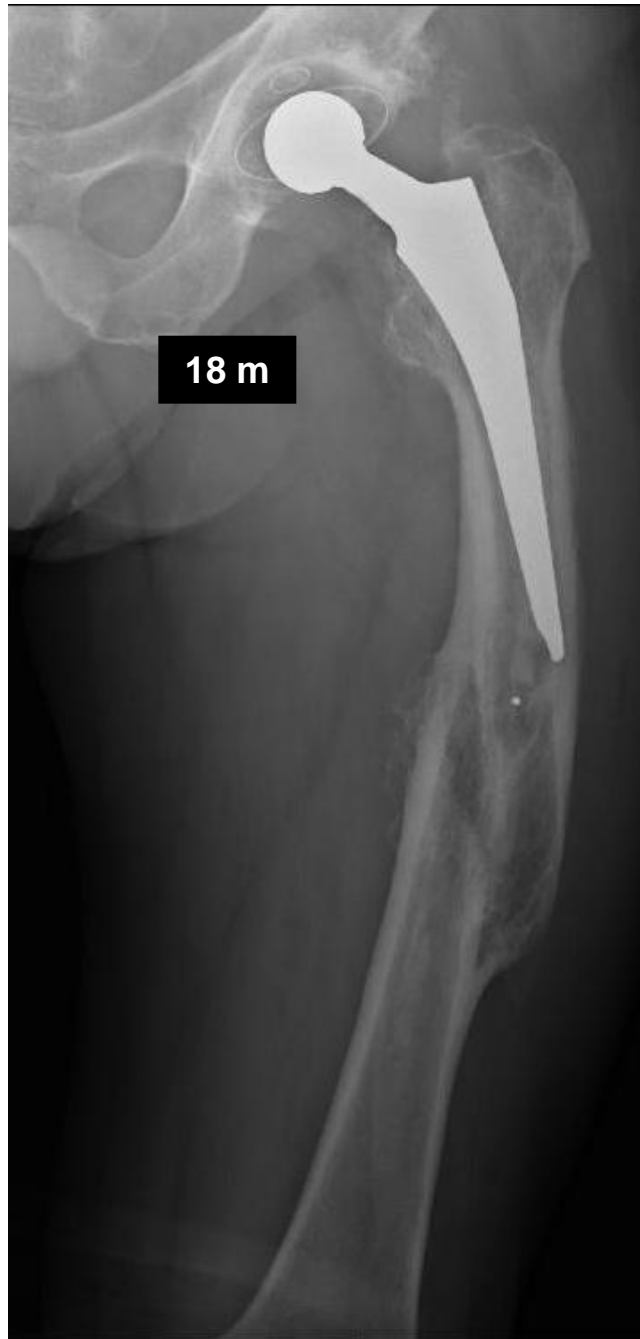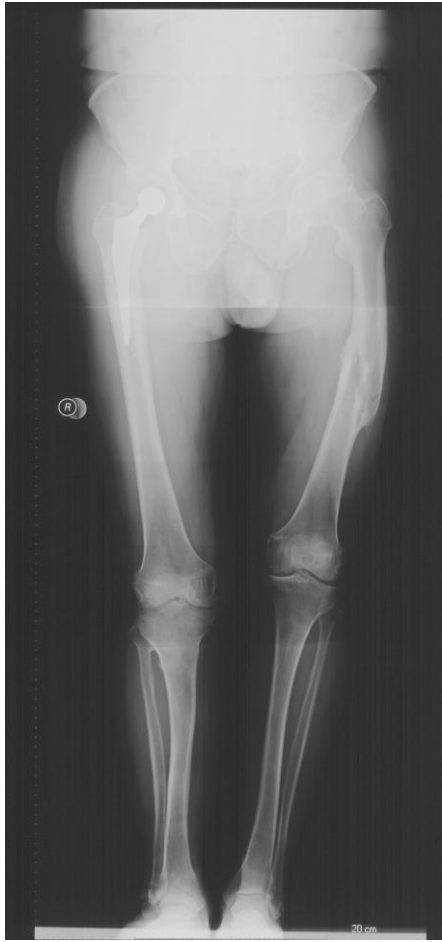femoral head

removing a debonded femoral component.

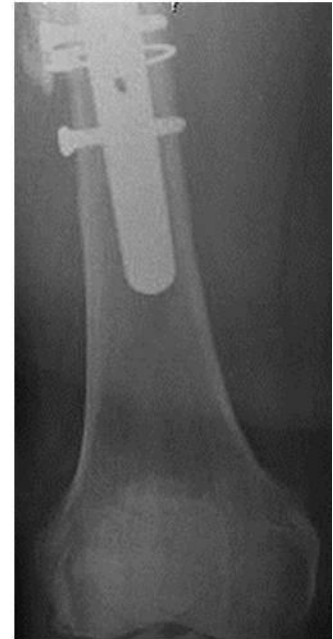
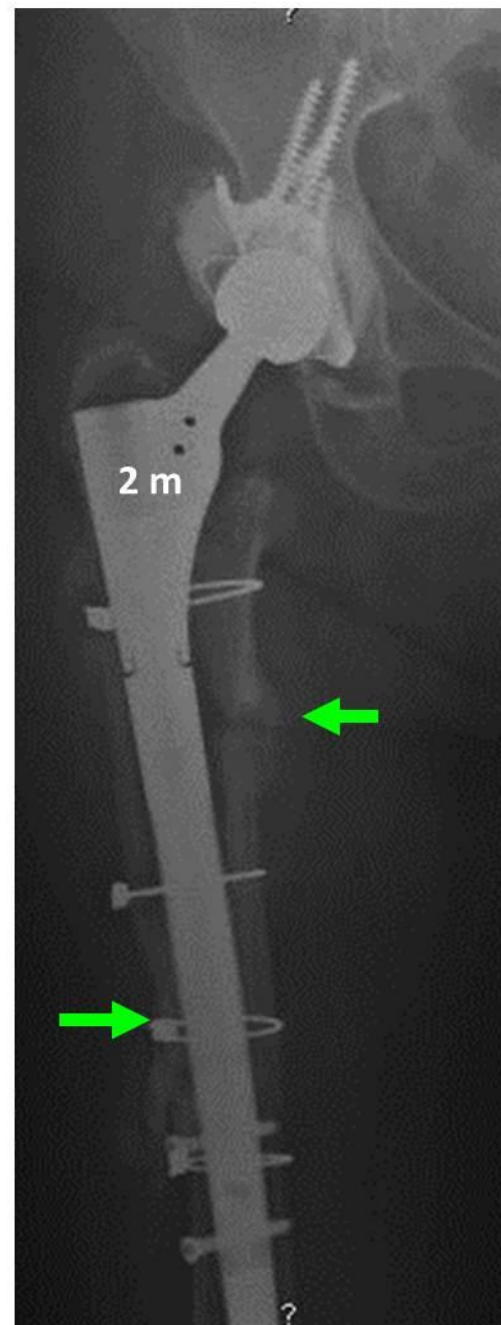
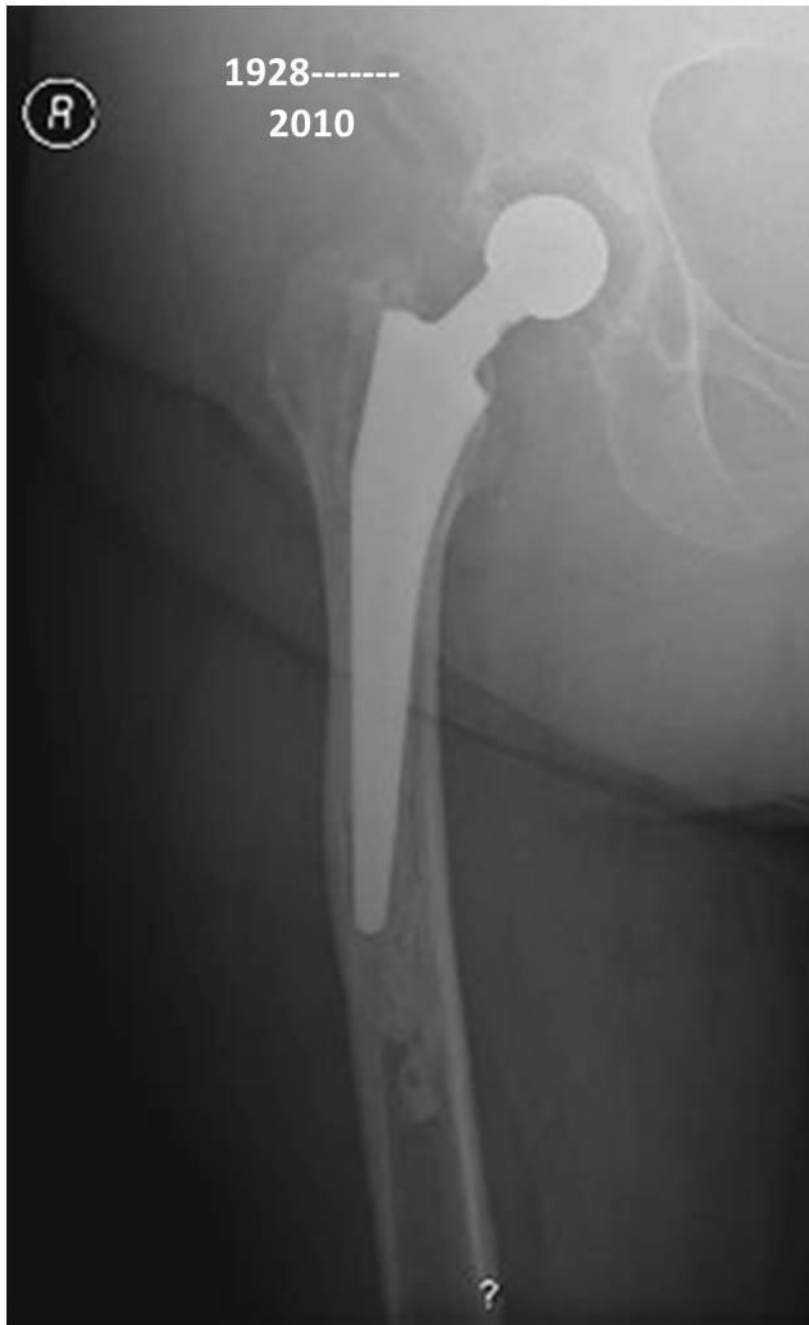

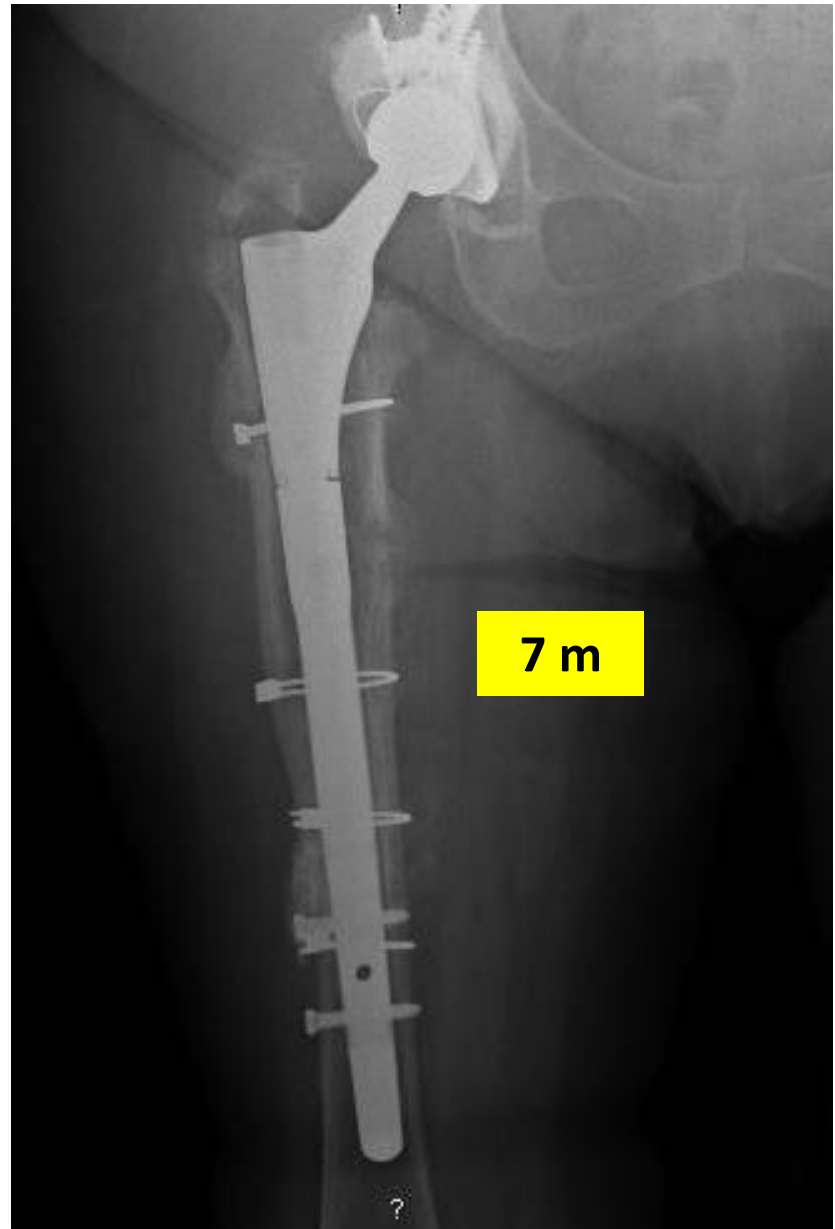
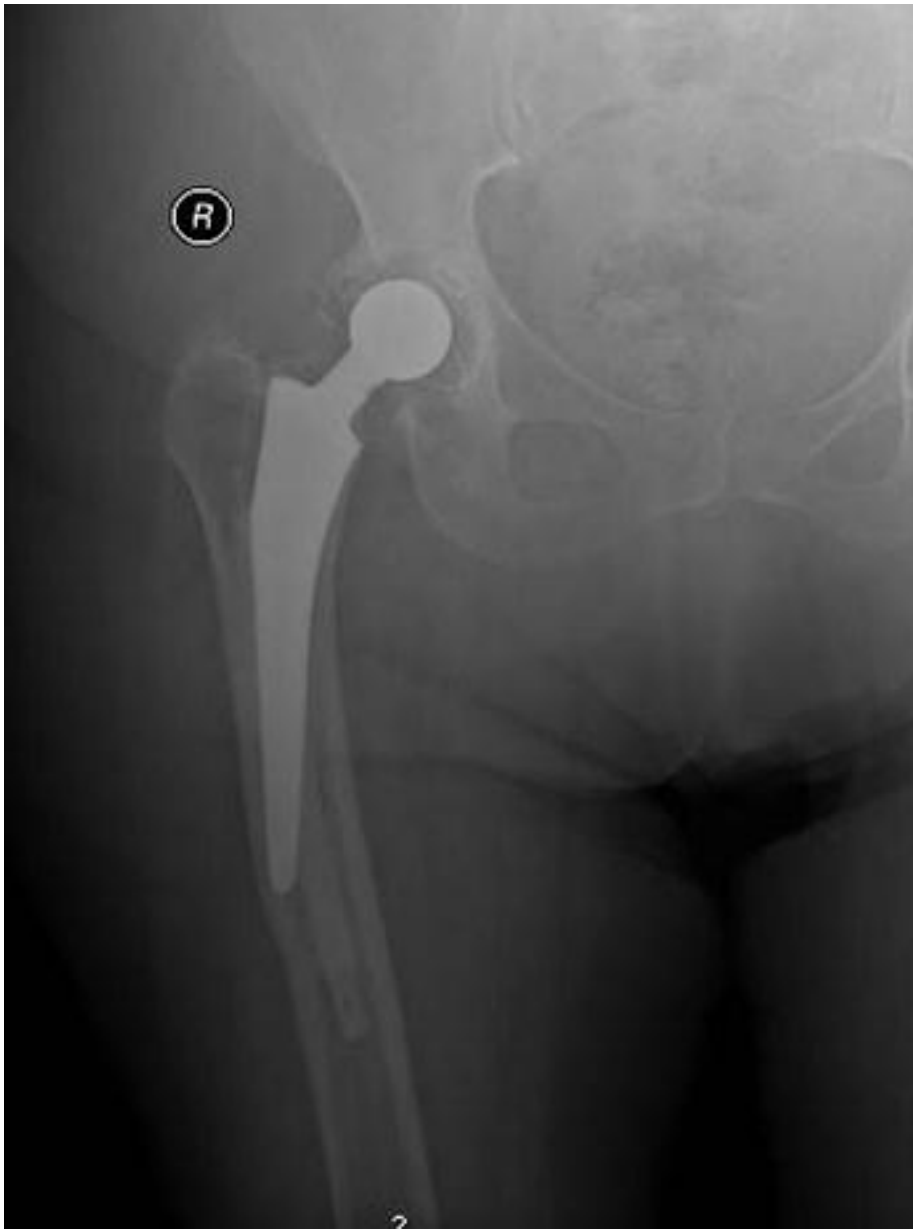Transfemoral approach

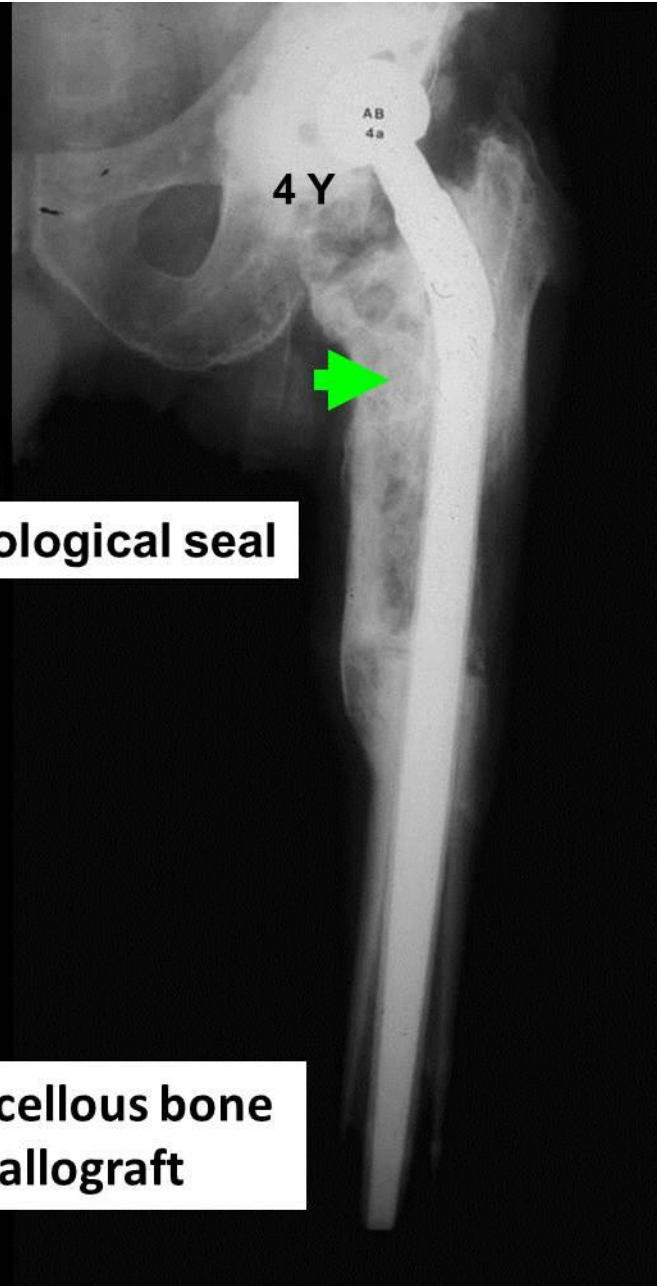
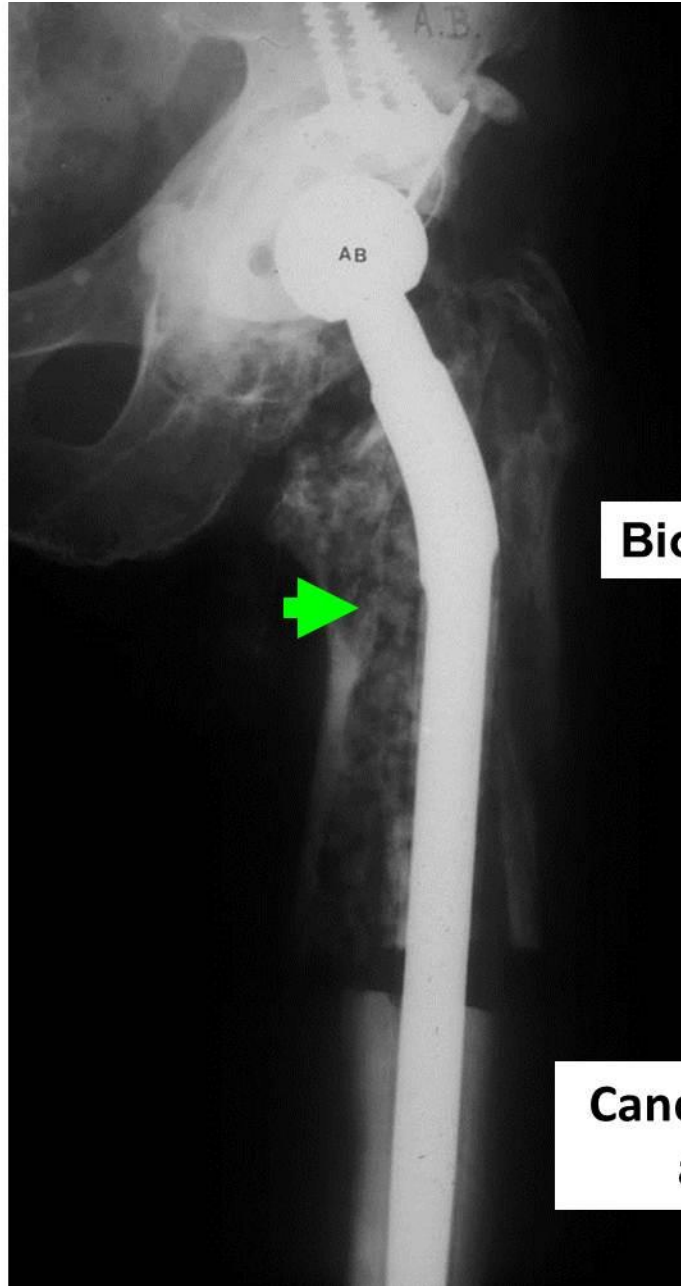
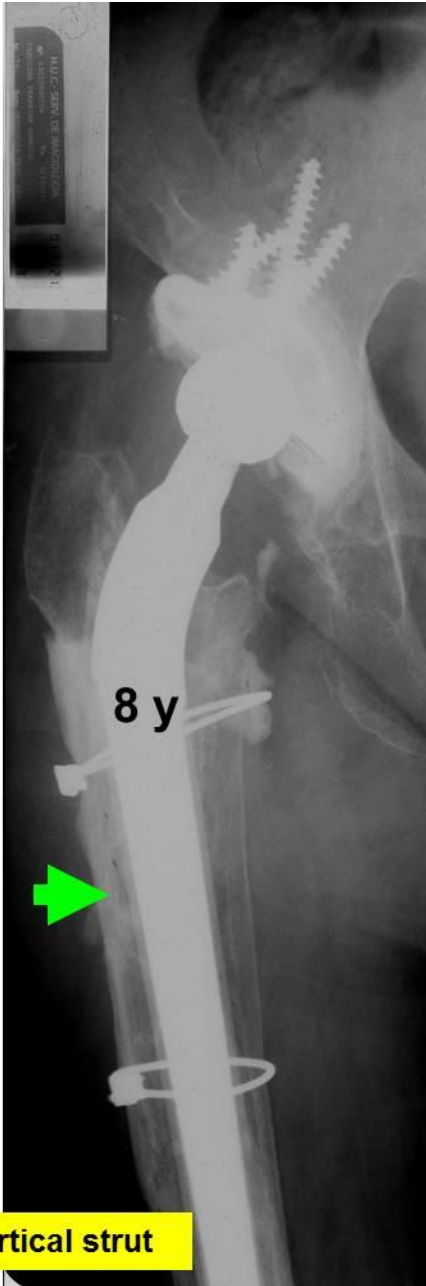




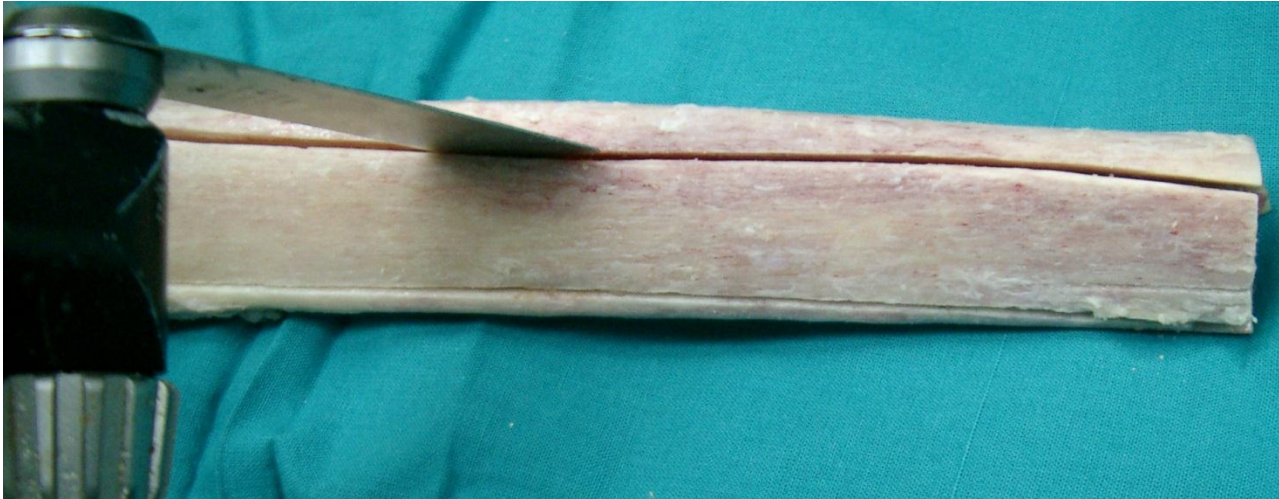
Transfemoral approach



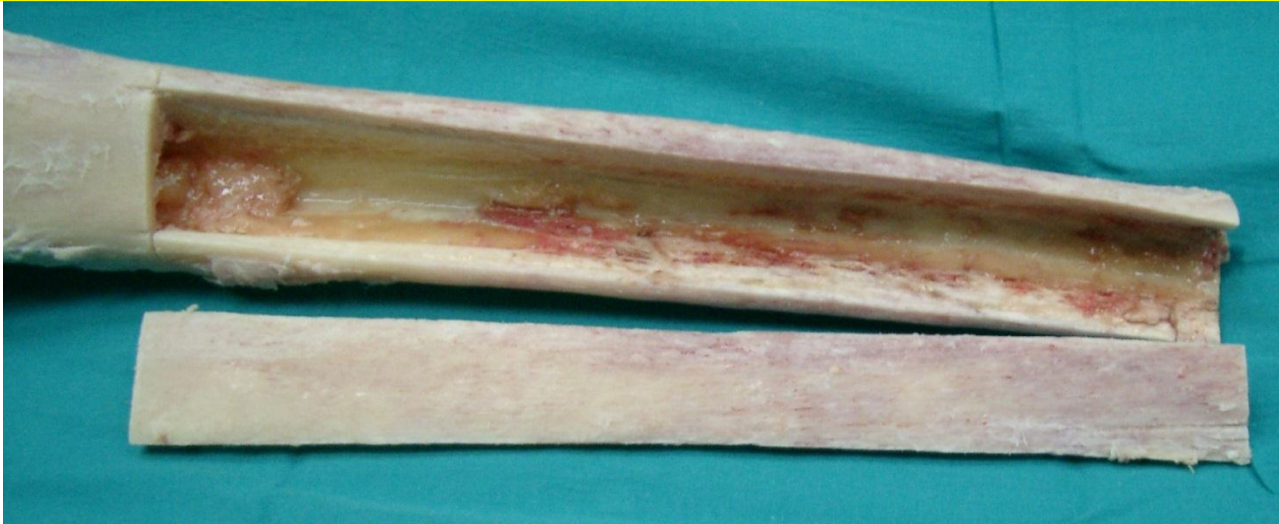


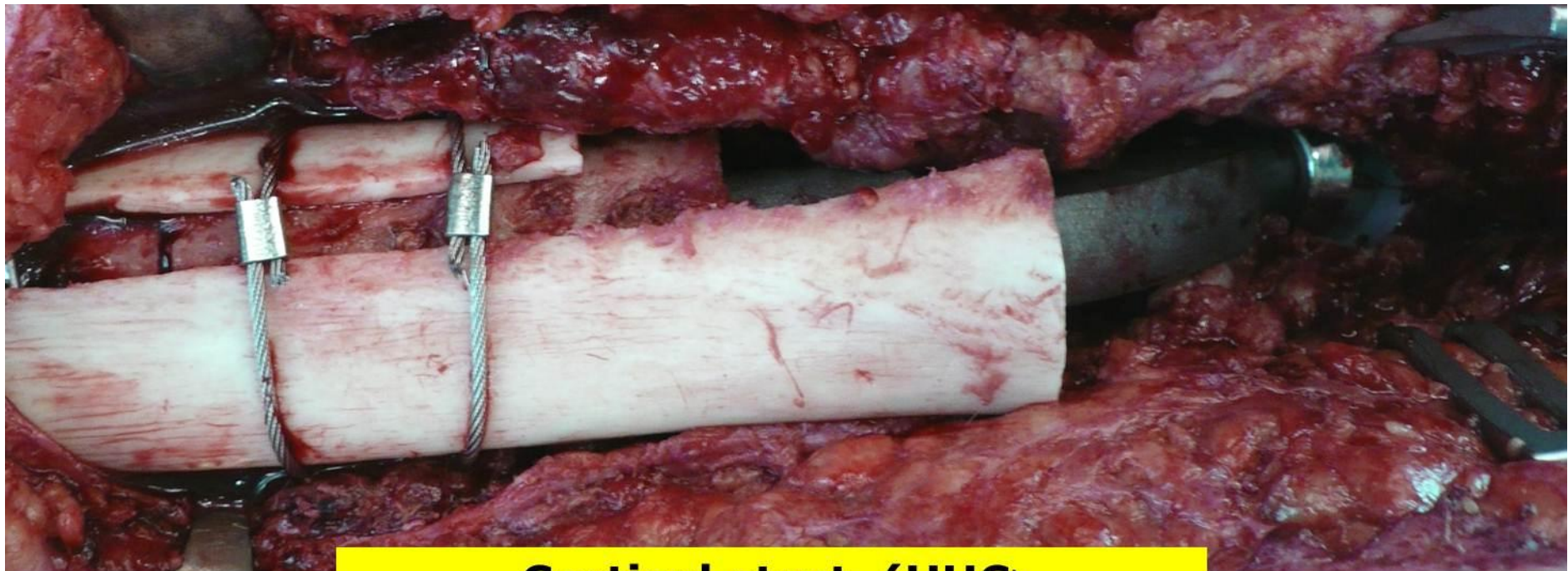
Cortical strut (biological plate)

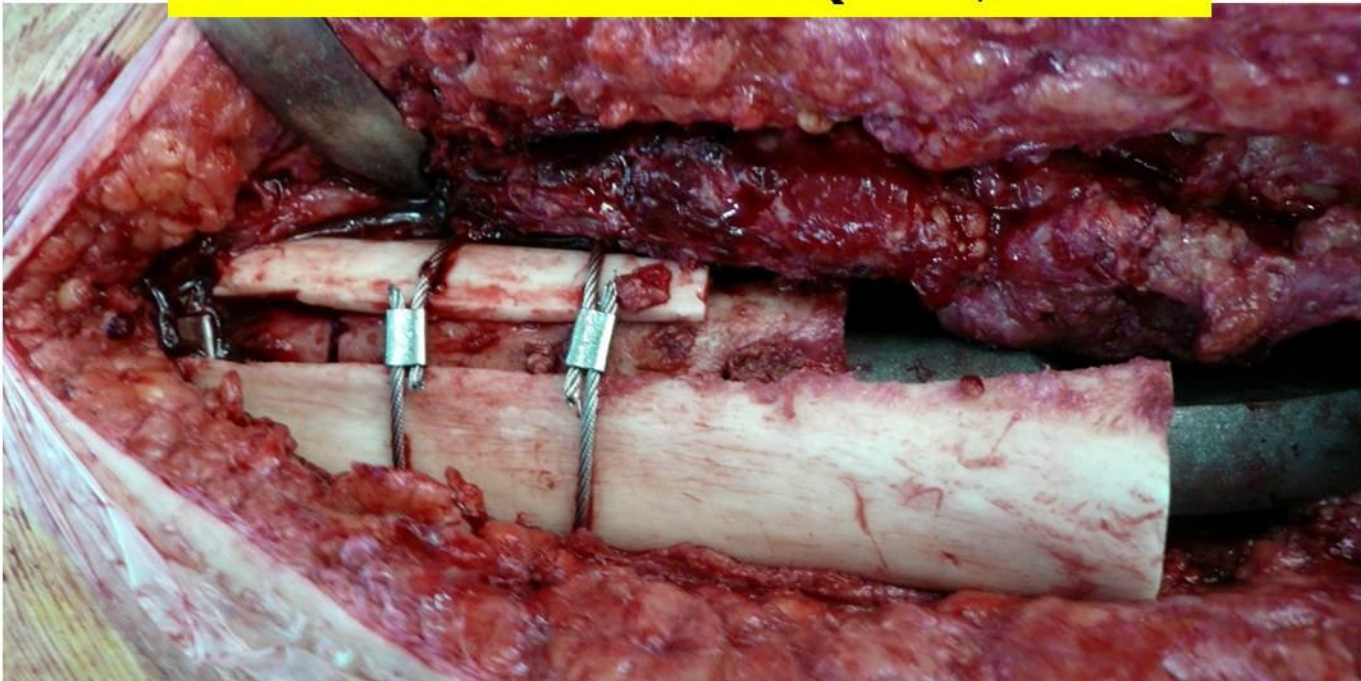


Coimbra University Hospitals Tissue Bank

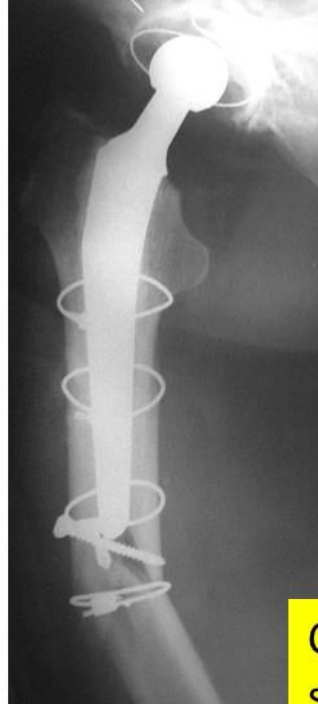
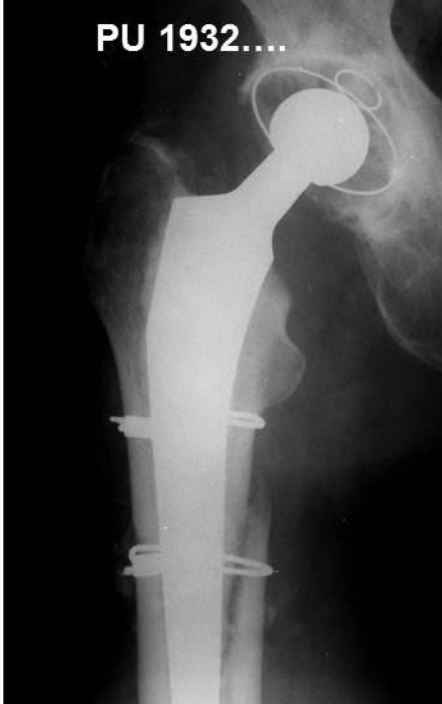


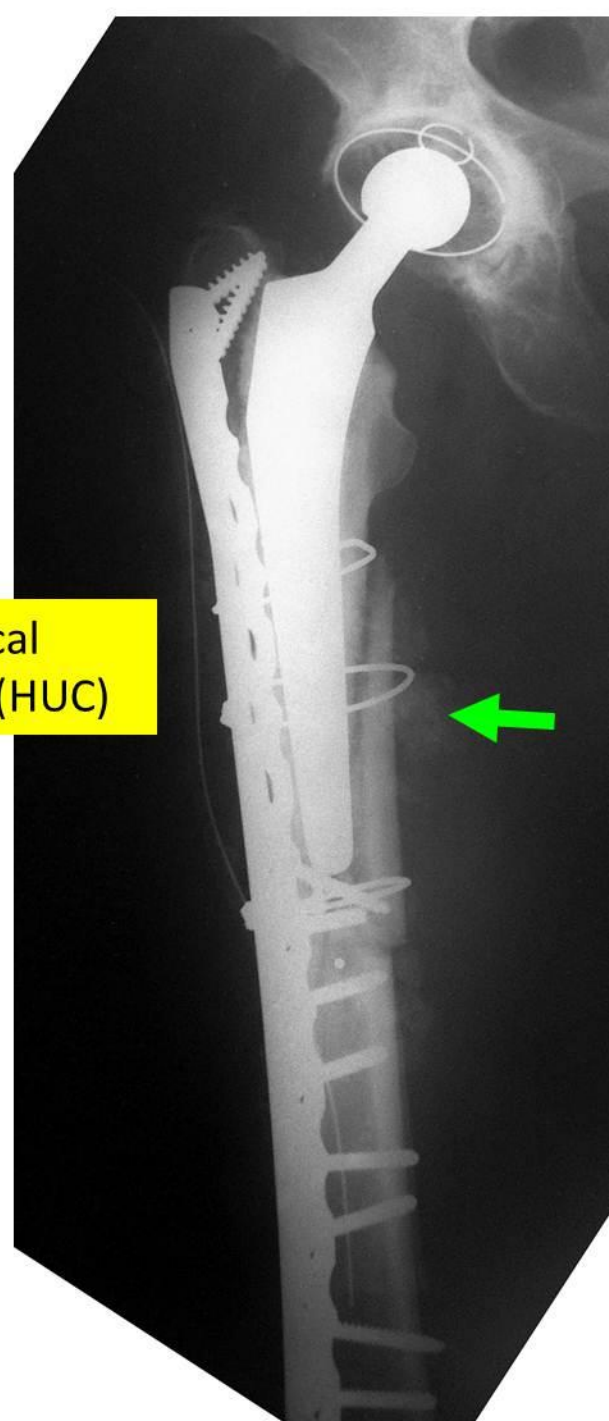Cortical strut (HUC)



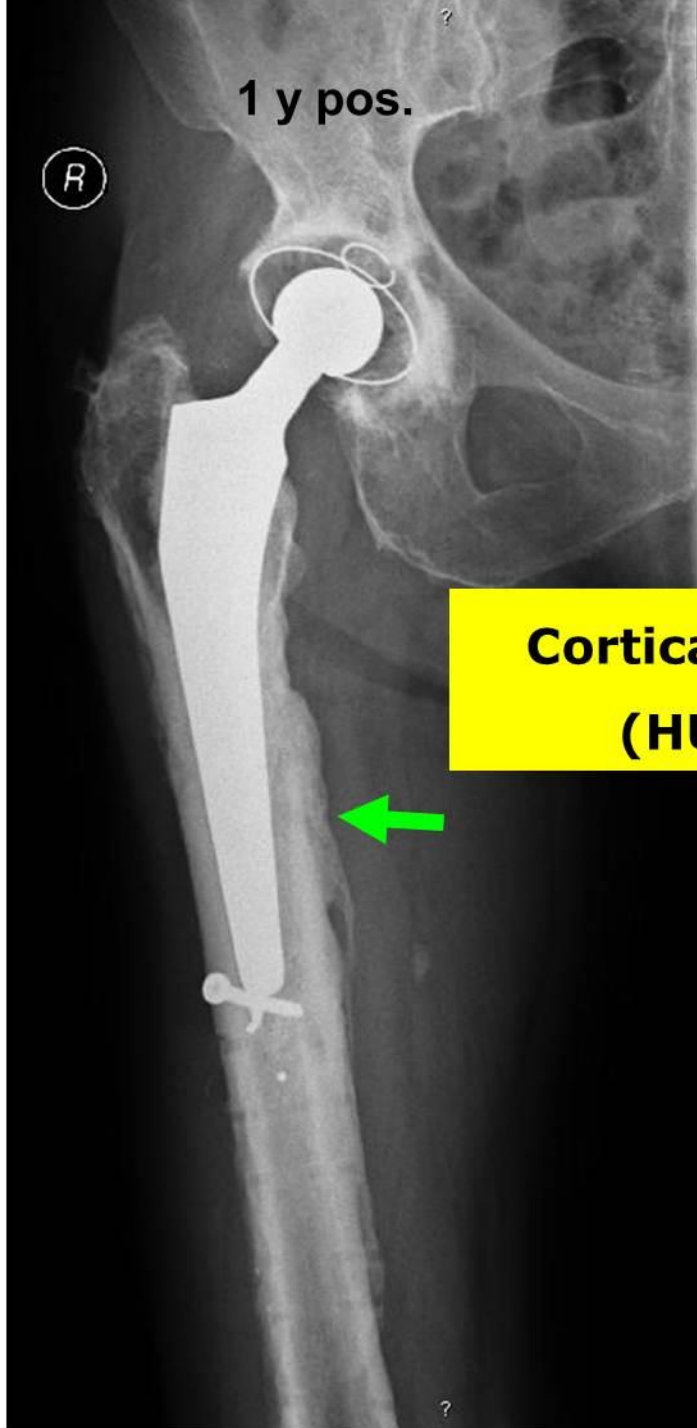PU 1932....



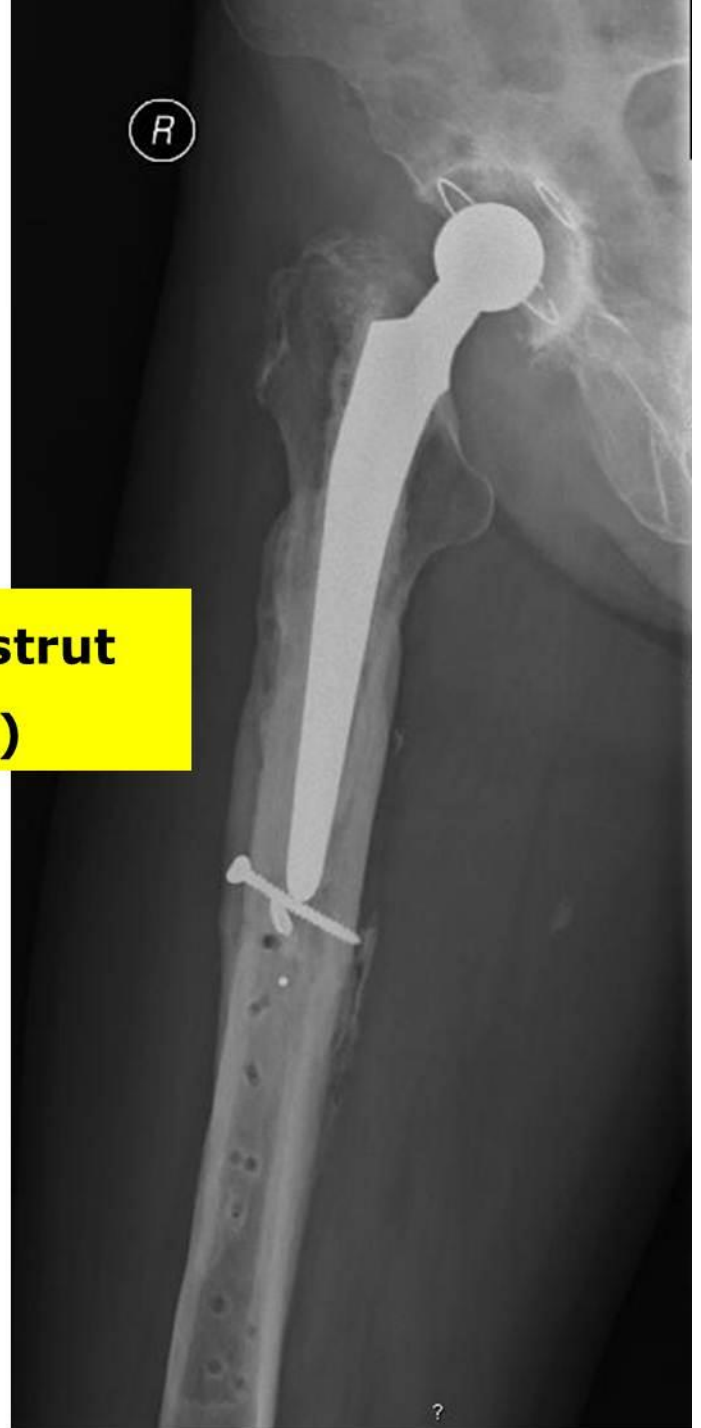Cortical
strut (HUC)



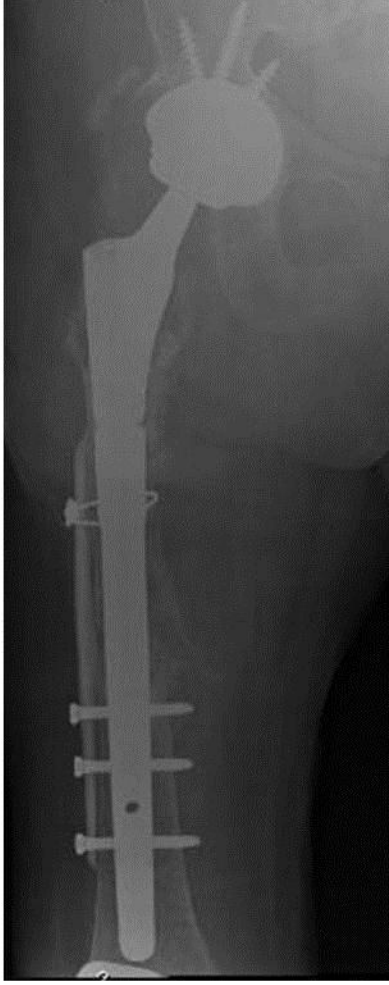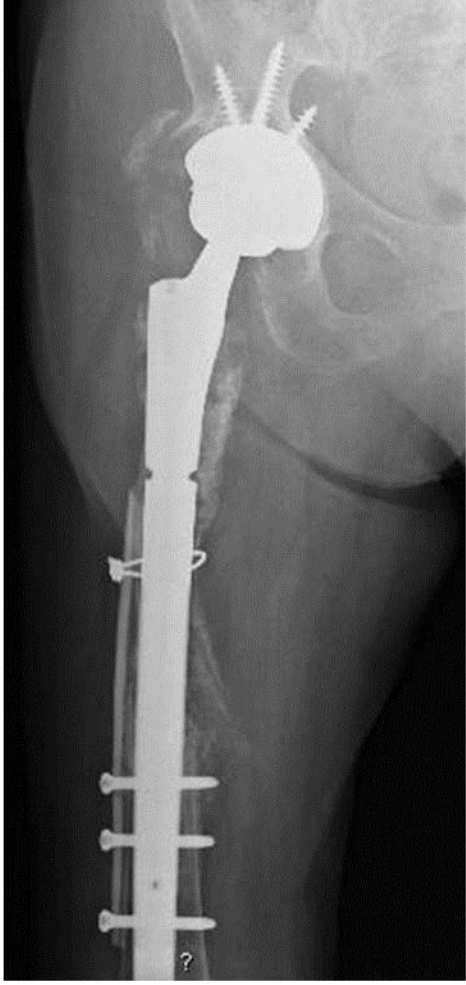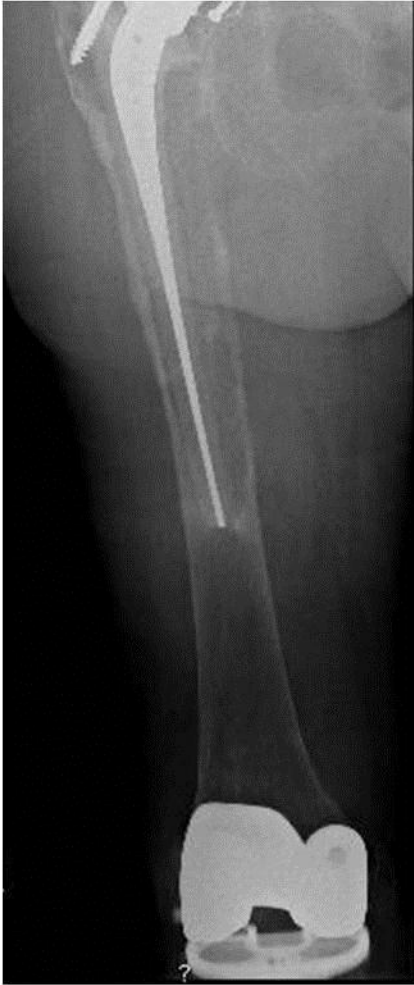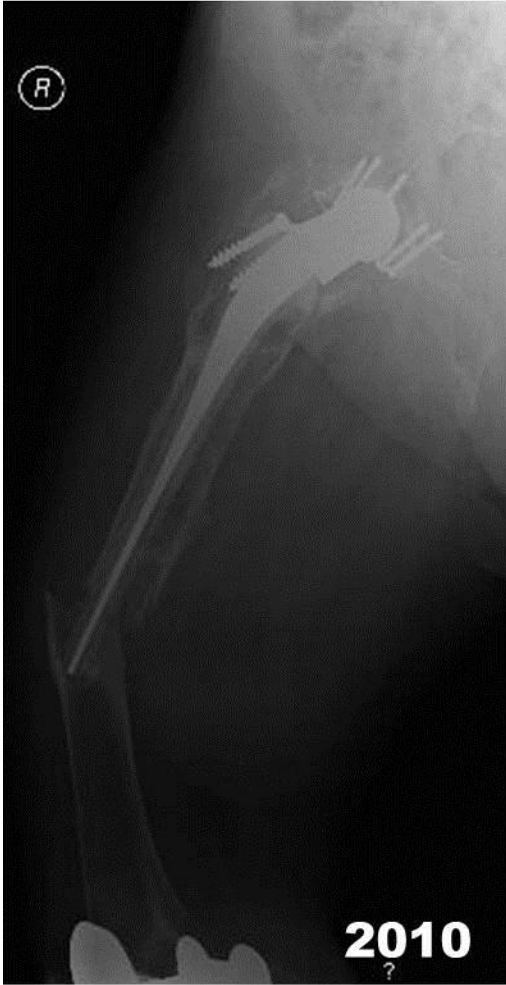2006



**Cortical strut
(HUC)**

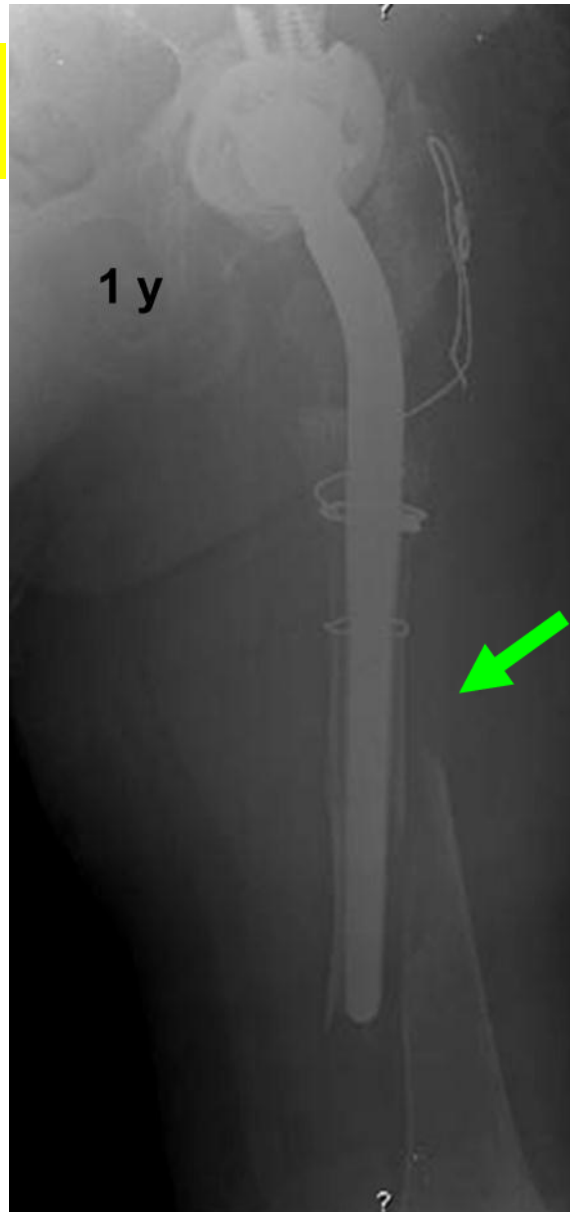


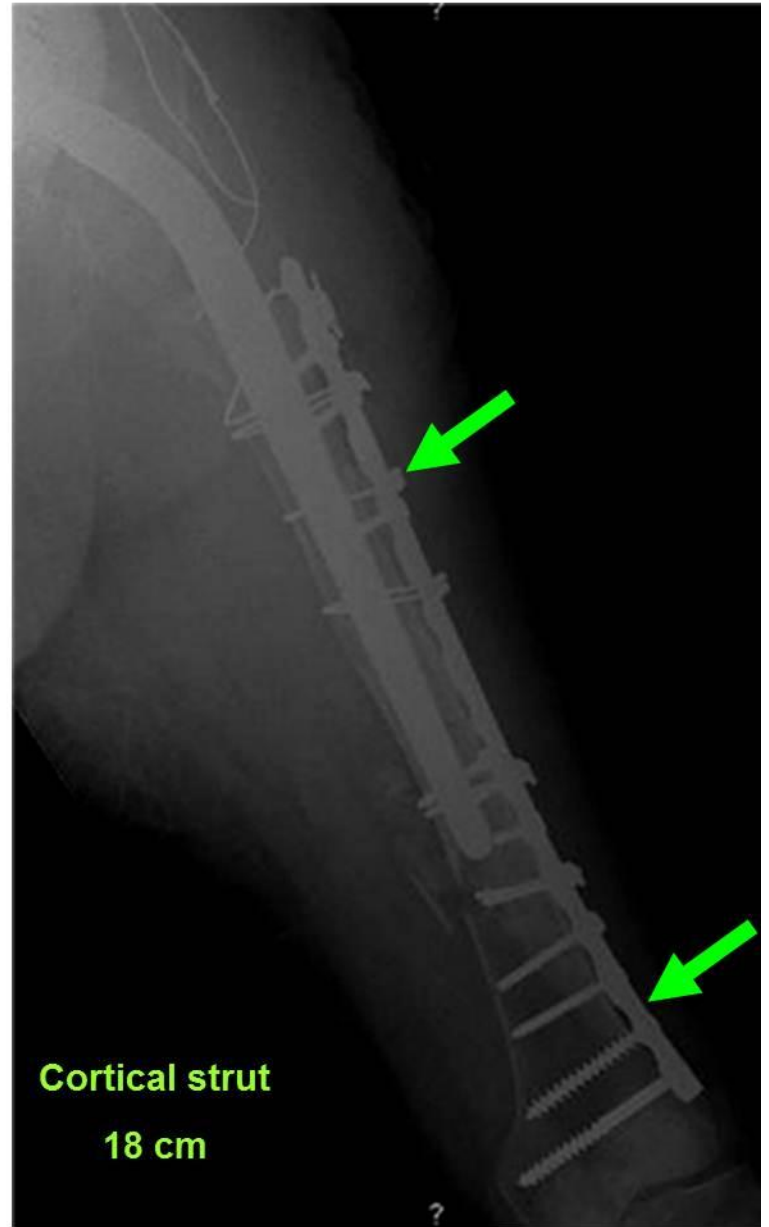
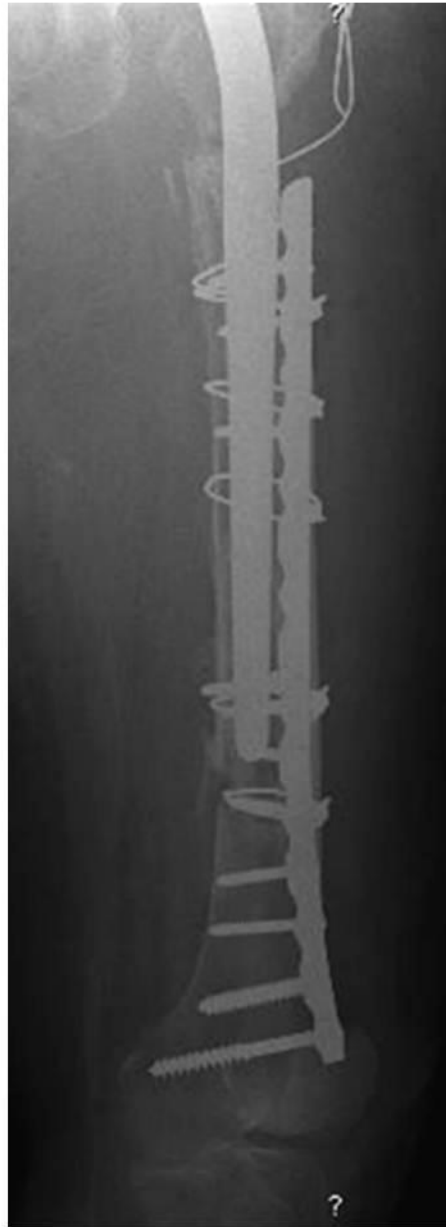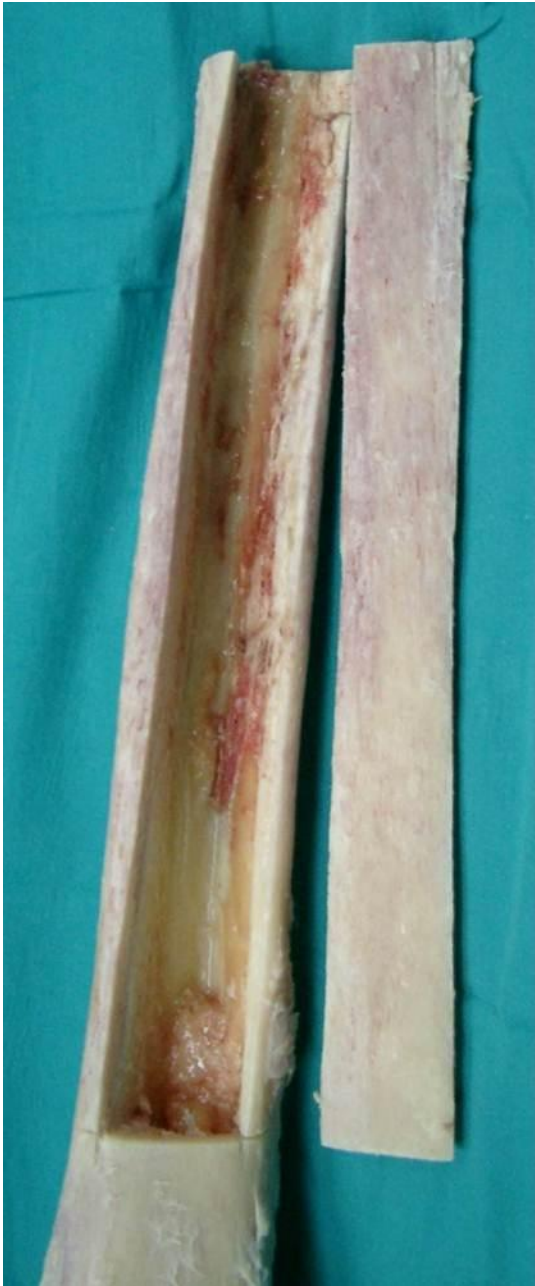Osteoporotic periprosthetic fracture of the femur in a 78 years old patient



Periprosthetic fracture

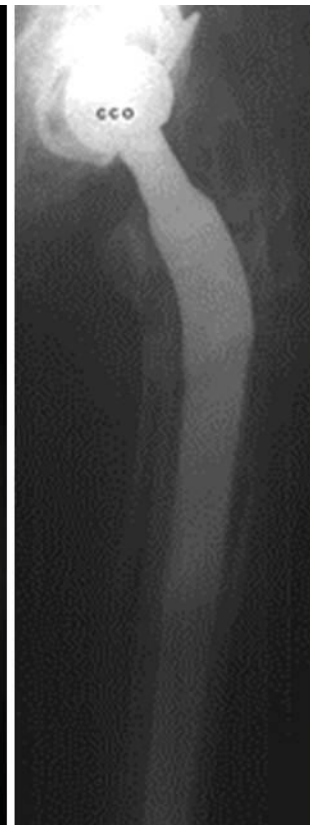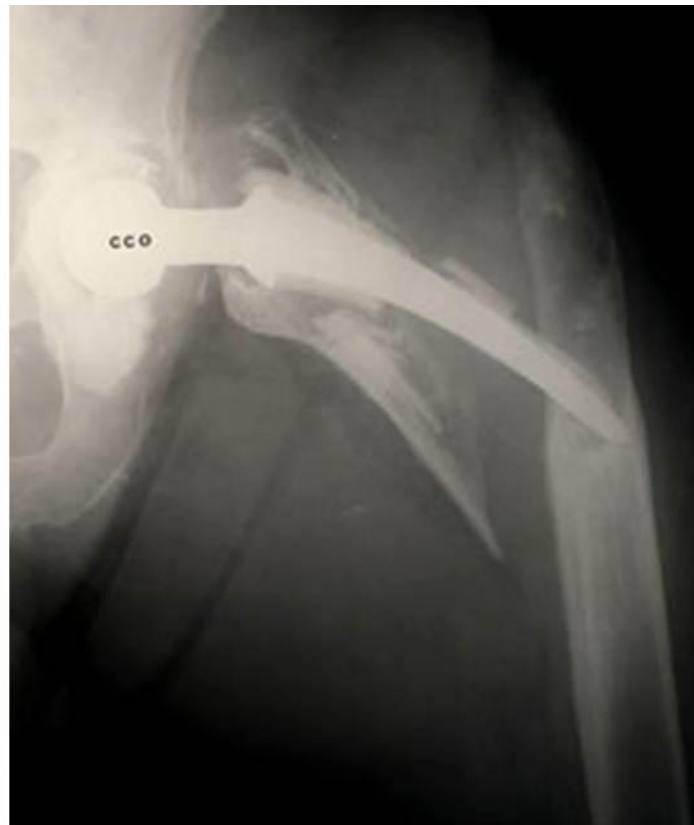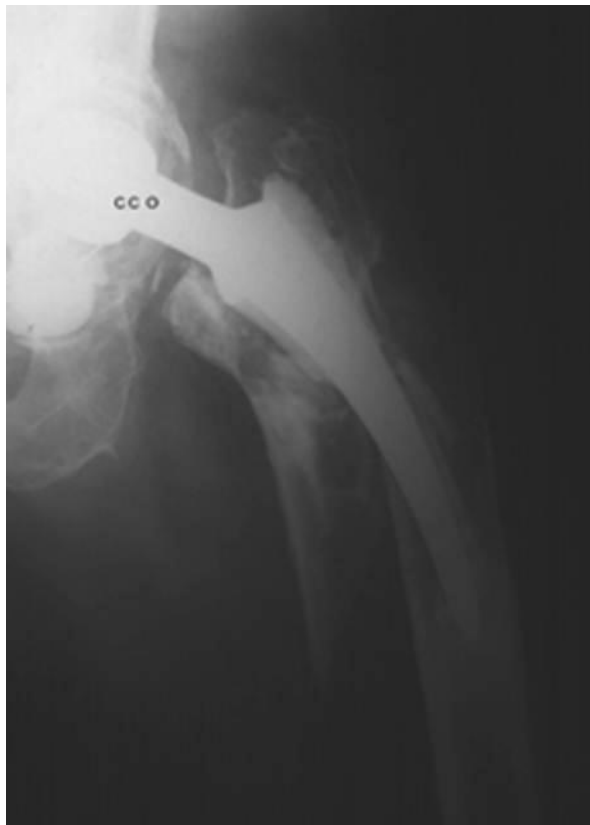70 Y
femal

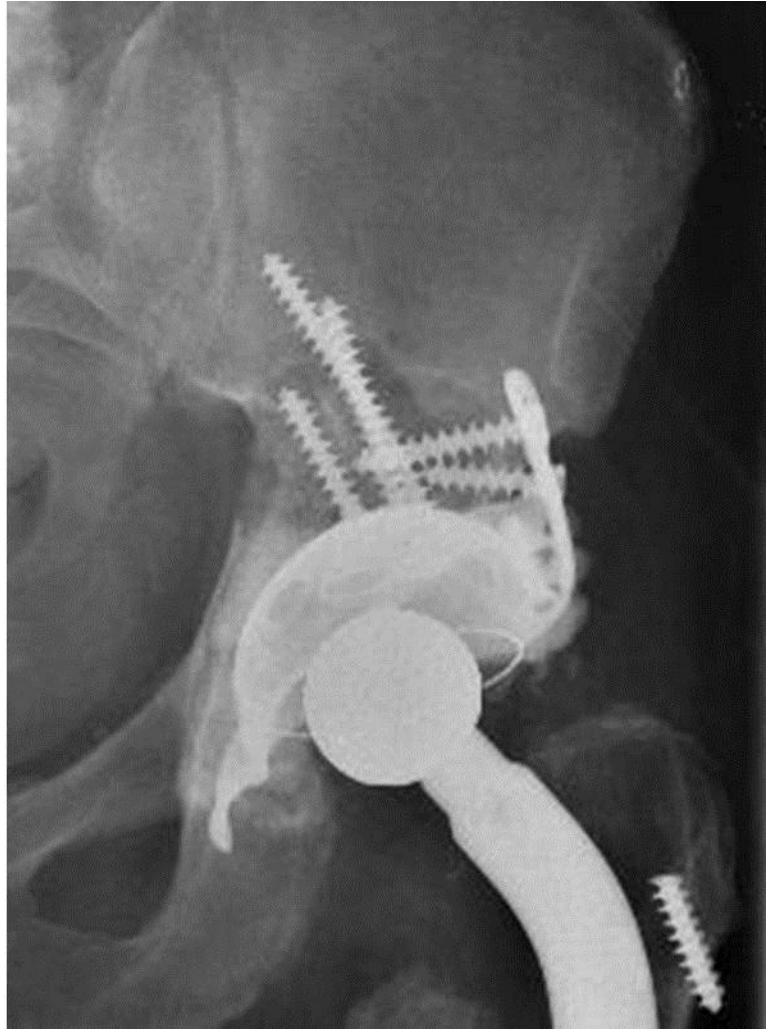
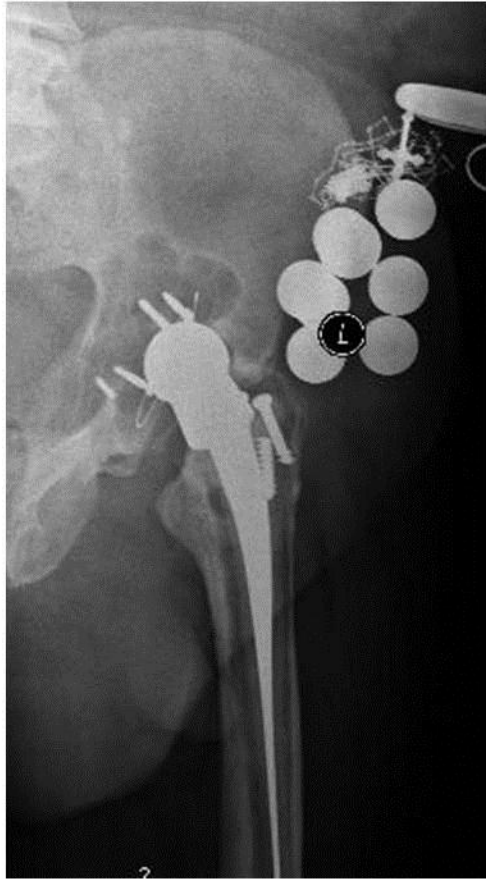
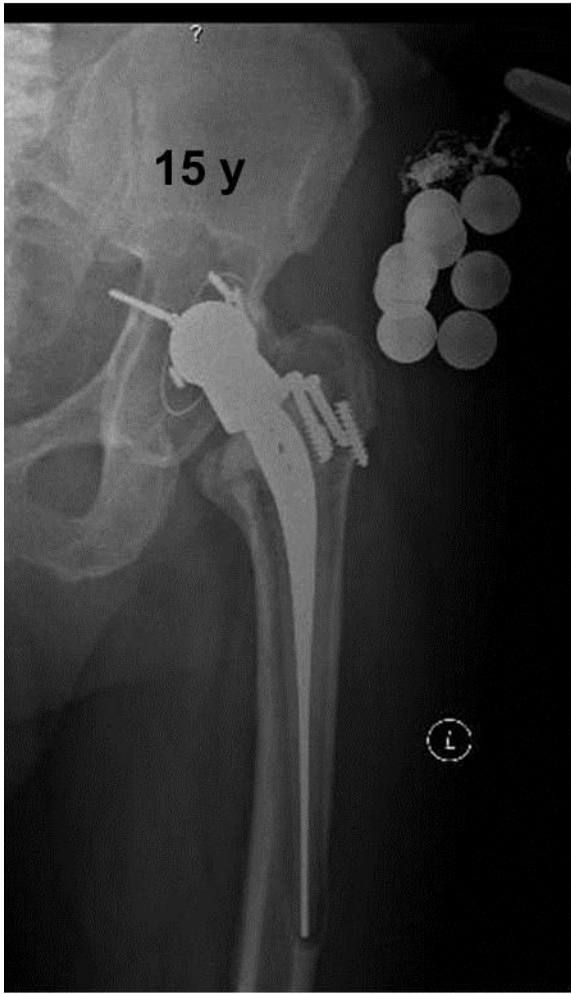

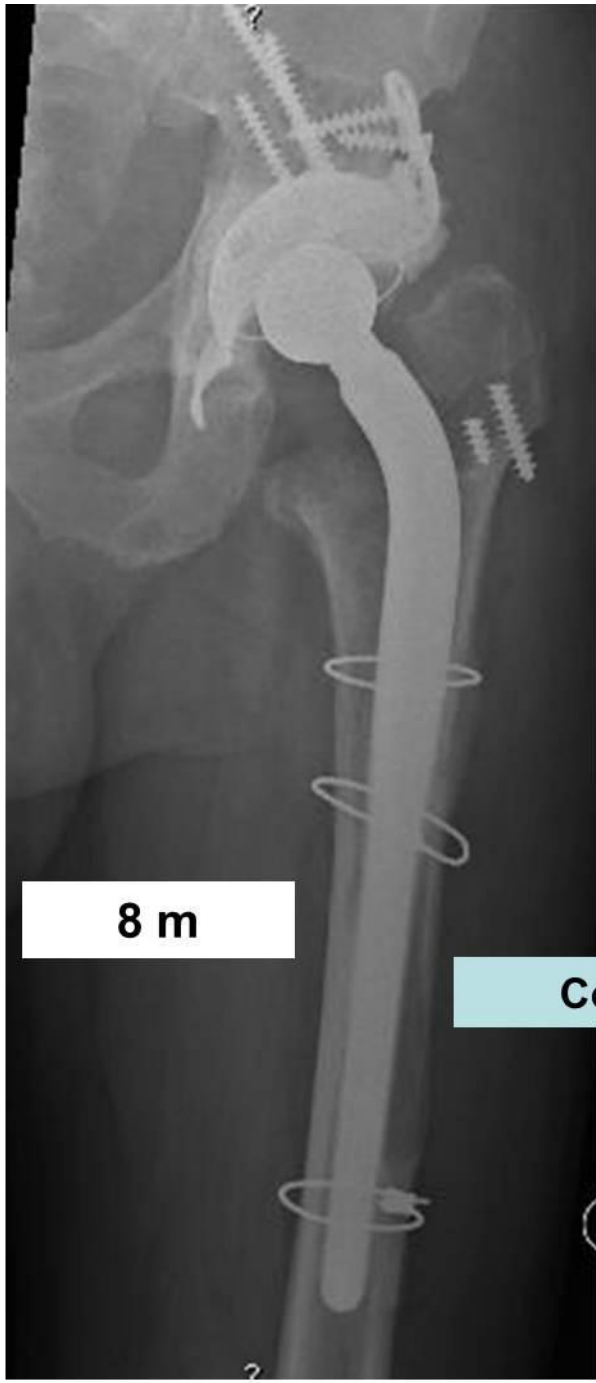

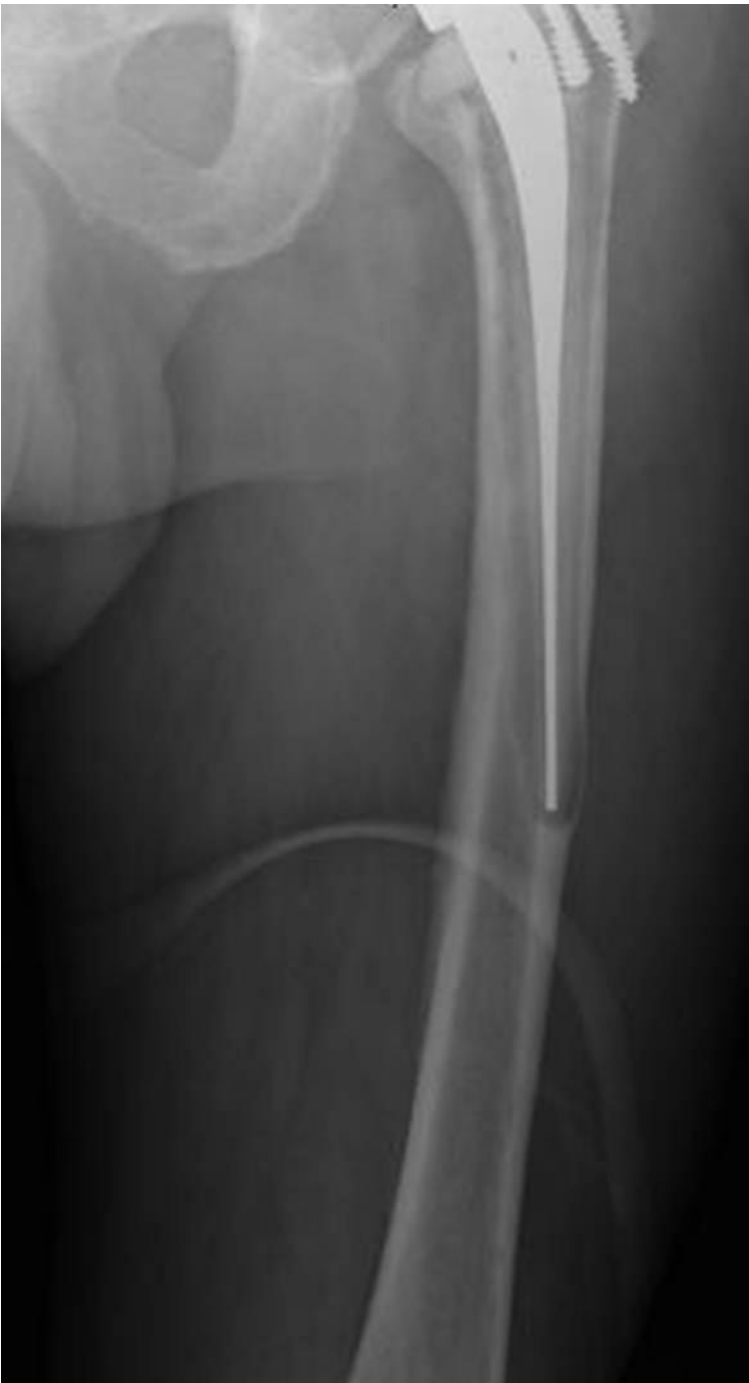
Cortical strut
18 cm

Periprosthetic fracture

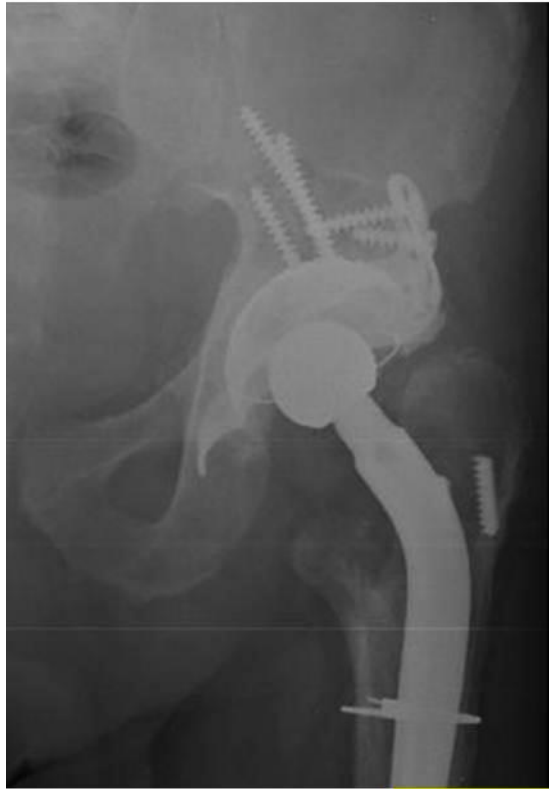




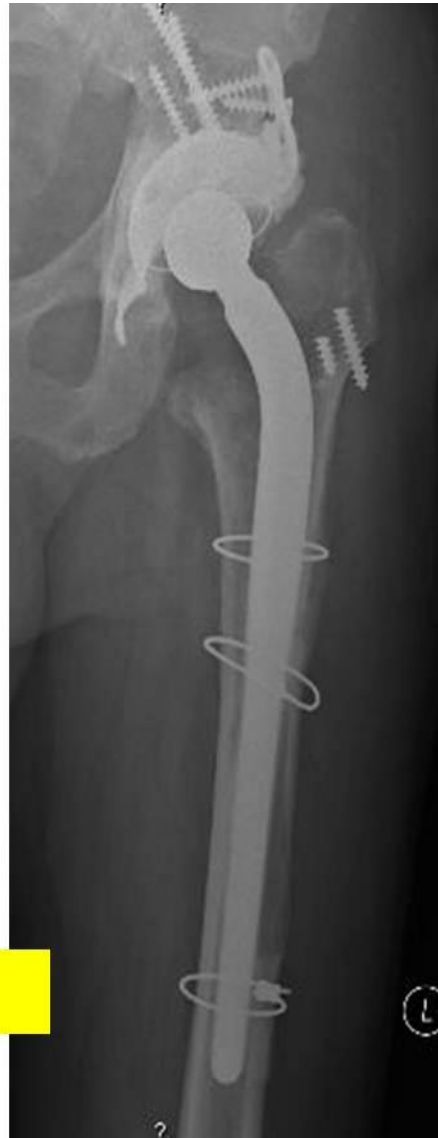
8 m

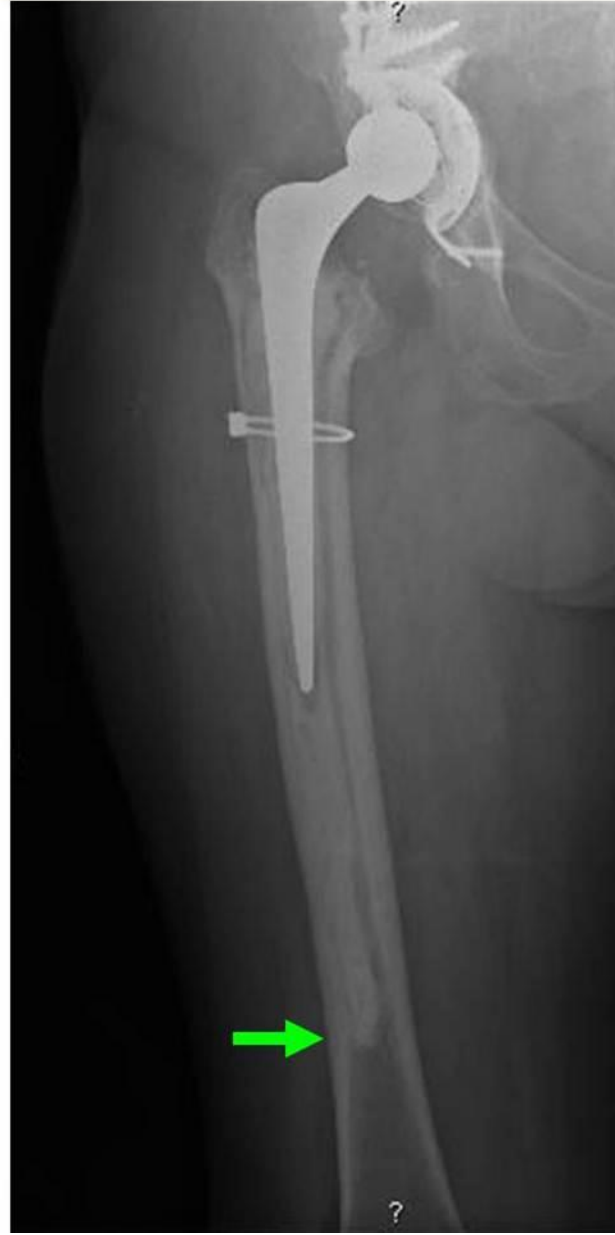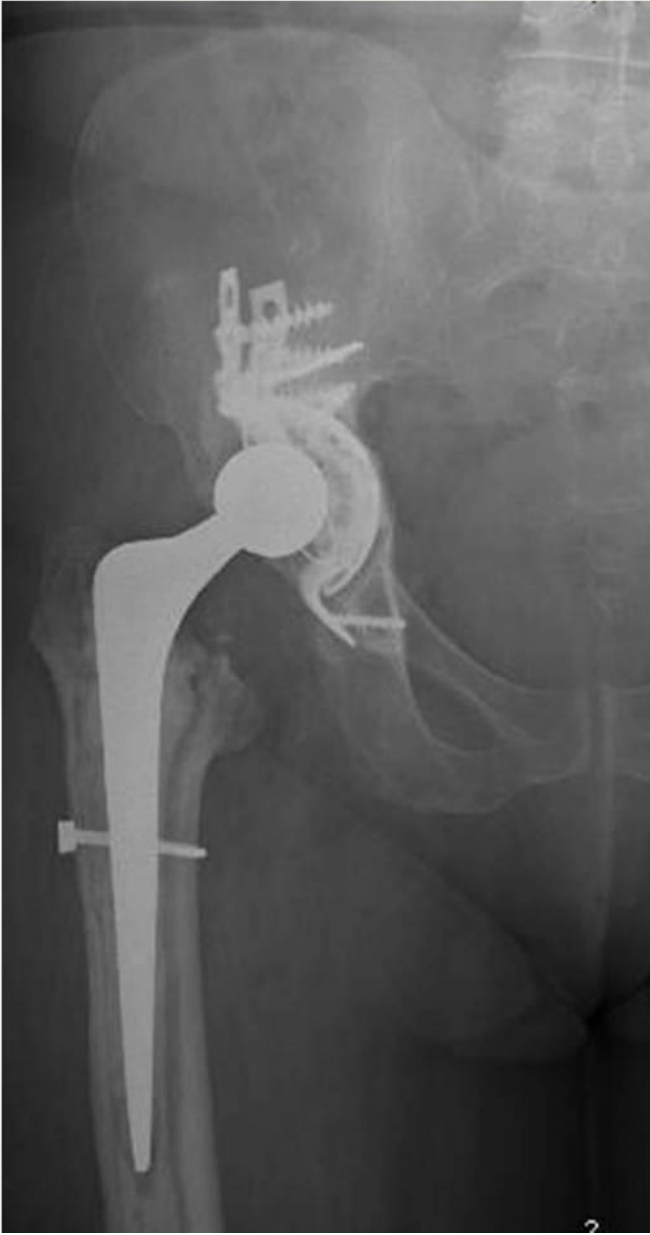Cortical strut

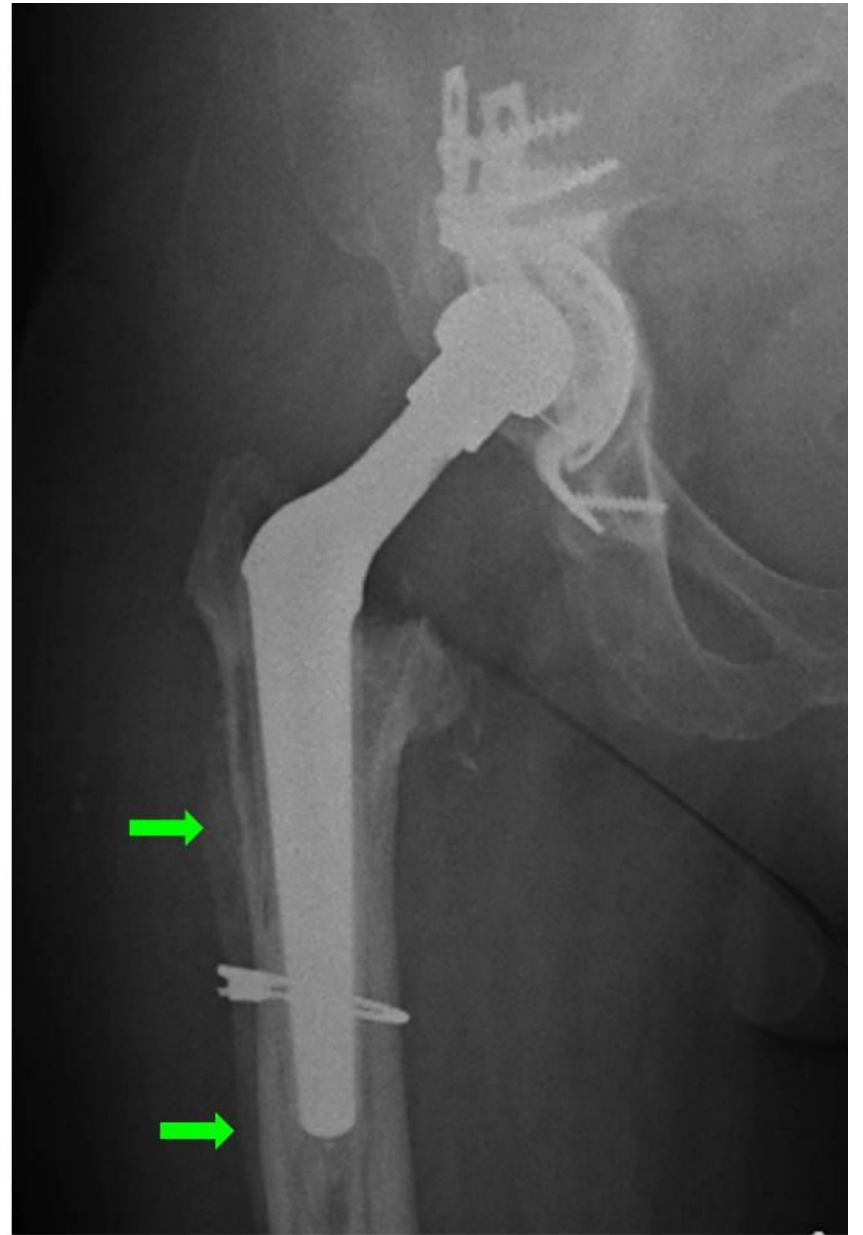
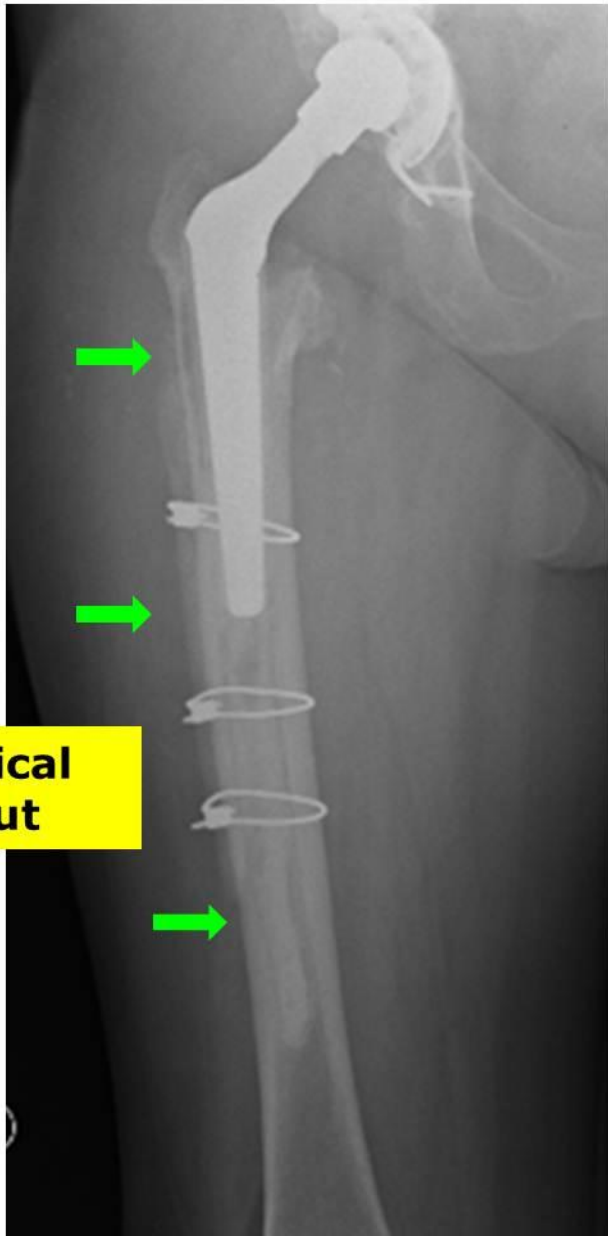
1 Y



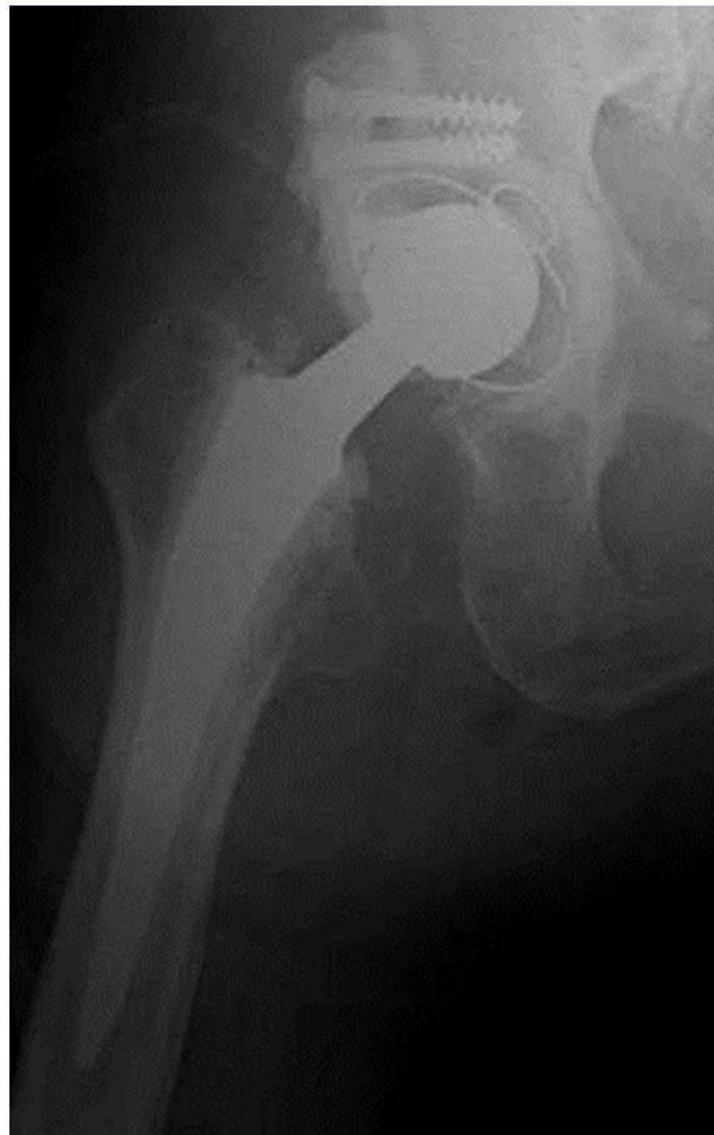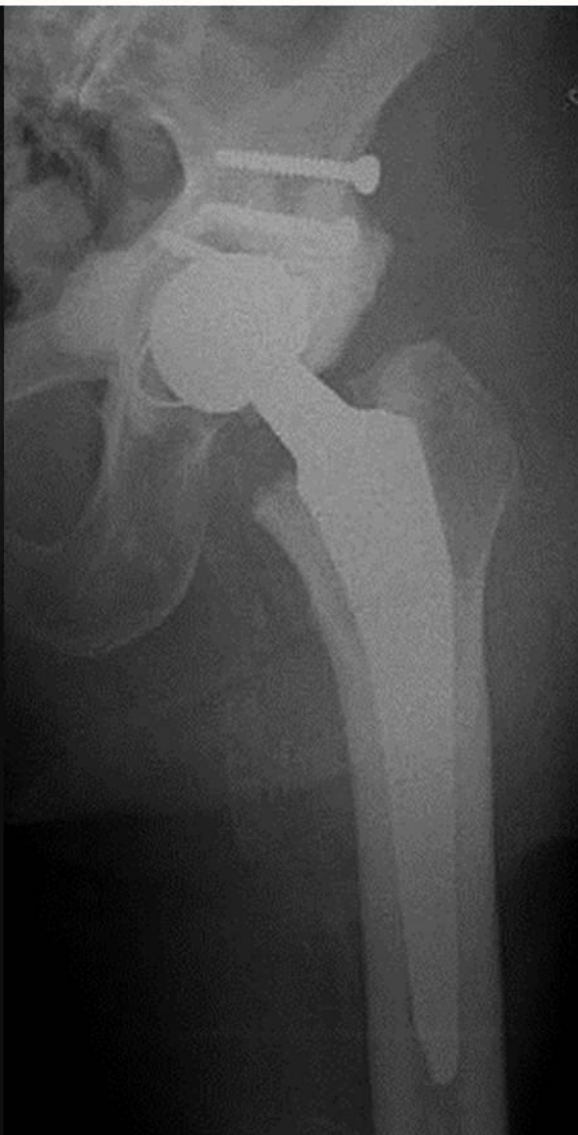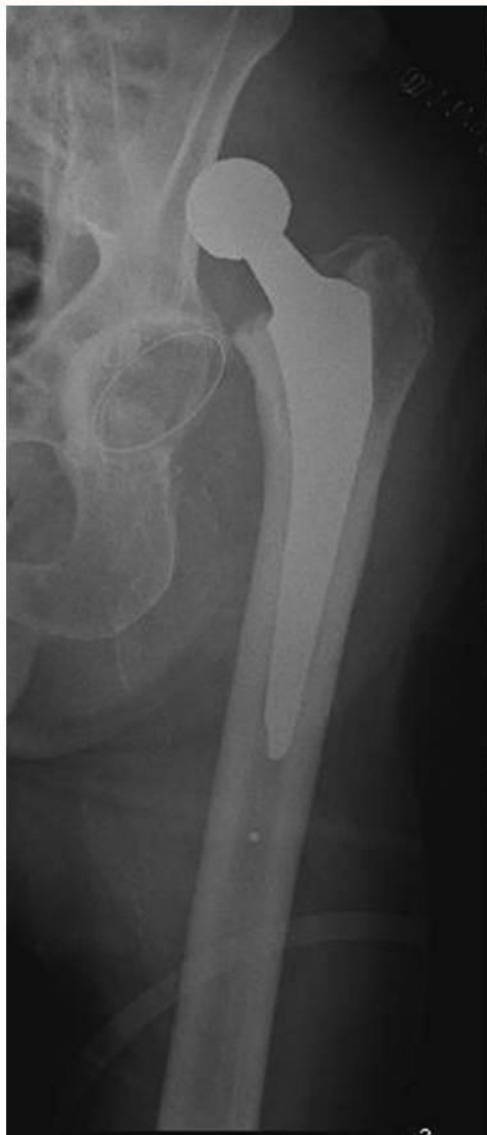**1952..femal, 15 y of follow-up, loosening of the femoral stem,
large cement mantle**



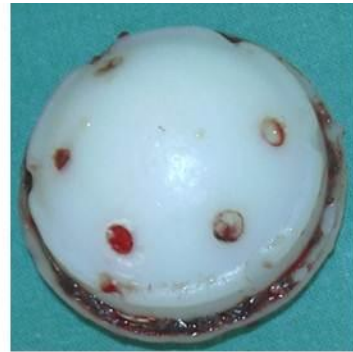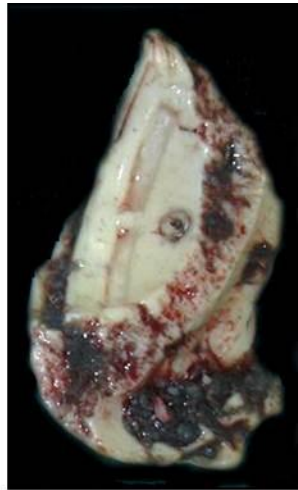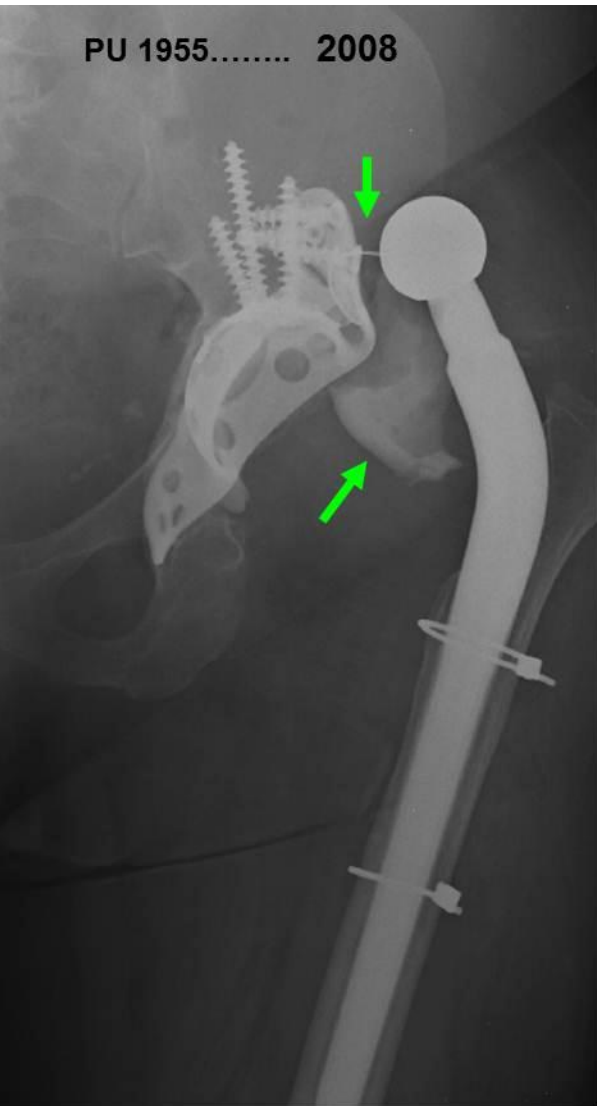


Instable arthroplasty of the hip treated with a simple technique of acetabular augmentation

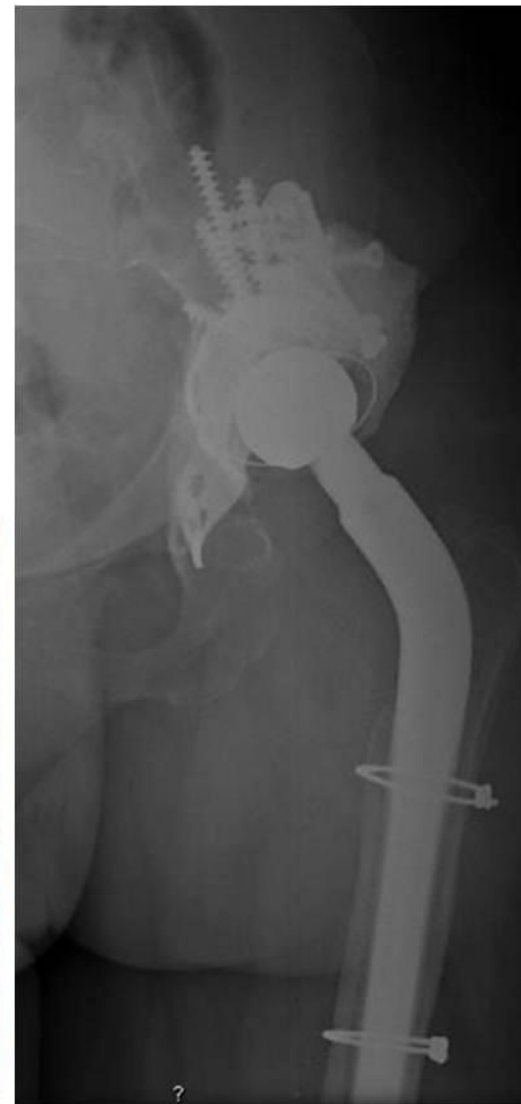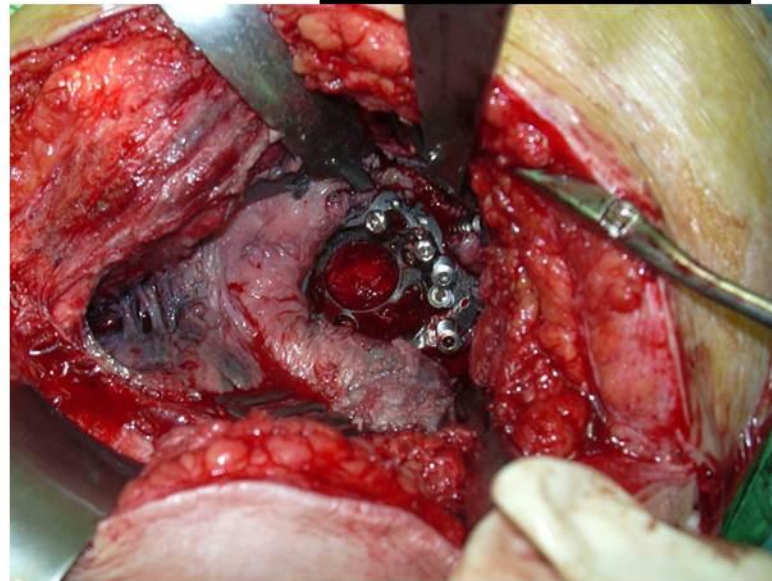
“ Butée ” with cement , 3 screws



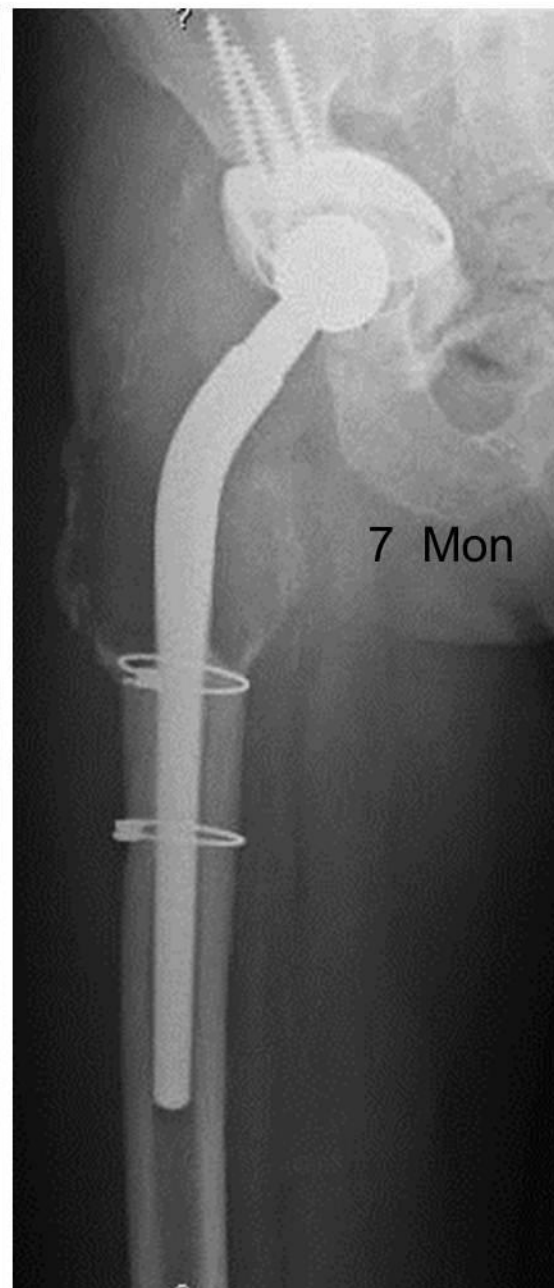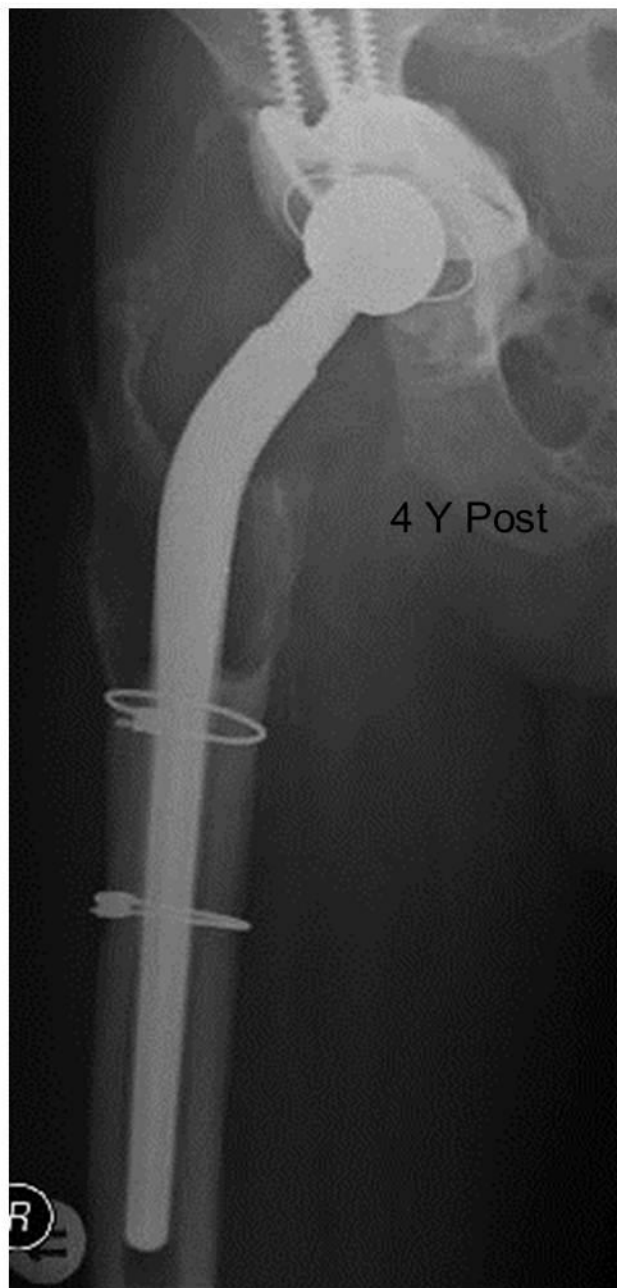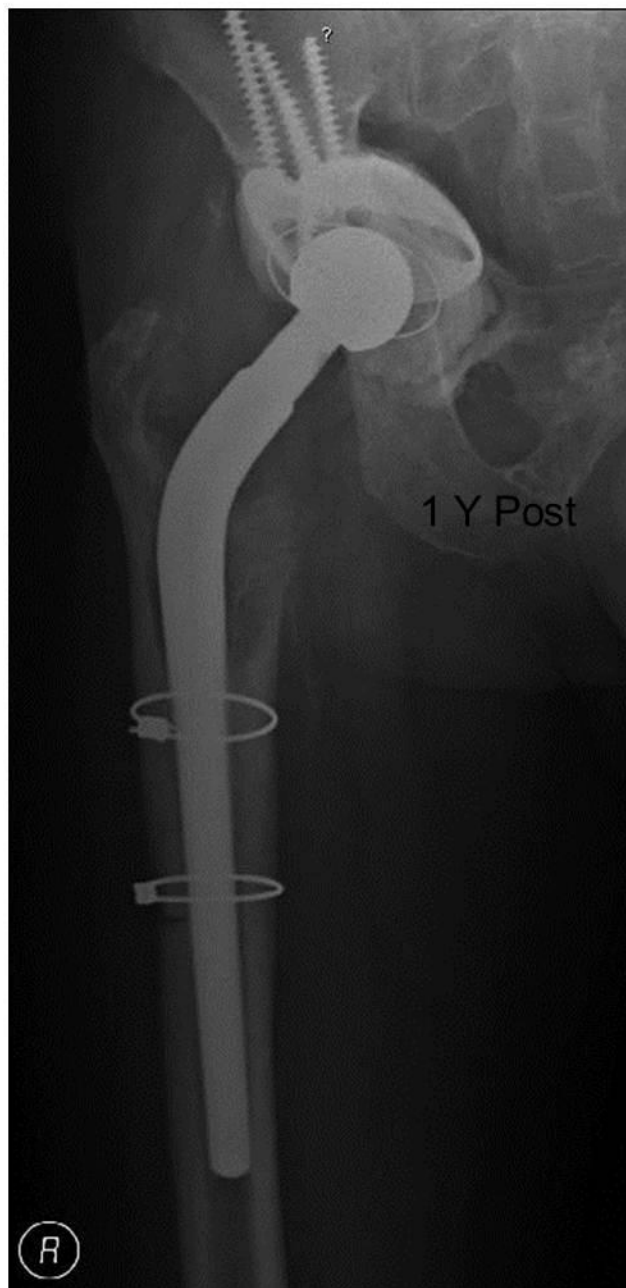**Dislocation with fracture of the cement, retroversion of the cage.
Reconstruction with acetabular augmentation (3 screws in the cage
+ cement)**



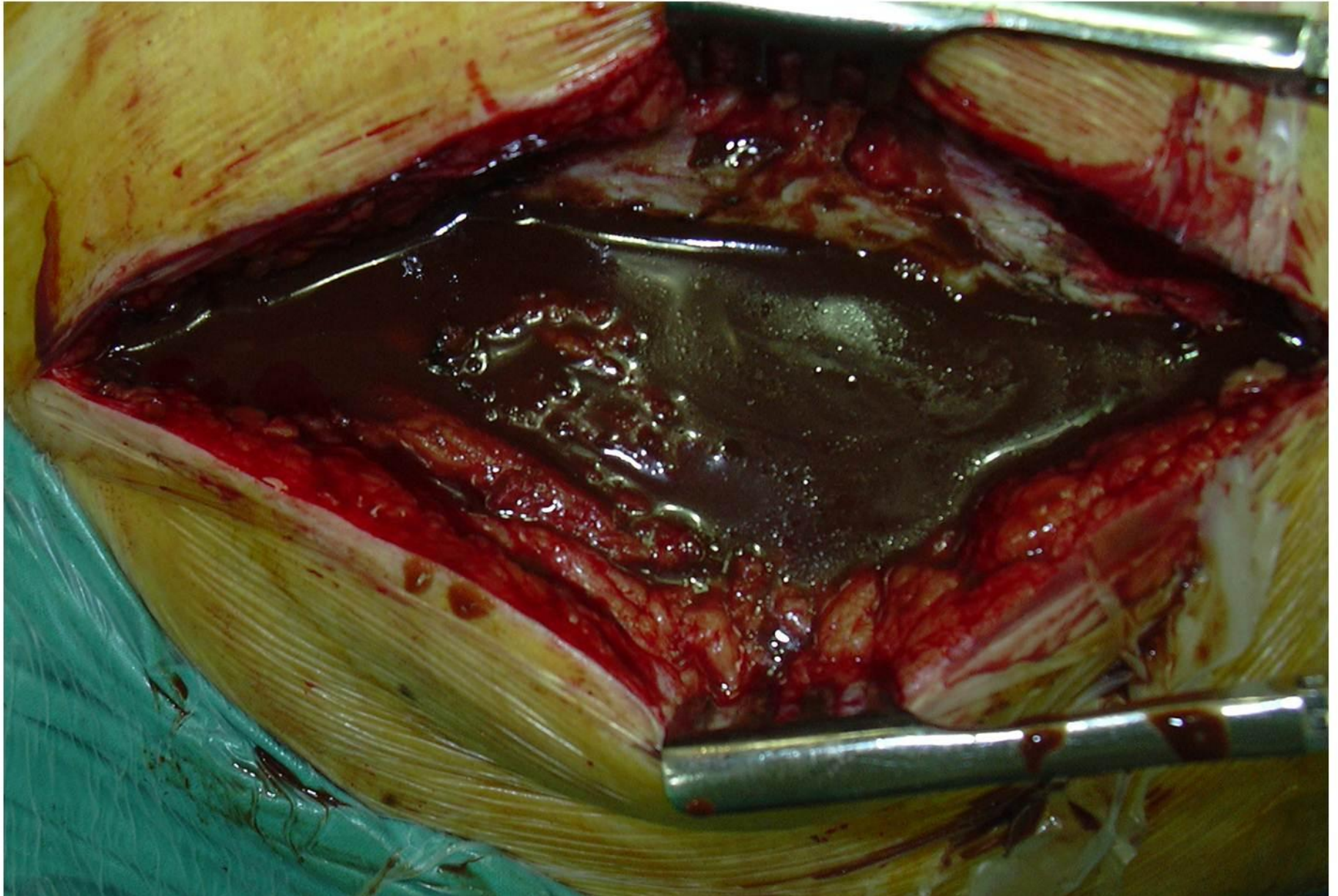
HUC



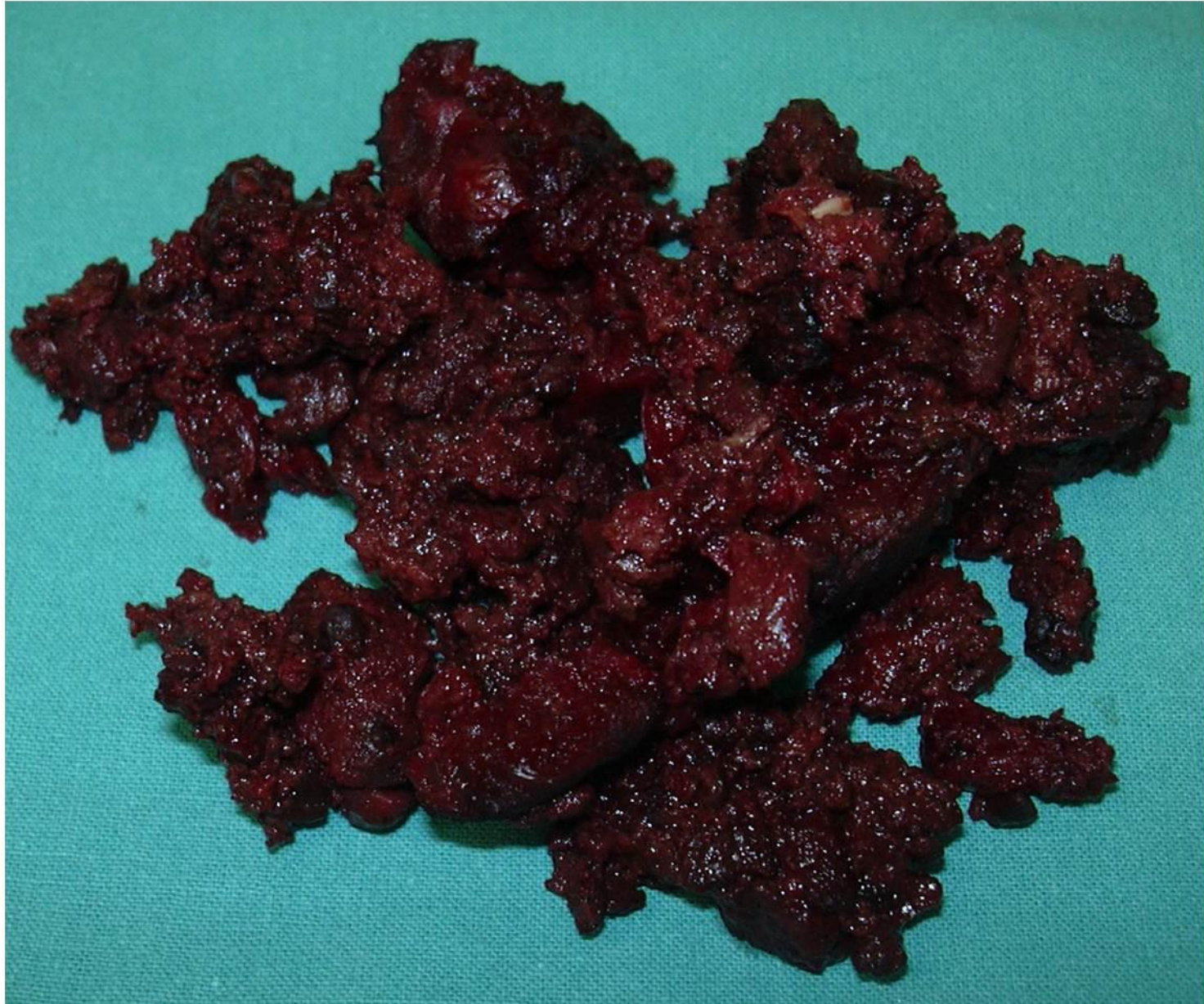Severe bone loss of the proximal femur with a rapid progression in a stable revision hip prosthesis



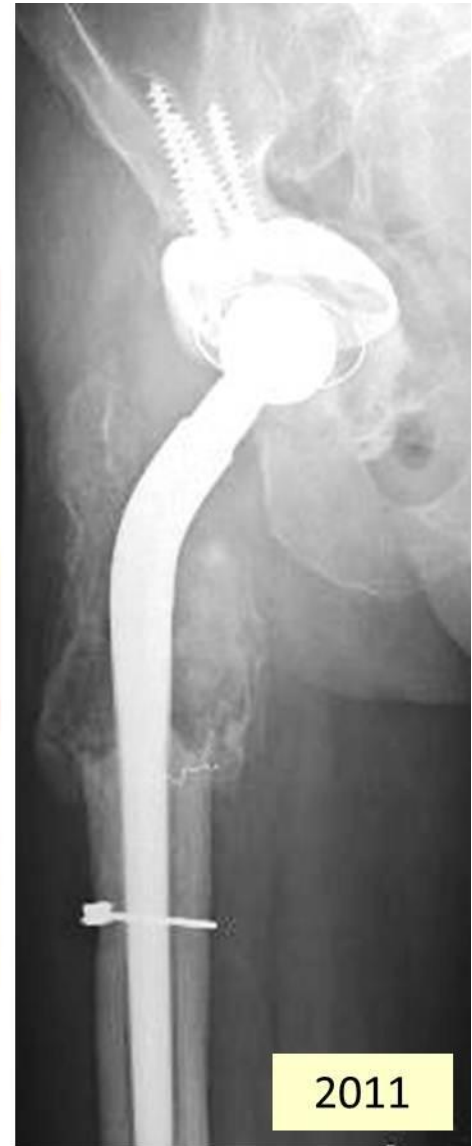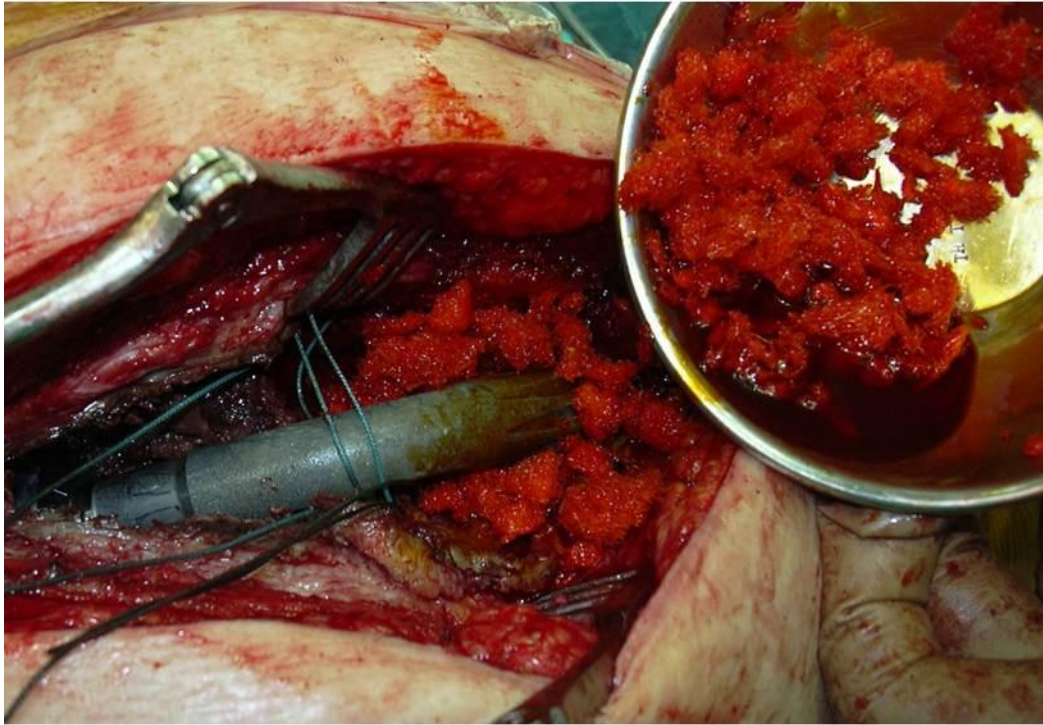
Intra-operative finding: large amount of a brownish fluid under great pressure (400 cc) in the pseudojoint cavity and in the joint space.



The specimen from the surgical operation revealed fibrous and necrotic material

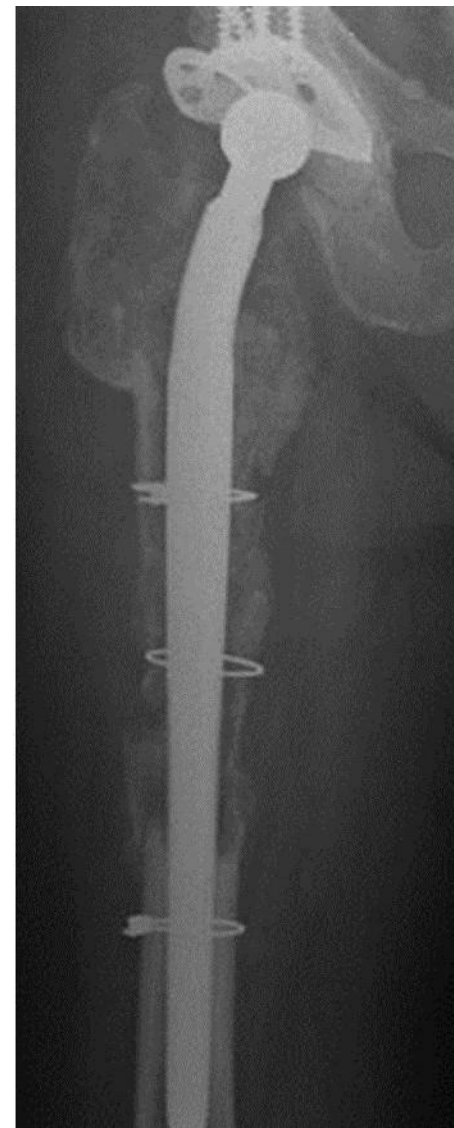
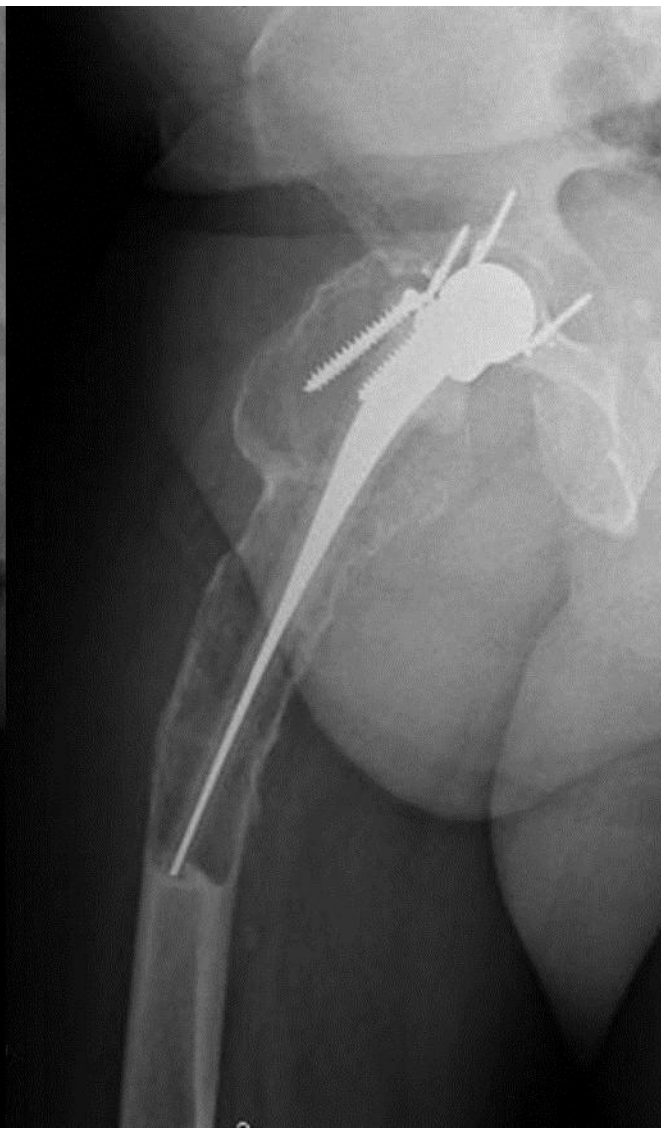
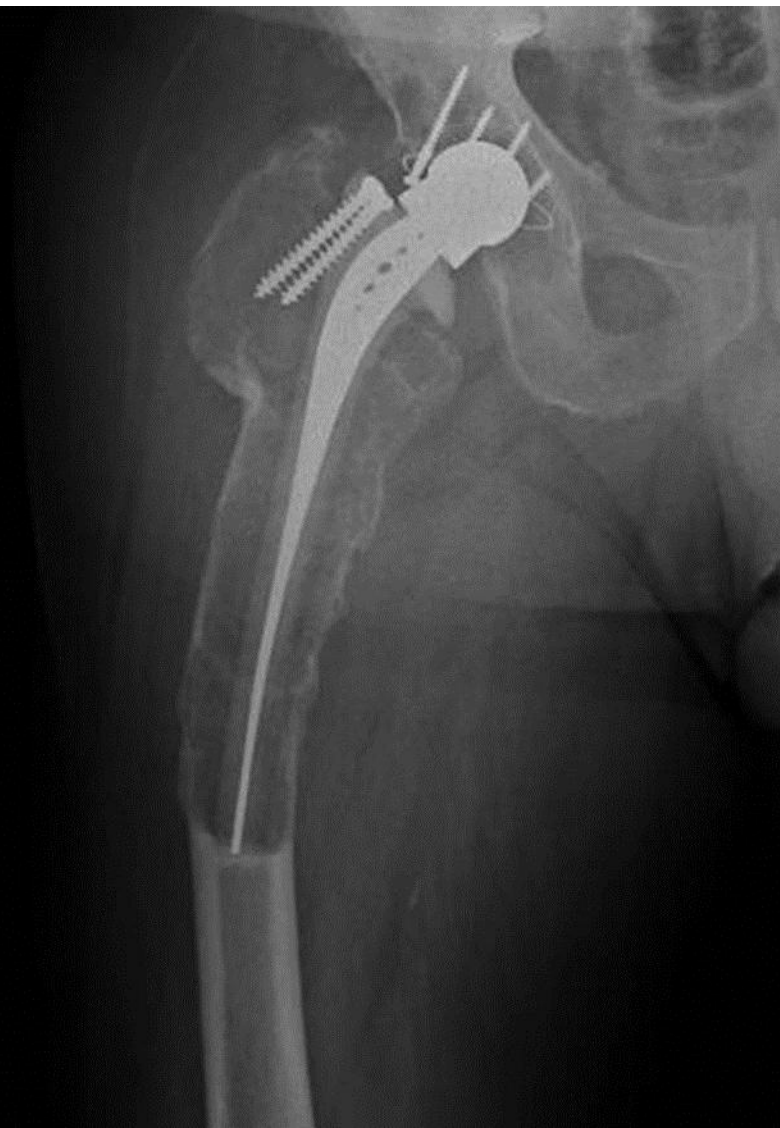Femoral reconstruction with cancellous bone allograft

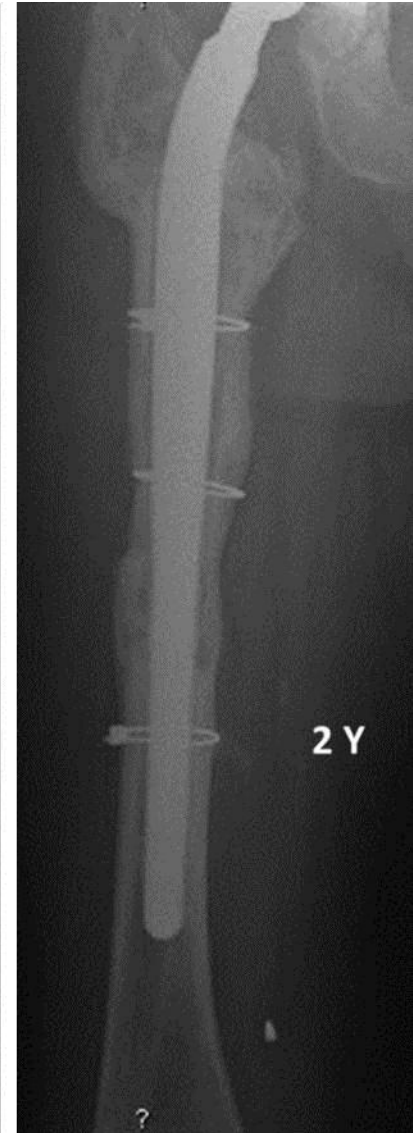
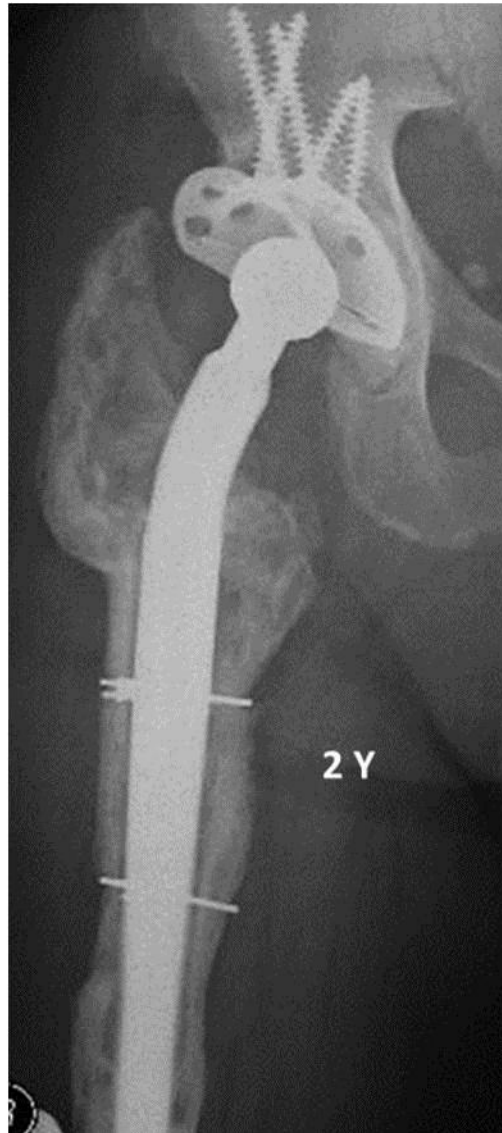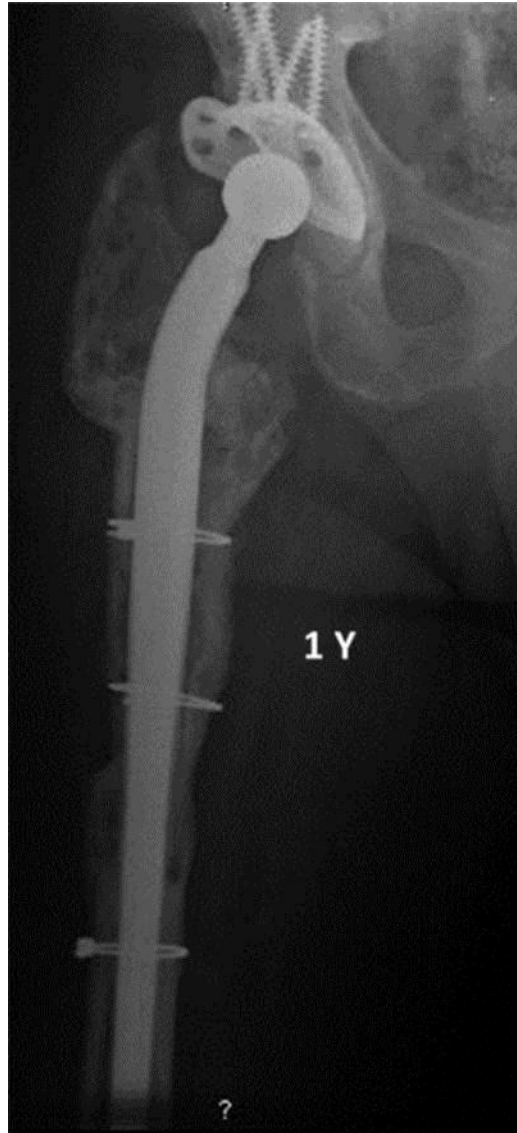


2011

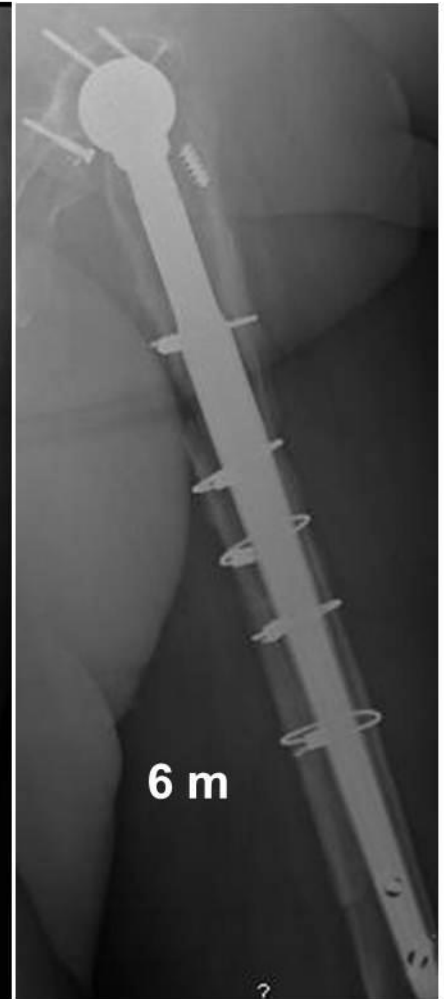
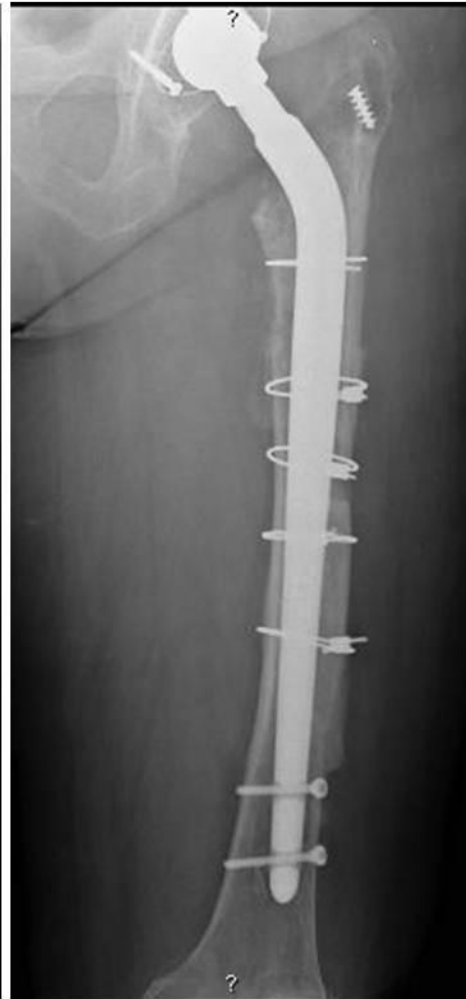
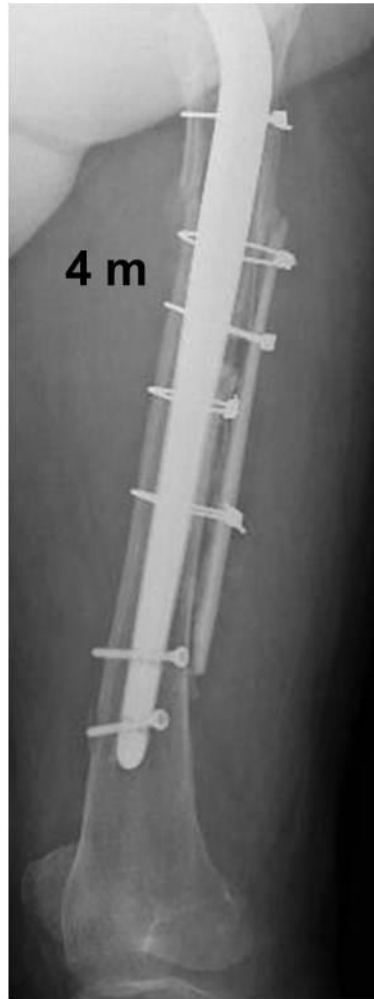
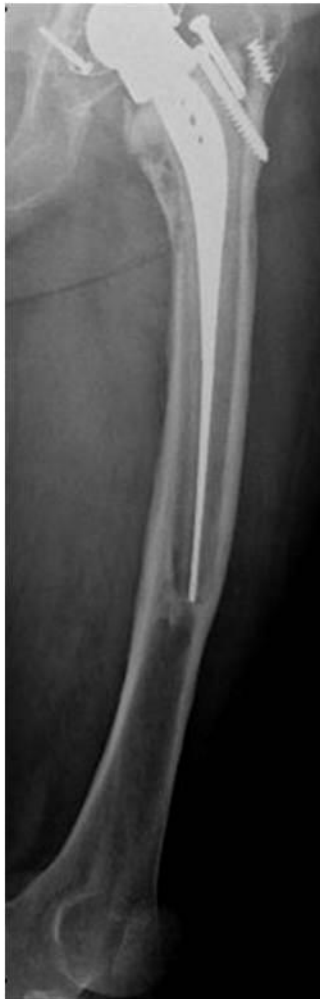PU 1940.... male, 2007, severe femoral ectasia



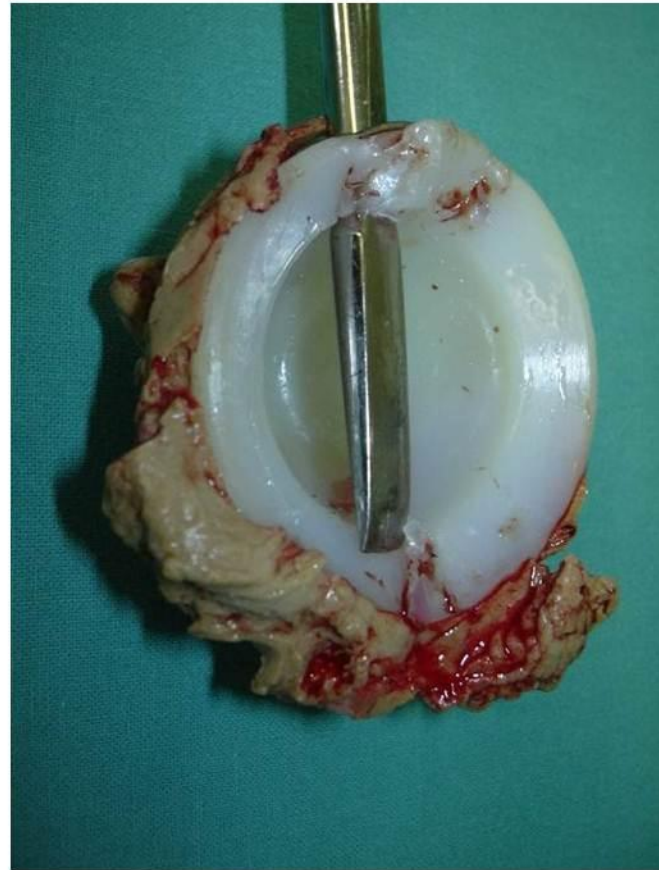
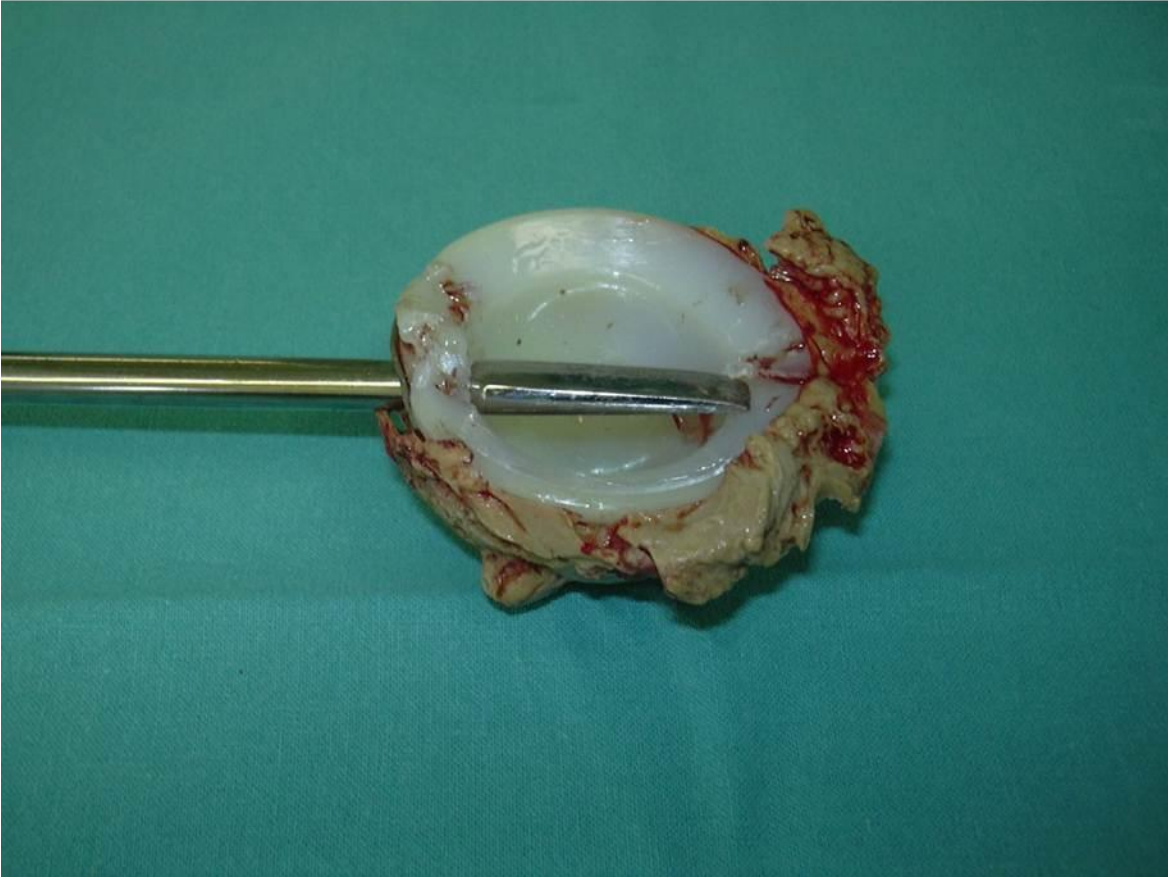
Femoral reconstructon with cancellous bone allograft

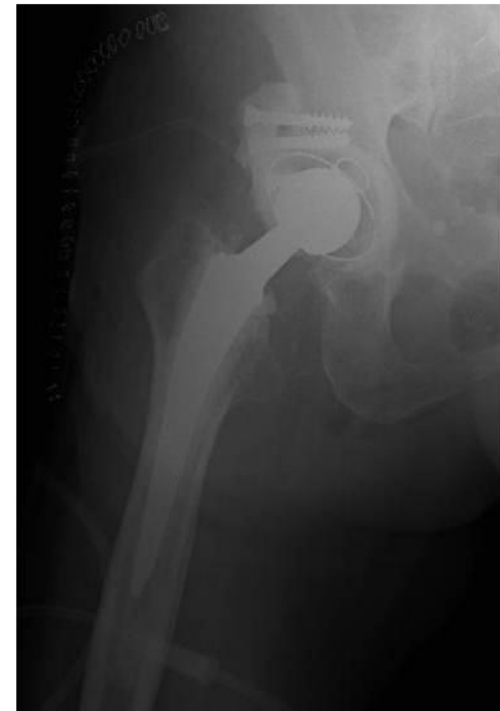
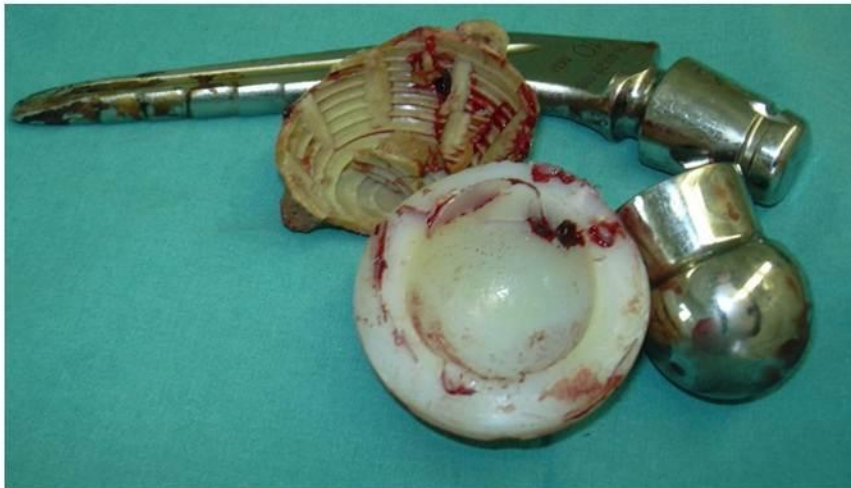
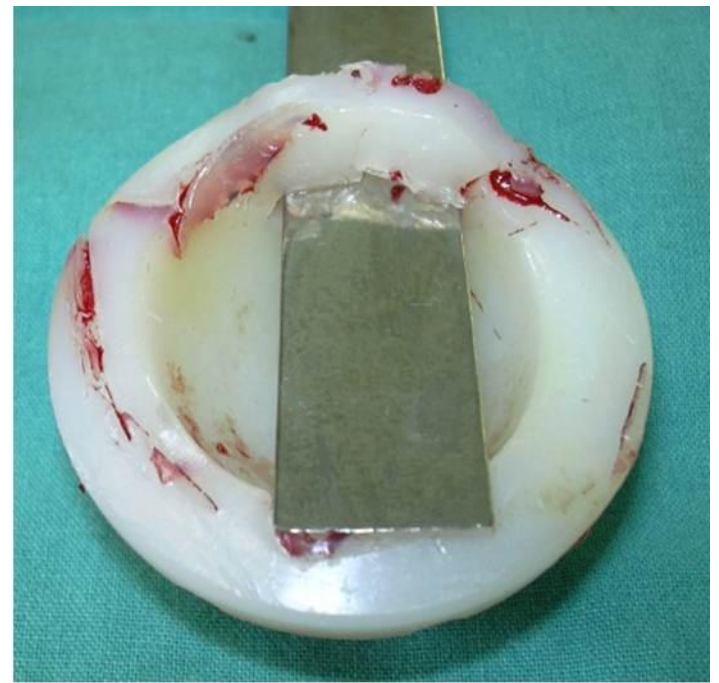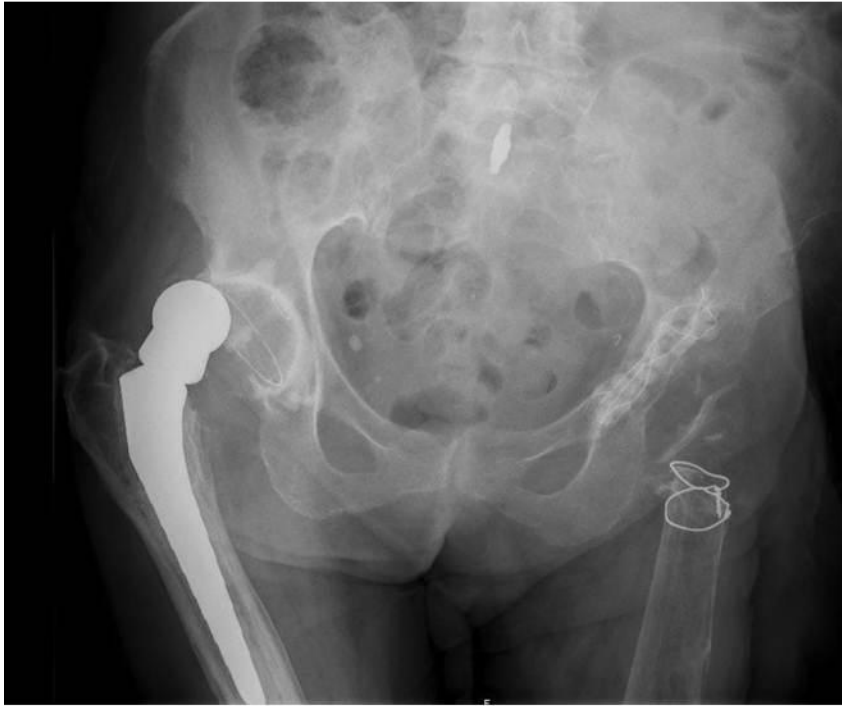Pu 1935..femal...2009....transfemoral approach + cortical strut

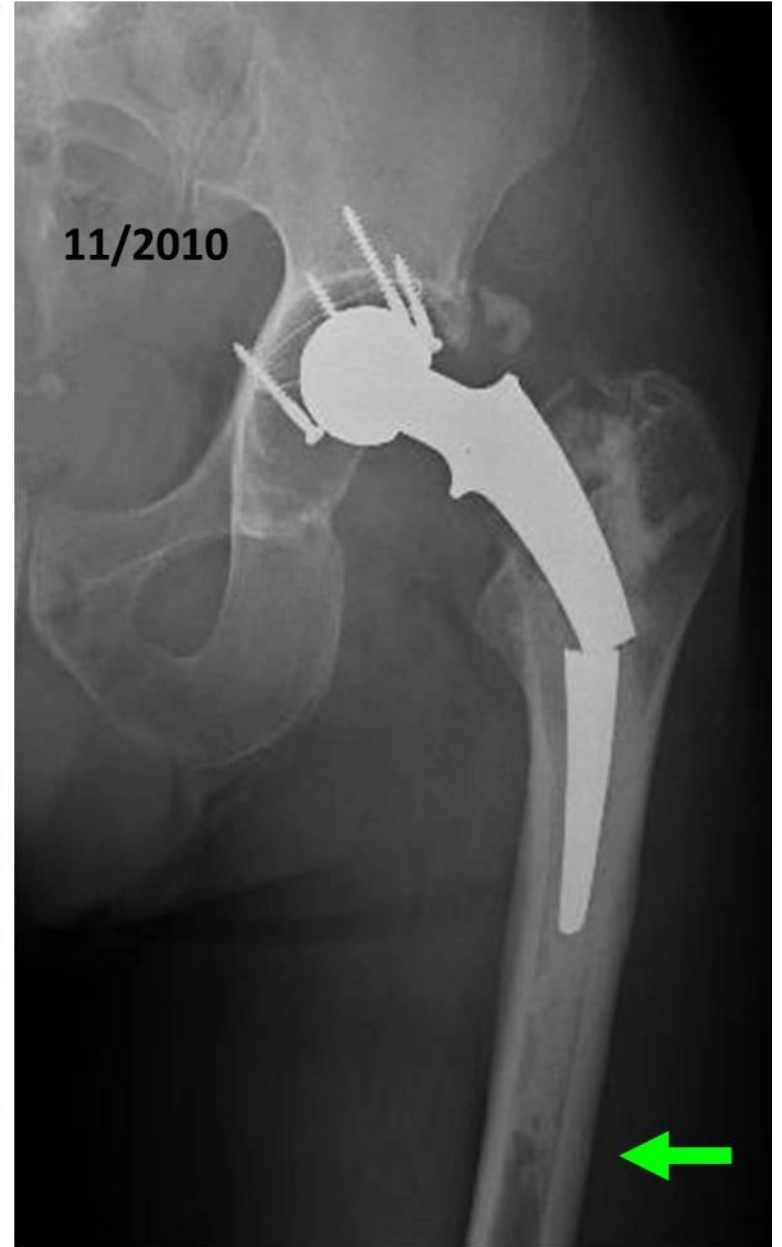
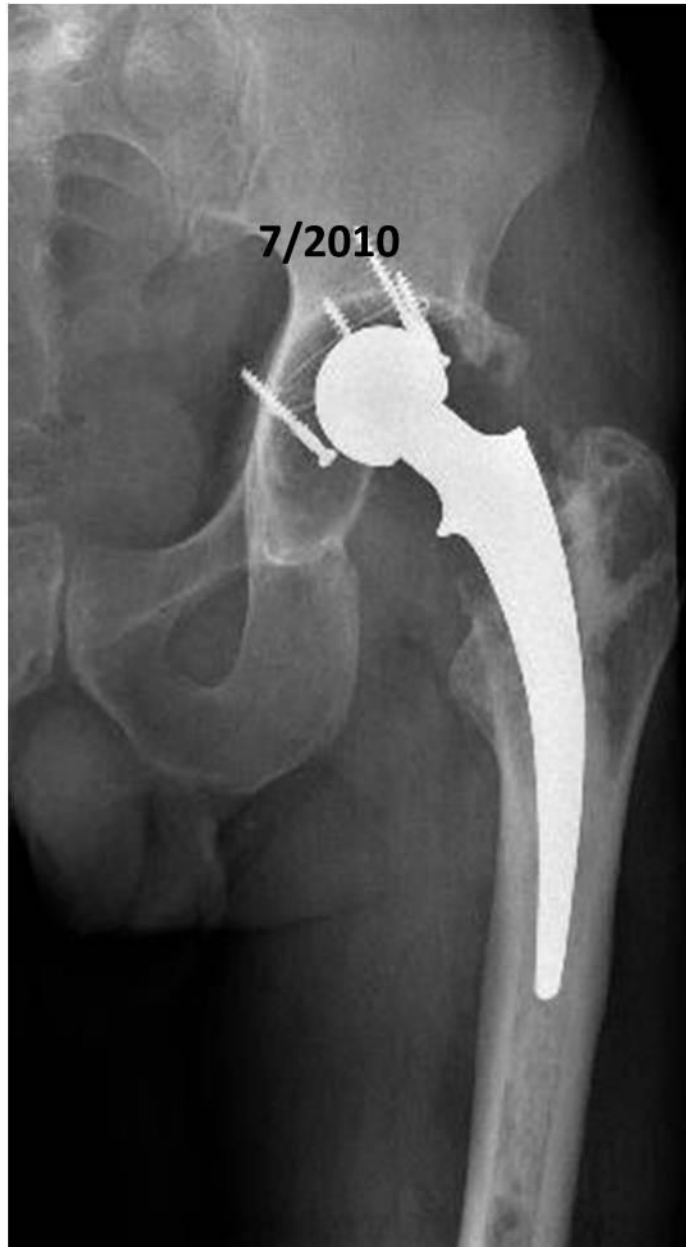
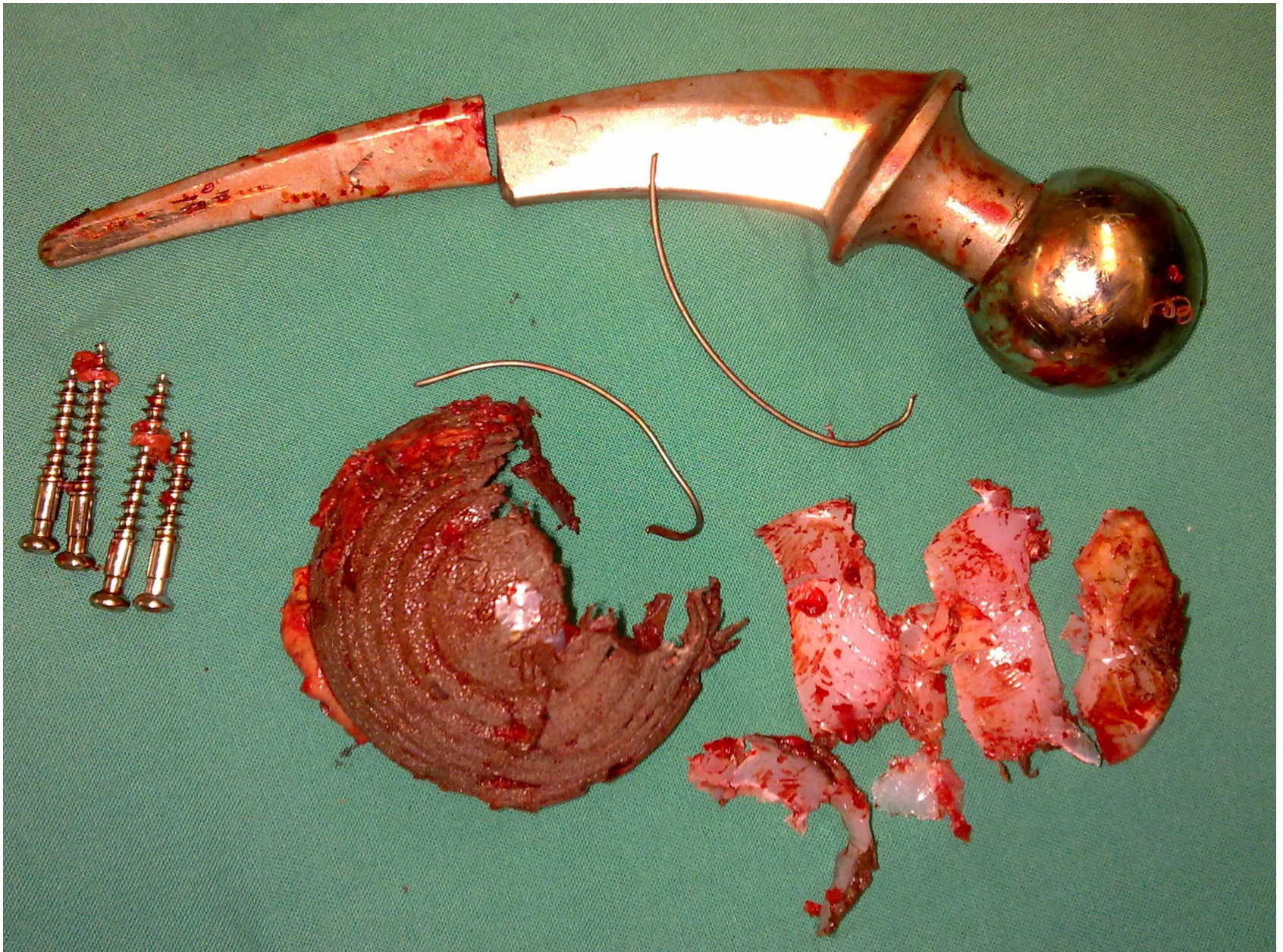Joystick



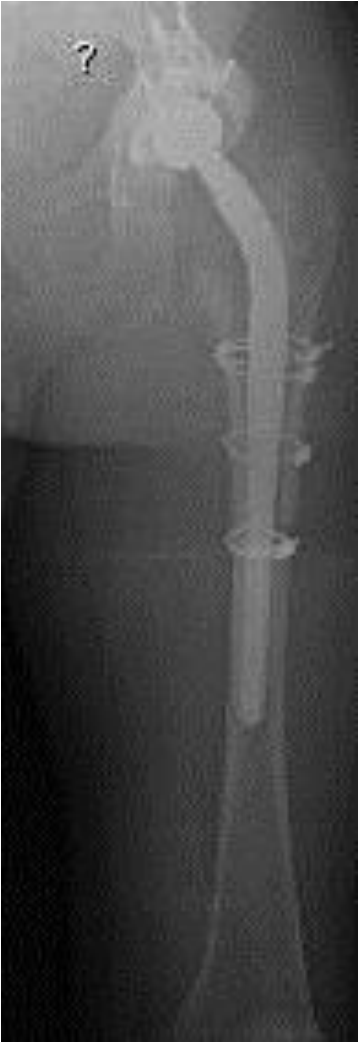
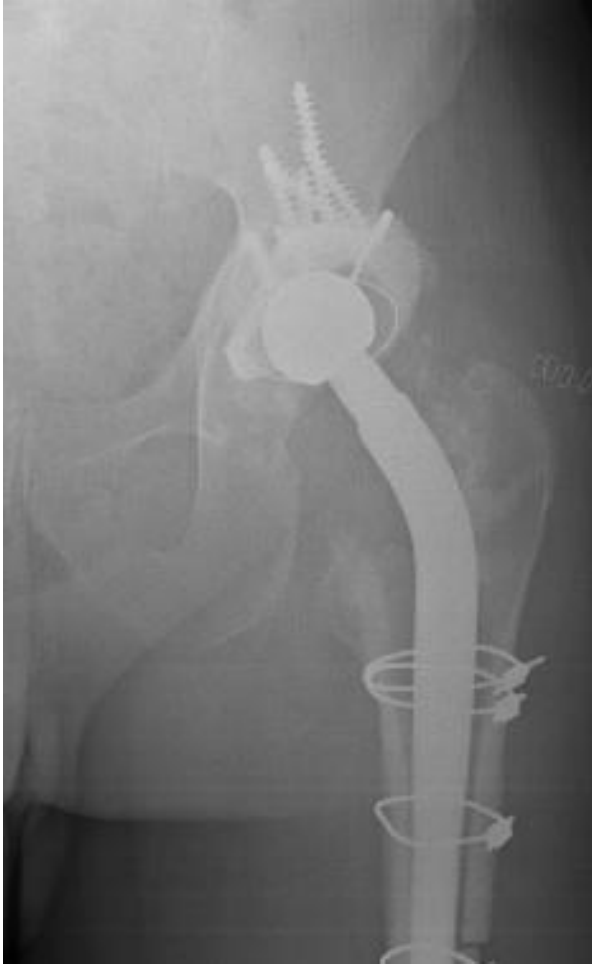
PU 1932..... male, NOV 2010

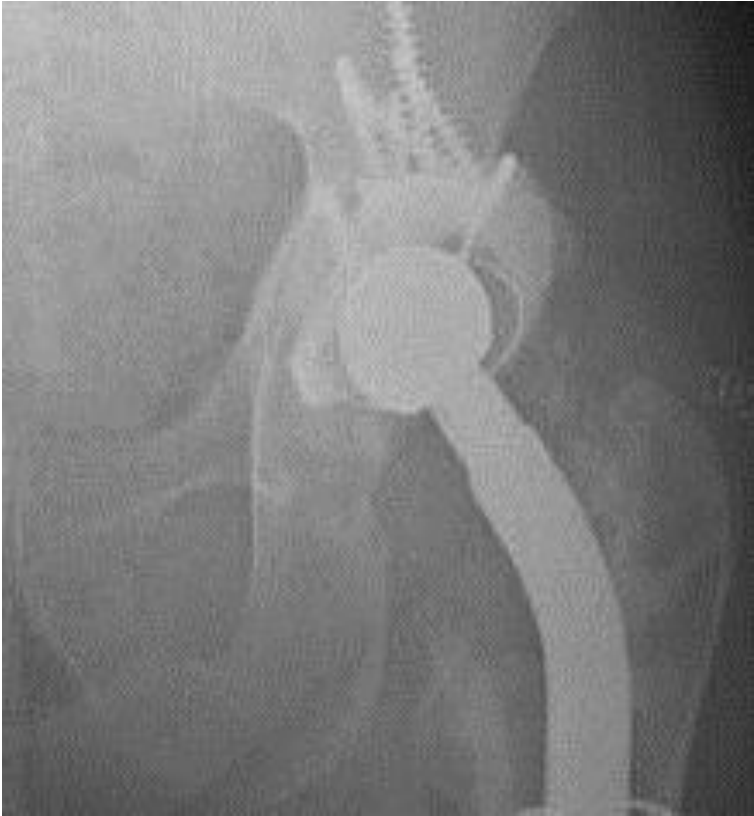




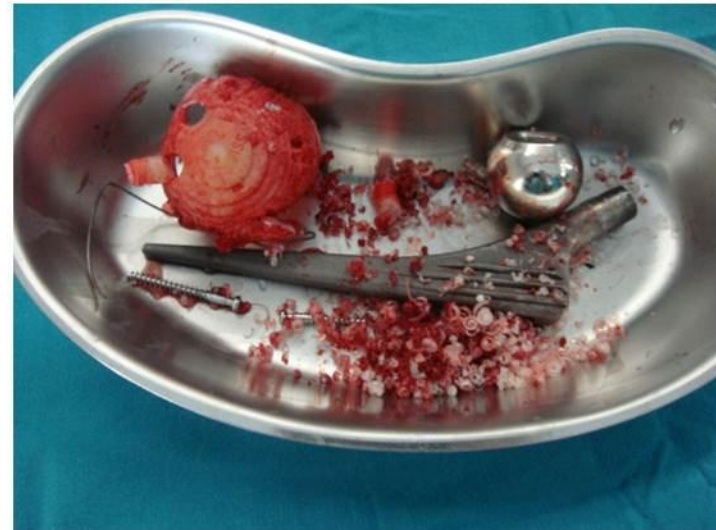
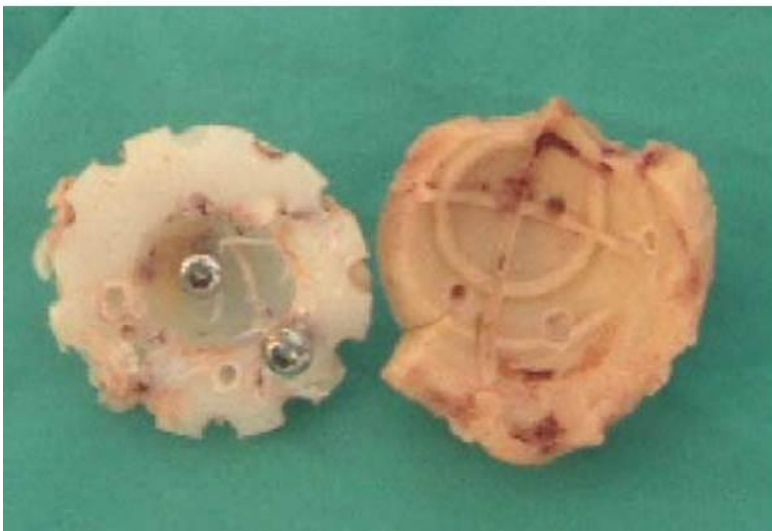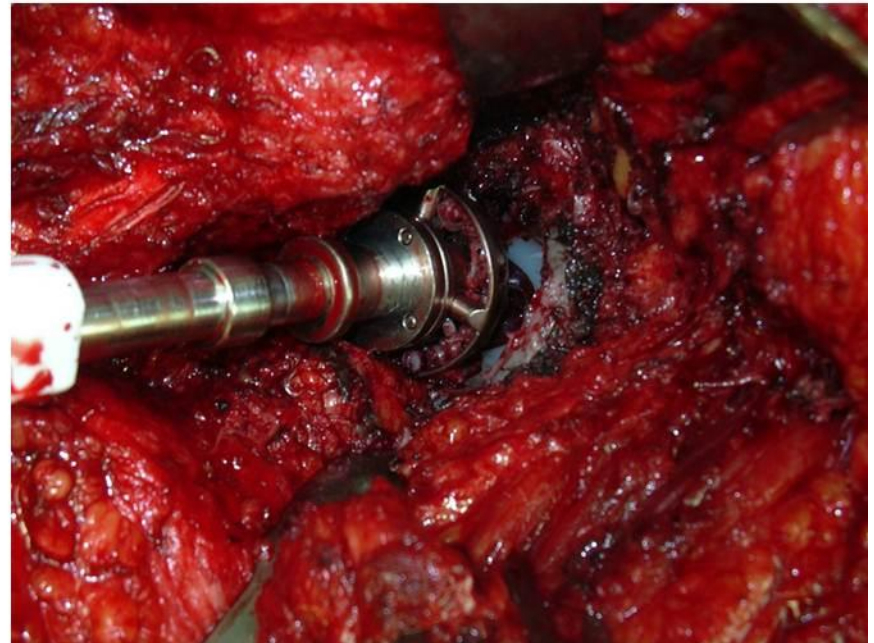
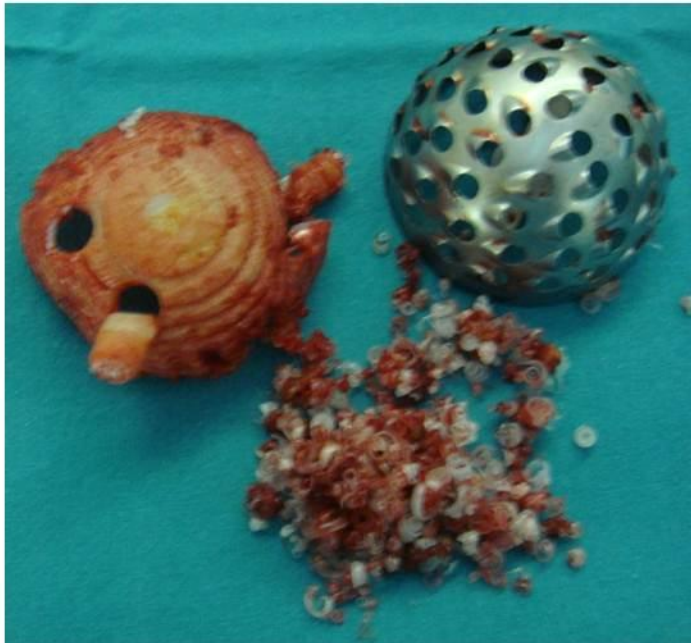PU 1932..... male, NOV 2010

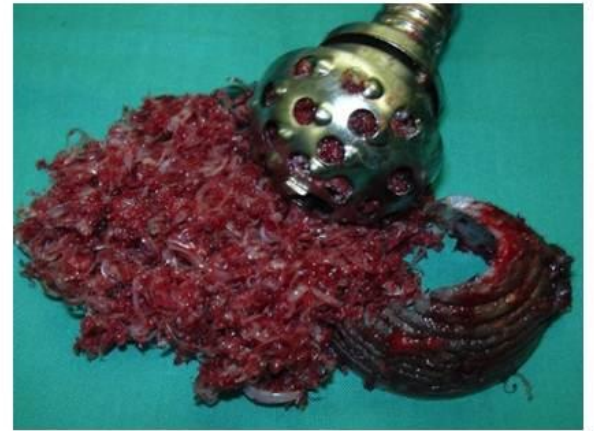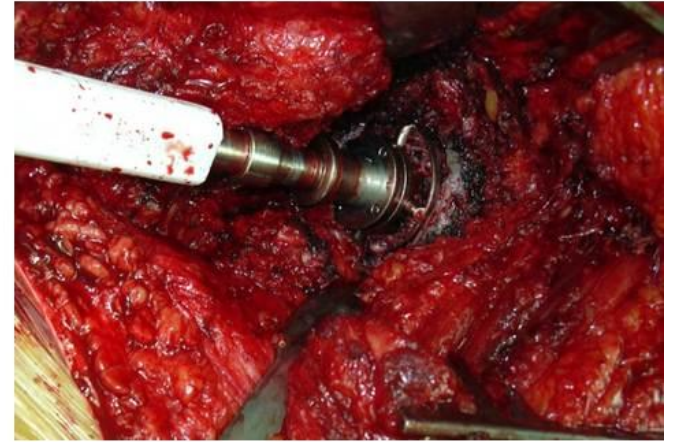

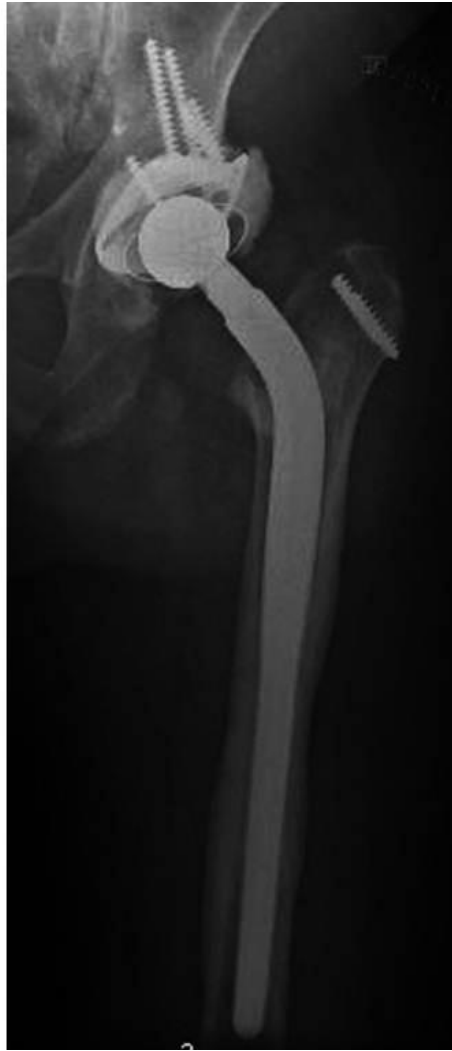
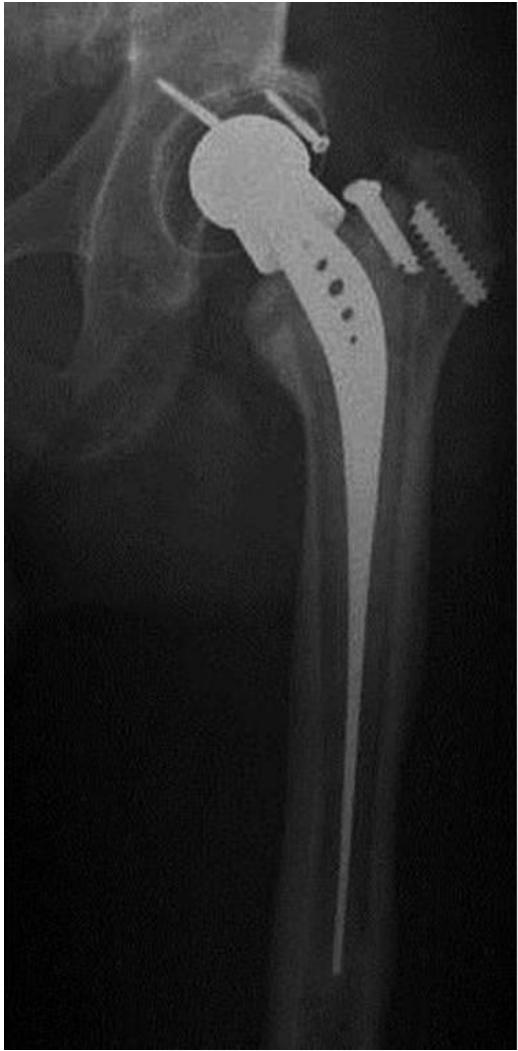Transfemoral approach



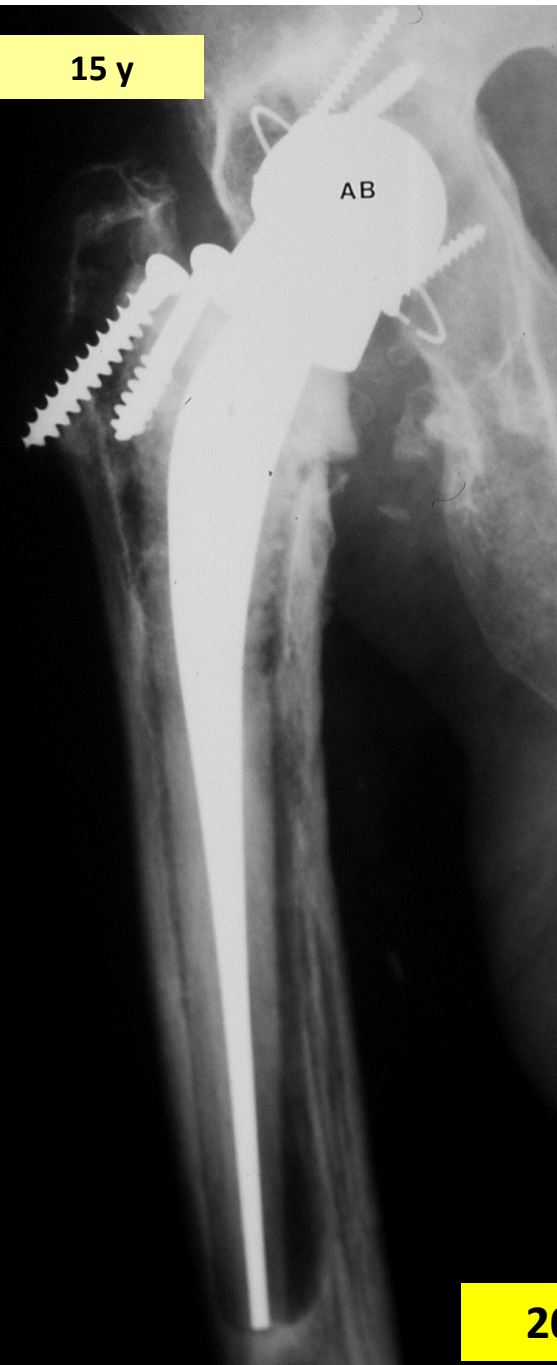
Removal of the implants



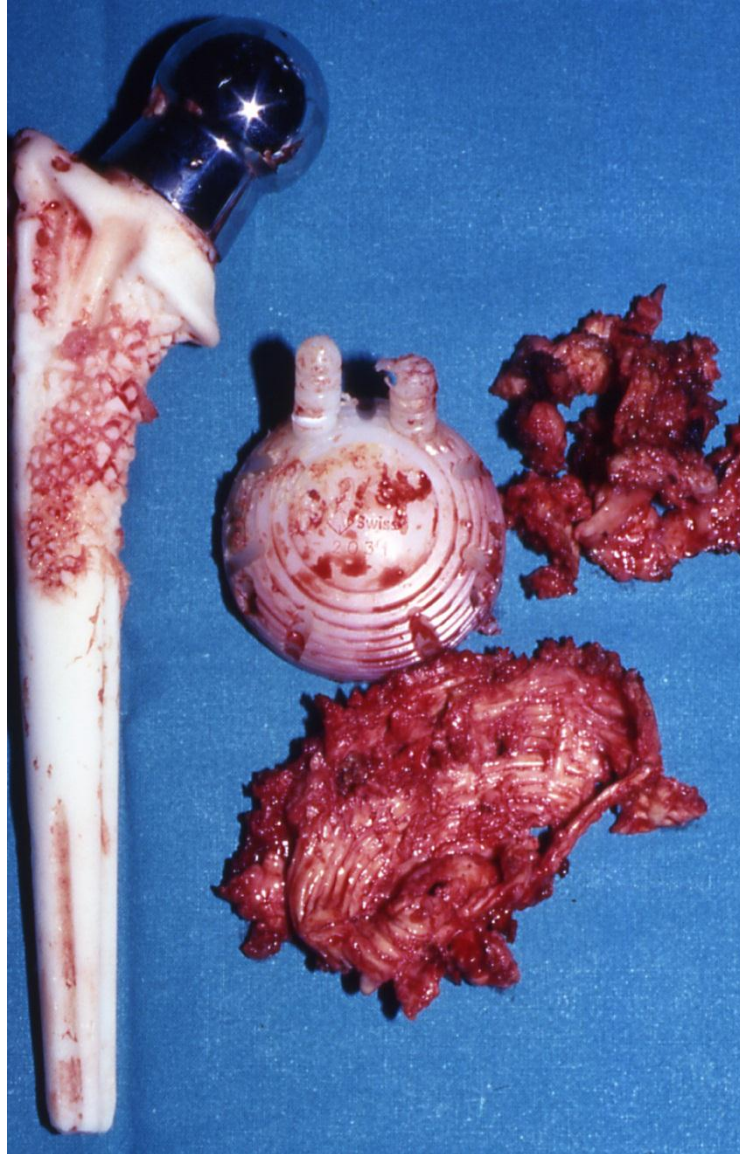


15 y

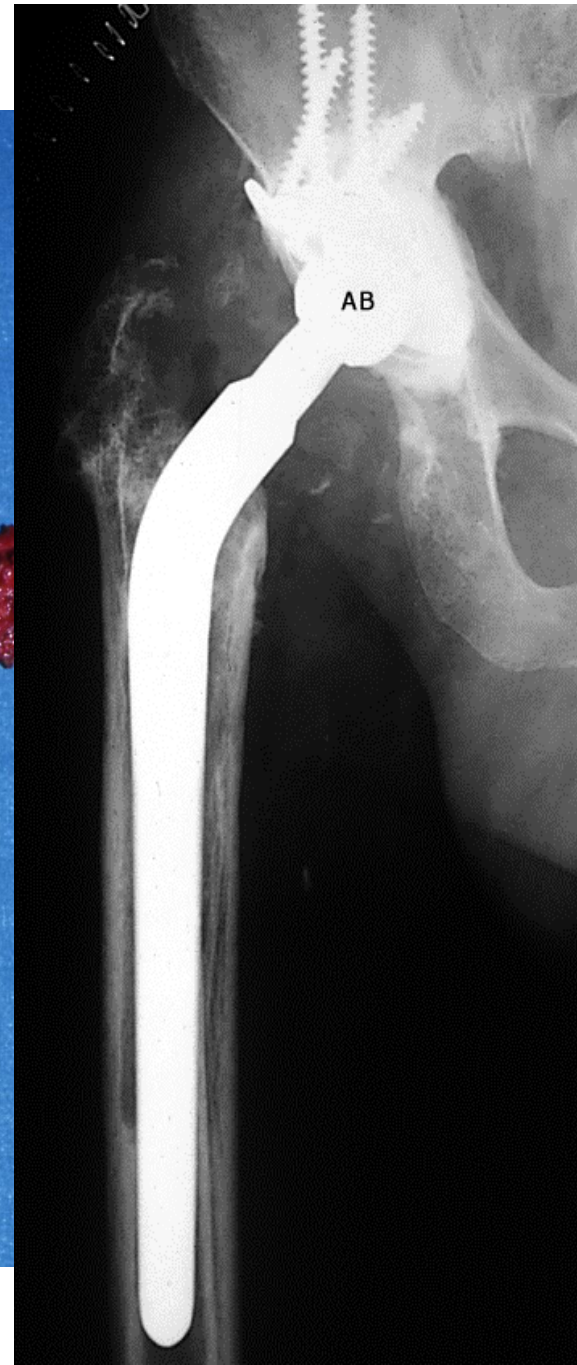
AB



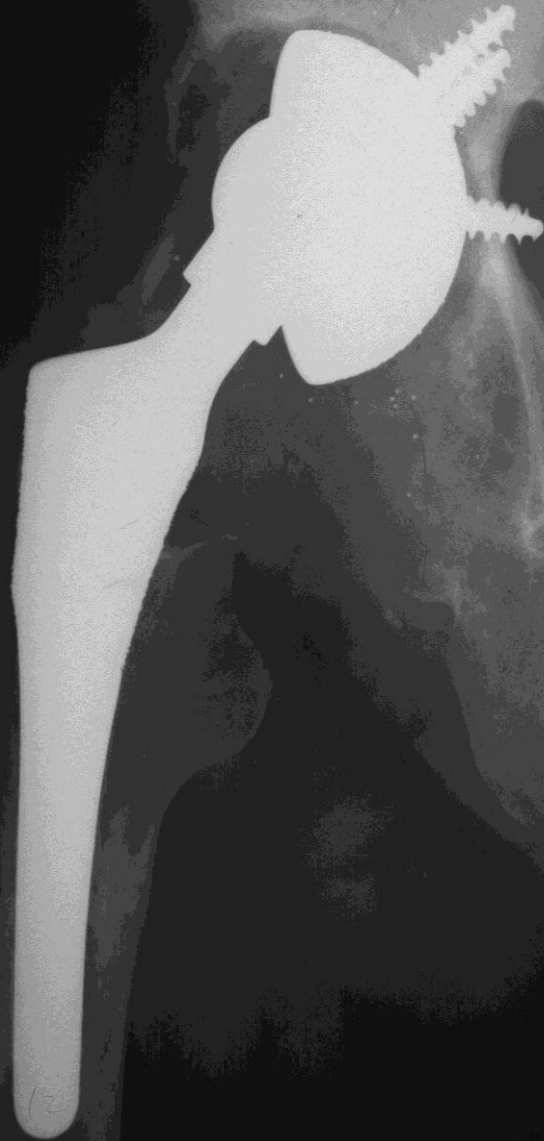2000



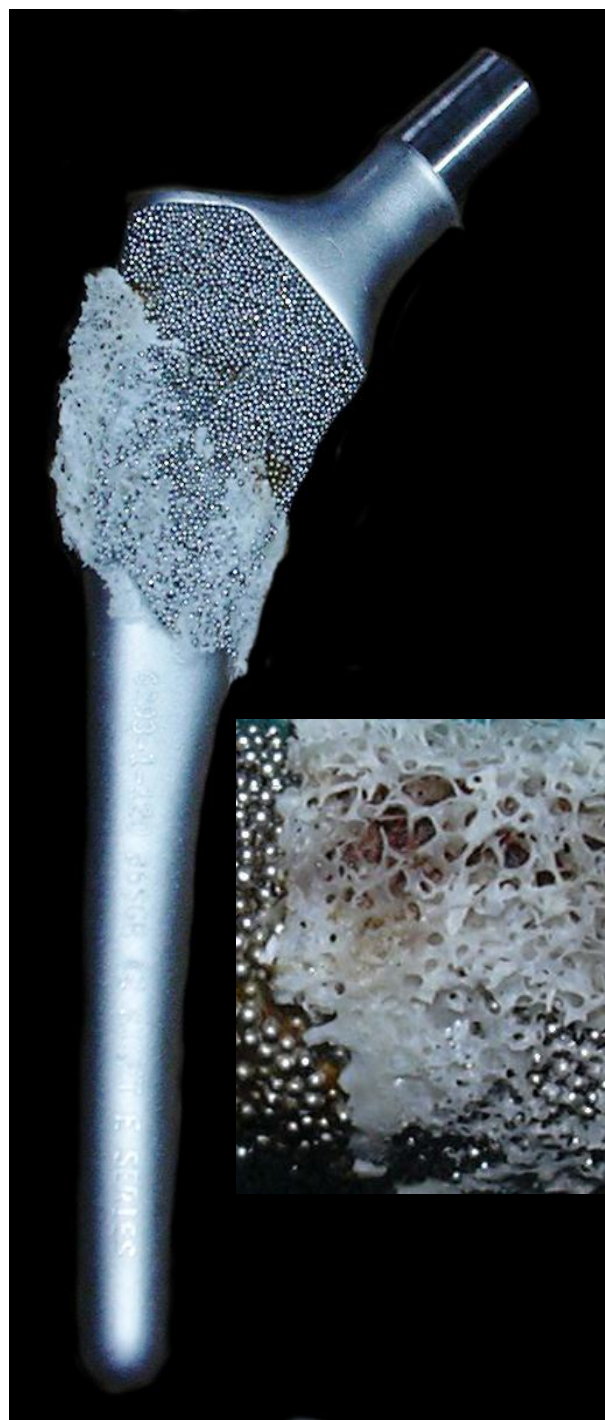AB



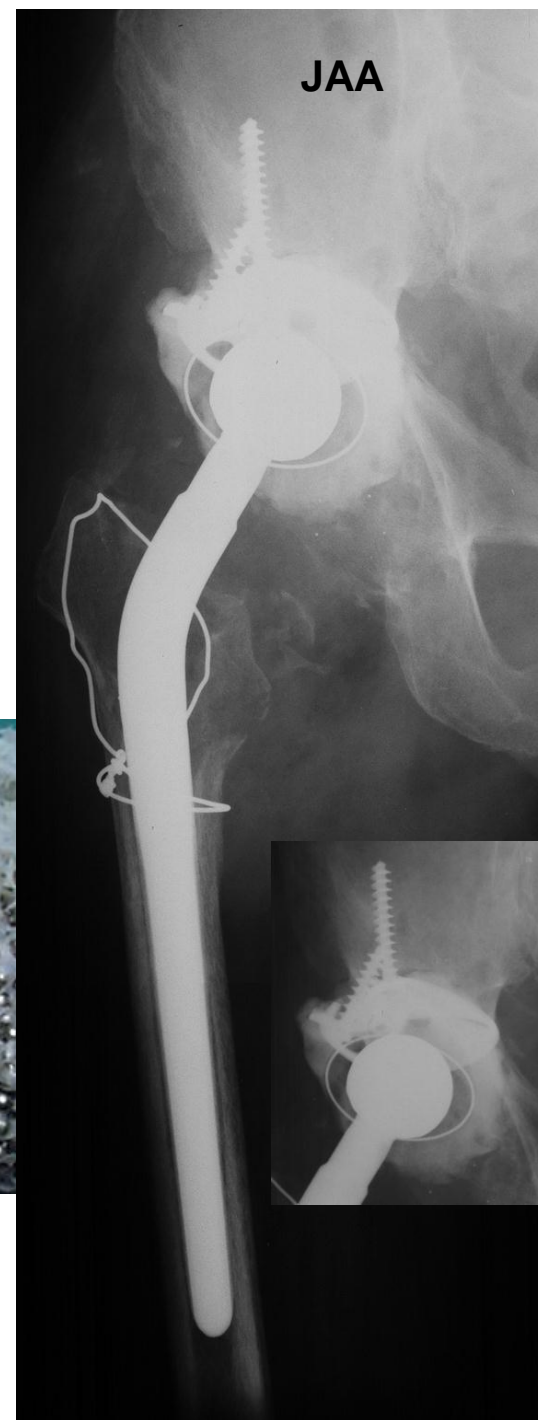
JAA



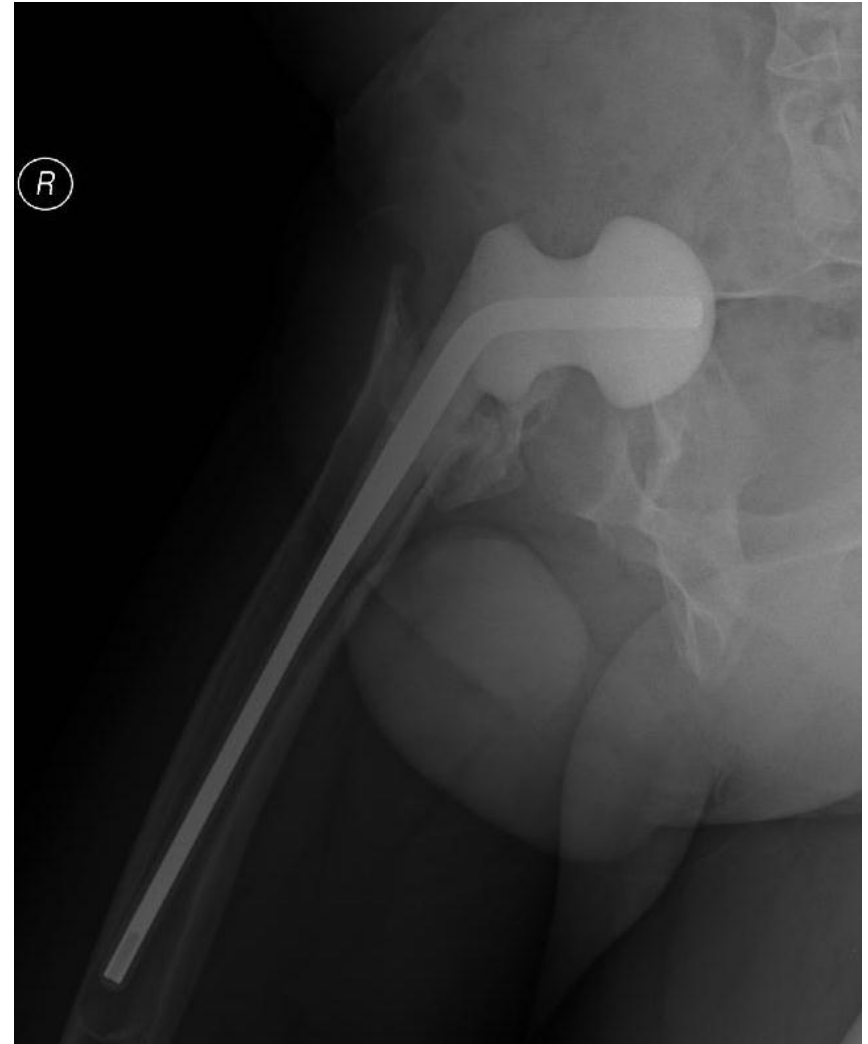
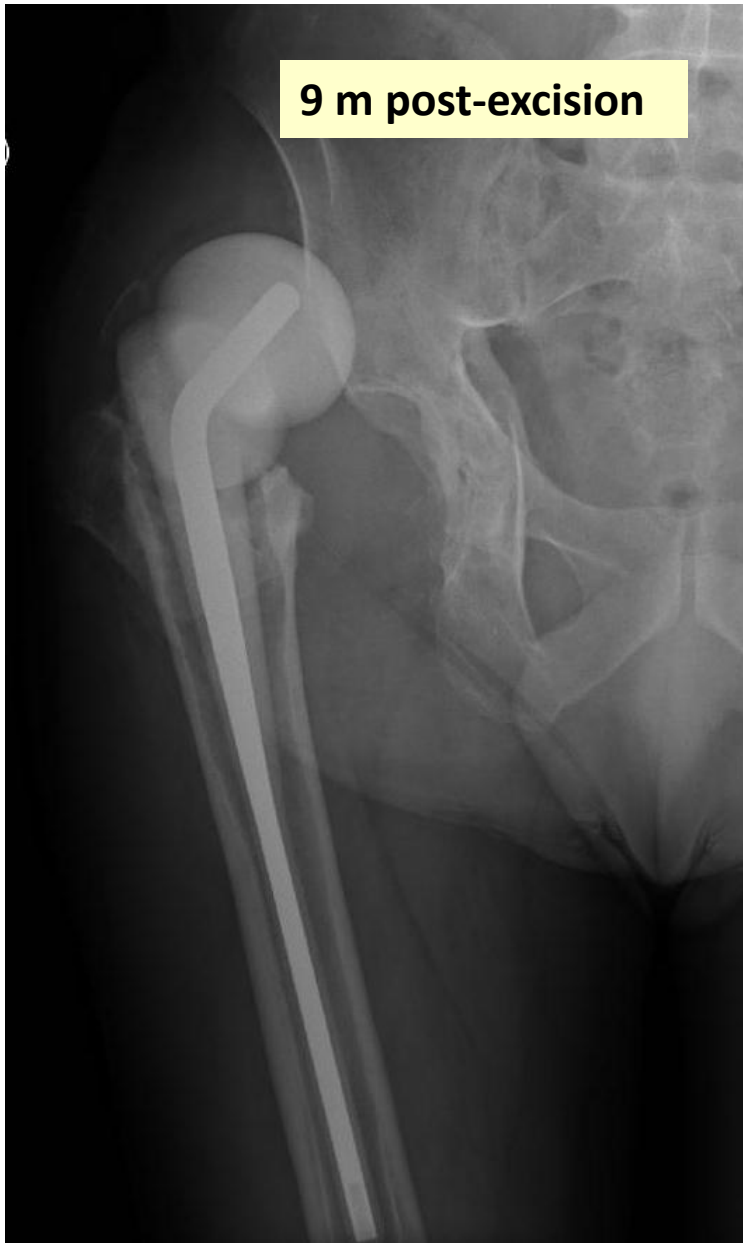2003



JAA

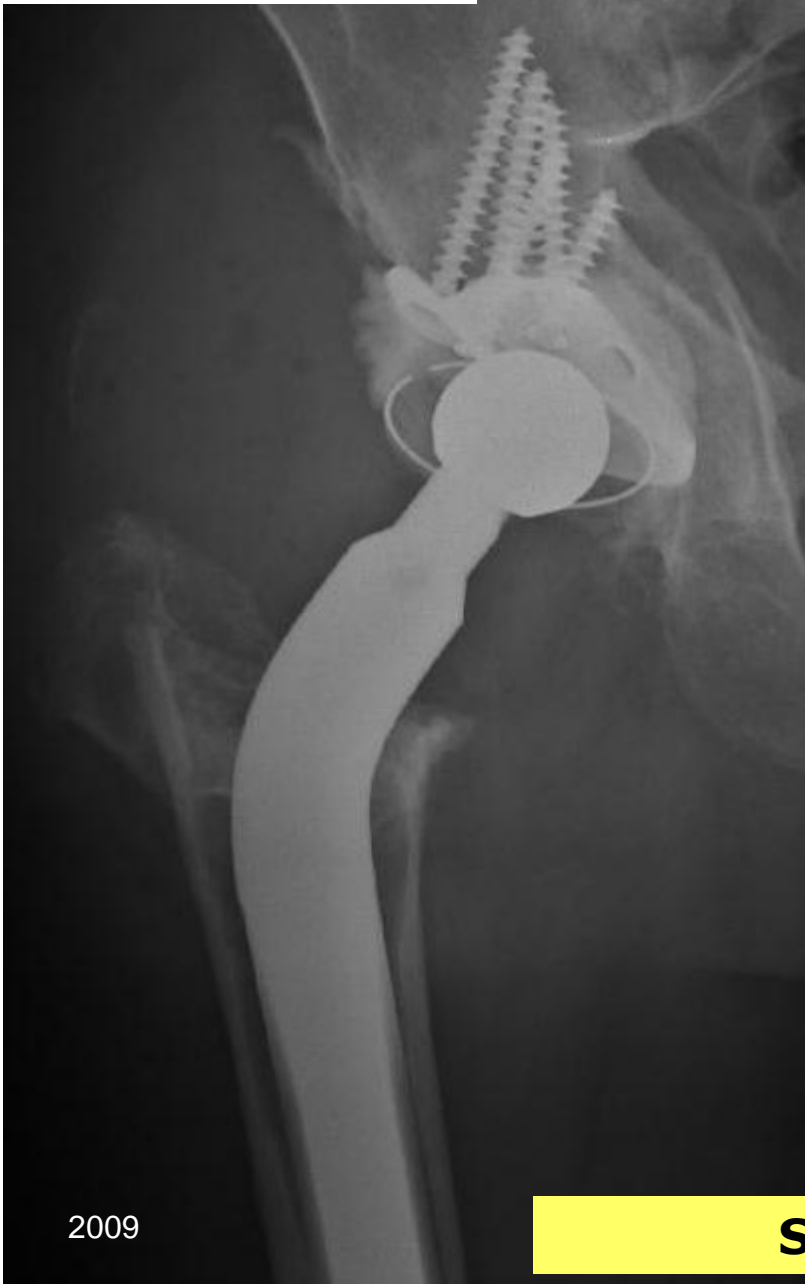

Infection of a revision THP

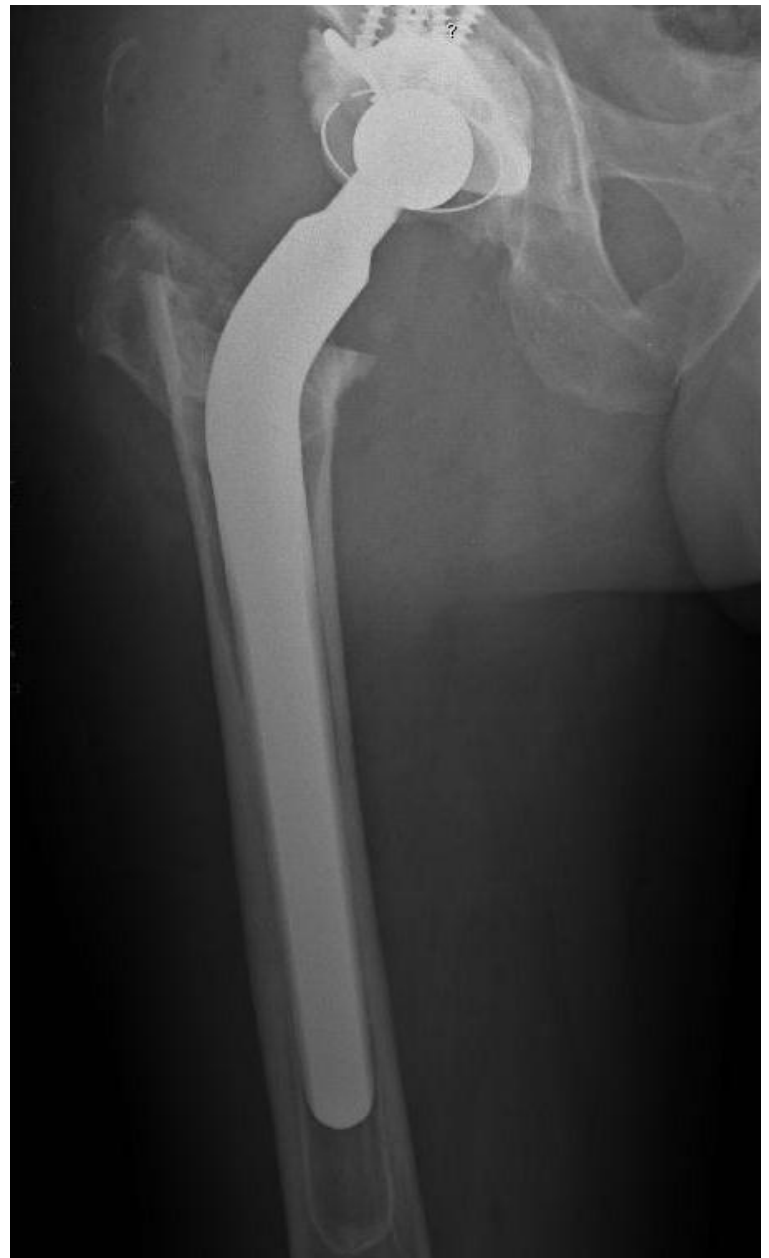

First-stage revision

PU 1972....post-op



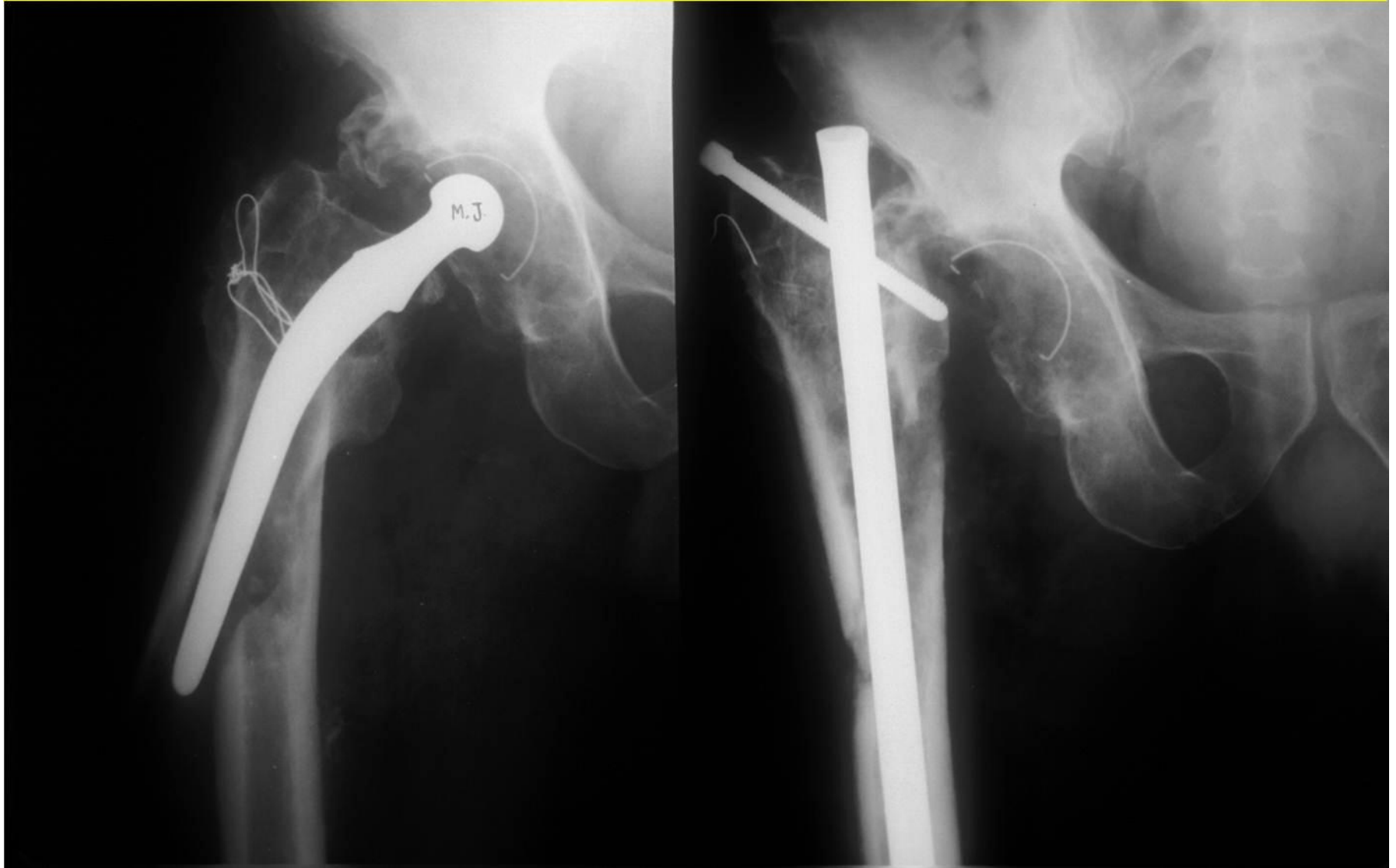
2009



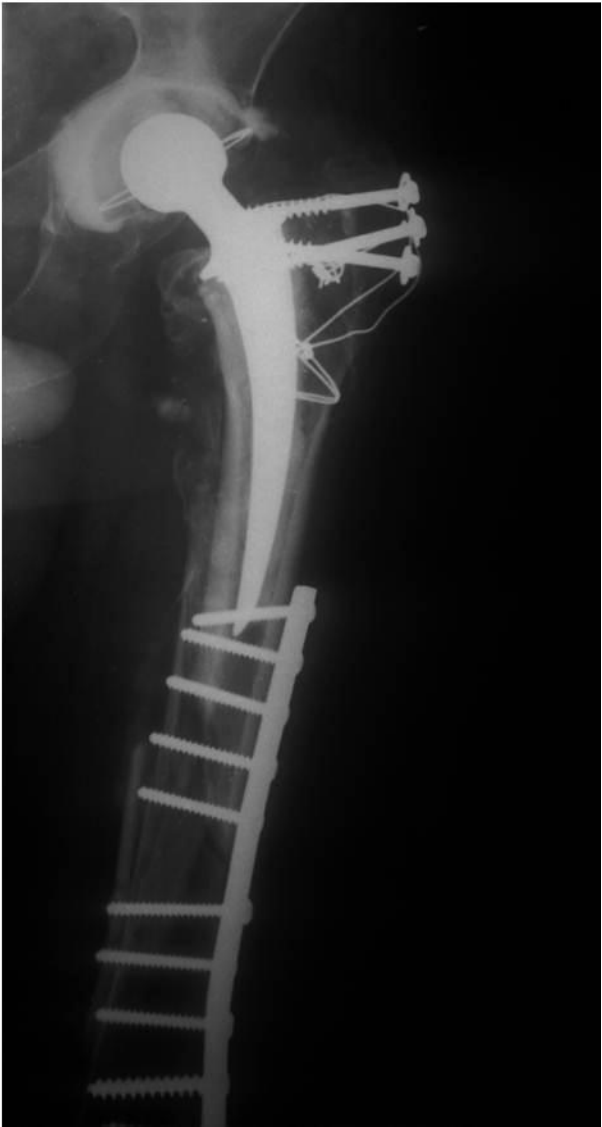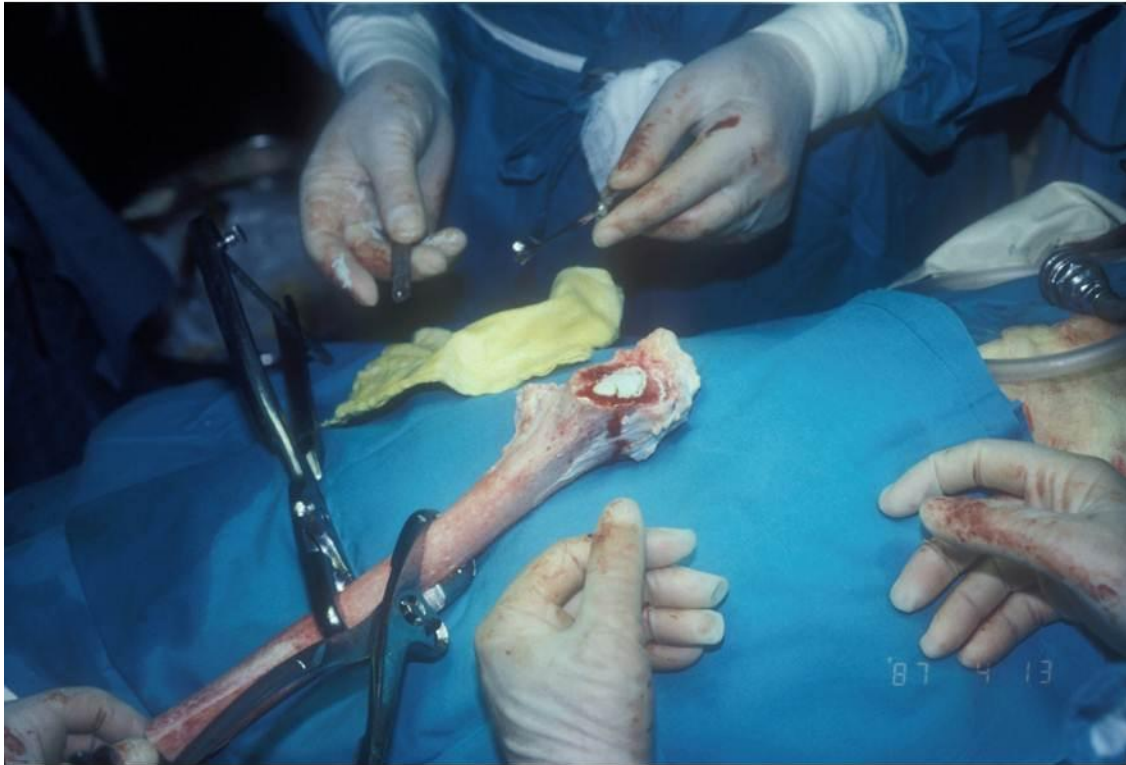Second-stage revision

The past: two-stage revision procedure of a periprosthetic fracture with femoral loosening

Serviço de Ortopedia dos HUC



The past



Final Notes

- *Revision hip arthroplasty is a complex procedure with a higher risk of complications (dislocation, leg length discrepancy, pain, infection, abductor dysfunction) and unforeseen circumstances.*
- *Surgical planning is indicated for every revision hip arthroplasty, whether it is a straightforward or a complicated case. The preoperative planning is defined in the outpatient clinic and should be repeated just before surgery. Templating may allow the surgeon to predict intraoperative difficulties and possible complications.*

- *Preoperative planning is required for: the surgical approach and patient positioning; the type of implants to be used; the method of the prostheses fixation (cemented, uncemented, hybrid); the need for bone grafting; help to reduce surgical time; minimize risks; decrease the stress level of the entire surgical team and increase the rate of the successful outcomes for patients.*
- *The removal of cemented and well-fixed porous-coated implants can be done with adequate preoperative planning and a thorough knowledge of numerous implant removal techniques.*

- *The anatomy is usually distorted. Proximal femoral varus remodeling is observed in up to 30% of the patients with a loose femoral stem. The subsequent surgical reconstruction is challenging due to the deformed femoral bone. The transfemoral approach can be indicated in this situation.*
- *The aims of surgical procedures are to restore bone stock, the center of hip rotation, the offset, the leg length and to obtain optimal alignment of the implants.*
- *We used cementless implants associated to cryopreserved morselized cancellous bone allograft in the majority of the patients submitted to hip replacement prostheses.*

References

- Gross AE, Hutchison CR, Alexeeff M, Mahomed N, Leitch K, Morsi E. Proximal femoral allografts for reconstruction of bone stock in revision arthroplasty of the hip. *Clin Orthop* 1995;319:151-8.
- Head WC, Malinin TI, Mallory TH, Emerson RH Jr. Onlay cortical allografting for the femur. *Orthop Clin North Am* 1998;29:307-12.
- Judas F, Figueiredo MH, Cabrita AM, Proença A: Incorporation of impacted morselized bone allografts in rabbits. *Transplant Proc* 2005, 37(6):2802-4.
- Judas F, Teixeira L, Proença A: Coimbra University Hospitals' Bone and Tissue Bank: twenty-two years of experience. *Transplant Proc* 2005, 37(6):2799-801.
- Judas FJ, Dias RF, Lucas FM. A technique to remove a well-fixed titanium-coated RM acetabular cup in revision hip arthroplasty. Technical Note. *J Orthop Surg Res* 2011; 6 (1):31.
- Mitchell PA, Masri BA, Garbuz DS, Greidanus NV, Wilson D, Duncan CP: Removal of well-fixed, cementless, acetabular components in revision hip arthroplasty. *J Bone Joint Surg Br* 2003, 85(7):949-52.
- Proença A, Judas F, Cabral R, Canha N. Revision surgery of hip prosthesis. Osteolysis reconstruction with bone allografts. 1996 Orthopaedics Department of Coimbra University Hospitals.
- Rawal JS, Soler JA, Rhee JS, Dobson MH, Konan S, Haddad FS: Modification of the Explant System for the Removal of Well Fixed Hip Resurfacing Sockets. *J Arthroplasty* 2010, 25(7):1170, e7-9..
- Zmolek JC, Dorr LD. Revision total hip arthroplasty. The use of solid allograft. *J Arthroplasty* 1993;8:361-70.