

Seminario 1

Técnicas de ganglio centinela en el cáncer de mama

Moderador: Carlos Vázquez Albaladejo

Sentinel node in breast cancer. Preliminary results obtained at Gynaecology Department of the University Hospital of Coimbra

Vera Oliveira, Isabel Cruz, Paulo Correia, Natalia Amaral, Paula Lapa*, Sofia Oliveira*, Teresa Silva**, Maria Irene Martins**, João Pedroso de Lima* and Carlos Freire Oliveira

Gynaecology Department. *Nuclear Medicine Department. ** Pathology Department. University Hospital of Coimbra. Portugal.

Introduction. The identification and surgical removal of the sentinel node (SN) in the surgical treatment of breast cancer is a new technique that predicts the neoplastic invasion of the axillary nodes. Still in the experimental stage, it will allow avoiding axillary dissection in all patients with disease-free axilla.

Objectives. We will present the preliminary results obtained at the Gynaecology Department of the University Hospital Coimbra, in association with the Nuclear Medicine and Pathology Departments. Our work had two main objectives: first, to assess the ability to identify the SN using both a radioactive tracer (^{99m}Tc Nanocol) and a vital dye (Blue Dye); second, to be measure, by histological analysis of all axillary nodes, the extend to which the SN is a predictor of axillary node status.

Material and methods. We studied 44 patients with operable breast cancer, T1 or T2 and N0, with histological confirmation of malignancy through previous biopsy, from November 1999 to January 2002. In SN identification both a radioactive tracer (^{99m}Tc Nanocol) and a vital dye (Blue Dye) were used. The node(s) identified as SN were removed and sent to the Pathology Unit for an intraoperative frozen section analysis. In this prospective study, a complete axillary dissection was later performed in all patients.

Results. In 44 patients, identification of the SN by radioactivity and/or vital dye was possible in 38 (86.6%); of these in 34 (77.2%) a SN was isolated and sent for histopathological evaluation. The use of both techniques increases the rate of SN identification. Of the 34 patients in which a SN was identified and isolated, the specificity and positive predictive value were 100%; the sensitivity was 69.2% and the negative predictive value of SN was 84%.

Conclusion. Our small series of 44 women needs further investigation. Still at an experimental stage in our centre, the procedure will in the future reduce the need for axillary dissection in patients with disease free axilla.

INTRODUCTION

Currently, the treatment of operable invasive breast cancer demands complete axillary dissection. Axillary node invasion is the single most important prognostic factor, making it essential to assess for adjuvant therapy^{1,2}.

The identification and surgical removal of sentinel node (SN) in the surgical treatment of breast cancer is a new technique that forecasts the neoplastic involvement of axillary nodes. Still at an experimental stage, the procedure will in the future reduce the need for axillary dissection in patients with disease free axilla. This procedure arises from the need to abandon radical, mutilating surgery and replaced it by conservative, yet effective, disease controlling techniques^{1,4}.

The principle of sentinel lymph node (SN) biopsy is that the first lymph node to which the tumour drains is the site of the first lymphatic metastasis. Whether the sentinel node is involved or not should, therefore, reflect the status of the group of nodes; if the SN is positive, then axillary dissection can be performed; if it is negative the remaining nodes should also be uninvolved².

We will present the preliminary results obtained at the Gynaecology Department of the University Hospital Coimbra, in association with the Nuclear Medicine and Pathology Departments. Our work had two main objectives: first, to assess the ability to identify the SN using both a radioactive tracer (^{99m}Tc Nanocol) and a vital dye (Blue Dye); second, to measure, by histological analysis of all axillary nodes, the accuracy of SN predicting axillary node status.

MATERIAL AND METHODS

We studied 44 patients with operable breast cancer, T1 or T2 and N0, with histological confirmation of malignancy.

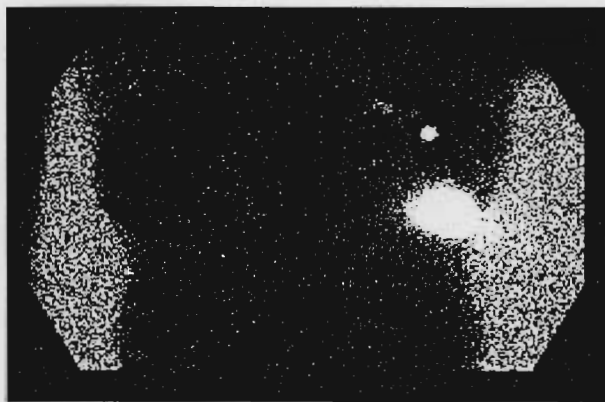

Fig. 1. Lymphocintigraphy.

nancy through previous biopsy, from November 1999 to January 2002. Pregnant women, patients with palpable axillary nodes, multifocal cancer or who had previously undergone chemotherapy, radiotherapy or surgery and patients with allergy to the radiopharmaceutical or the blue dye, were excluded.

The day before surgery, 74 MBq (2 mCi) of Technetium-99m-labelled human albumin colloid particles, in 0.2 ml, were administered with intra-tumoral injection. Planar scans of the involved breast and axillary area, both anterior and oblique projections, were acquired (fig. 1). The skin immediately above the first node that became radioactive was marked^{5,6}.

The following day, all patients were submitted to surgery. The surgical technique began with the peritumoral injection of 1 cc of Blue Dye (fig. 2). Next, a radio-guided probe, in a sterile glove, was slowly passed over the tumor and marked skin area to locate the sentinel node or nodes. A skin incision was performed above the tumor, following the lymphatic vessels dyed blue draining to the SN. The SN identified by radiation and/or blue dye is excised and sent to the Pathology Department for frozen section analysis^{2,7,8}. After that, complete axillary dissection is performed along with the previously planned surgical procedure.

RESULTS

Identification and isolation of the sentinel node

Of the 44 patients the lymphocintigraphy was positive in all but one who had a retroamillary carcinoma. During



Fig. 2. Peritumoral injection of 1 cc of Blue Dye.

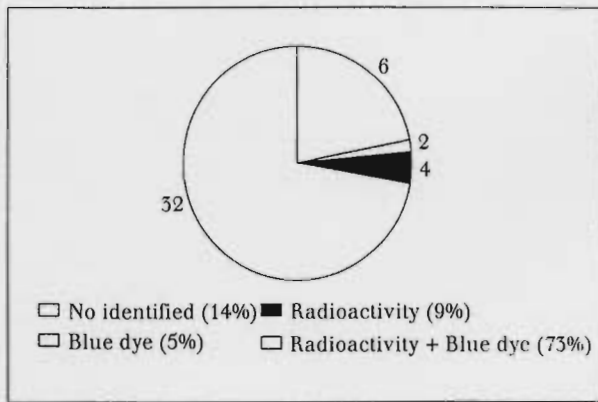


Fig. 3. Identification of the sentinel node.

surgery, the SN was identified by radioactivity and/or vital dye in 38 (86.6%) patients; these four (9%) were identified only by radioactivity and two (4.5%) only by the vital dye; six (13.6%) were not identified by any technique (fig. 3). Of the 38 patients in which a SN was identified, in three no node was found in the material sent for frozen section and in one the SN was sent along with the complete axillary dissection but not identified (fig. 4).

Predictive value of sentinel node in the axillary-node status

Of the 34 patients in which a SN was identified and isolated, frozen section was not performed in three cases; in these the final histopathological evaluation showed invasion in one patient (SN being the only one with neoplastic involvement). Of the 31 patients in which a SN was identified and a frozen section was performed, in eight (25.8%) the frozen section showed neoplastic cells, which were confirmed in the final histopathological evaluation; in 23 (74.2%) the frozen section showed no cancer cells. Of these, in four (17%) the final histopathological evaluation revealed micrometastasis, making these cases false negatives due to the frozen section technique; in other four (17%) patients the final histopathological evaluation confirmed the absence of malignant cells in the SN, although other nodes in the axilla were invaded. Of the remain 15 (76%) patients the absence of neoplastic involvement was confirmed by the histopathological evaluation of both the SN and the other nodes in the axilla.

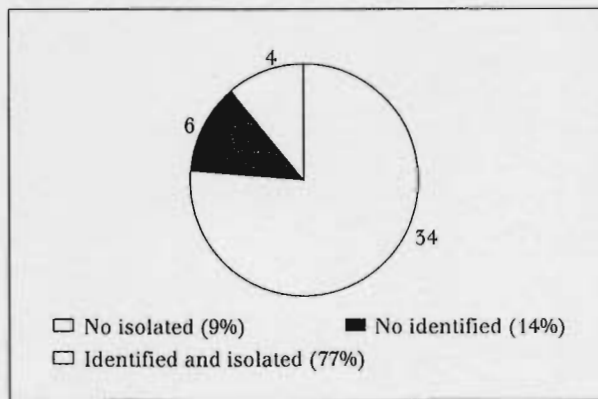


Fig. 4. Identification and isolation of the sentinel node.

DISCUSSION

Identification and isolation of the sentinel node

Of the 44 patients the SN was identified by radioactivity and/or vital dye in 38 (86.6%) patients; four (9%) were identified only by radioactivity and two (4.5%) only by the vital dye. The use of both techniques increase raises the rate of SN identification, as shown by our results. With the probe one can find a sentinel node in odd locations like the breast parenchyma. Such nodes are bound to be overlooked when only blue dye is used. With the probe one can identify the SN when the blue lymphatic duct is accidentally damaged and one loses the guiding track to the SN. On the other hand, the dye can help differentiate between first-echelon nodes and nodes with secondary drainage. This is useful when scintigraphy shows accumulation of the radiopharmaceutical in a multitude of nodes without indicating the drainage sequence. Blue dye does not only visualize the lymph node but also the lymphatic duct that comes from the direction of the primary tumour to SN.

Of the 38 patients in which a SN was identified, four were not isolated during surgery: in three no node was found in the material sent for frozen section (two samples contained only fat tissue and one was an acinar cyst) and in one the SN was sent along with the complete axillary dissection and not identified. In all these four patients the SN was identified by radioactivity and vital dye, and failure in excising it was probably due to technical inexperience of the surgeon. This difficulty happened mainly in the first 20 patients. The identification rate improved as the investigator became familiar with the nuances of the technique. All methods have a learning curve². However, with practice, the proportion of patients in whom the SN was identified and isolated increased.

Predictive value of sentinel node in the axillary-node status

The SN(s) was metastatic in 9 of the 34 patients with identifiable and isolated SN(s); in four patients, other axillary nodes were positive, whereas in the remaining five, the sentinel nodes were the only metastatic nodes. This finding indicates that the sentinel concept is biologically valid, and supports the argument for SN biopsy. Of the 25 patients in which the sentinel node was negative for neoplastic invasion, there were 4 false negatives, which showed 69.2% sensitivity and a positive predictive value of 84.0%. There were no false positives SN, so the specificity and positive predictive value was 100% (table 1).

We would like to emphasise your attention to the fact that the reliability of SN diagnosis on frozen sections may be questioned. Immediate and reliable intraoperative information on the condition of the sentinel node is vital for the technique's success, since the surgeon must decide whether or not to perform a total axillary dissection. We examined frozen sections of SN in 31 cases. In 27 (87%) of these cases, the intraoperative diagnosis was confirmed by the final histological examination. However, in four (13%) cases, the intraoperative diagnosis was falsely negative, because micrometastatic foci were subsequently identified on permanent sections. A patient whose SN was negative in frozen section but was positive on histology would require a further operation to clear the axilla, which would be likely to increase her distress. To help limit this distress, new techniques to improve the frozen-section were developed². Using a rapid cytokeratin

TABLE 1. Predictive value of SN in the axillary node status

	N+	N-	Total
T+	9	0	8
T-	4	21	25
Total	13	21	34

T+: positive SN; T-:negative SN; N+: positive axilla; N-: negative axilla.

immunocytochemical assay, micrometastases are more frequently revealed. In the future, all samples in which the frozen section proves negative will be tested with antibody MNF 116, an epithelial-cell specific antibody that allows more accurate detection of micrometastases.

CONCLUSION

There is no definite evidence that axillary surgery improves survival². Thus, the benefits and extent of axillary surgery must be counterbalanced by the complications of the procedure, particularly lymphoedema of the arm, neuropathy and restricted shoulder movement^{2,7,9,10}. This novel approach of lymphatic mapping with selective lymphadenectomy may lead to a substantial reduction of the need for axillary node dissection in patients with breast cancer, without compromising survival and regional control, and without loss of prognostic and staging information. This development will translate in a great reduction in patient morbidity and medical expenses. Our series of 44 women is still a small one and we need to extend the investigation. We hope that, with practice in a larger series of patients, we will be able to achieve an accuracy over 95% in predicting axillary node status. Still at an experimental stage in our centre, the procedure will in the future reduce the need for axillary dissection in patients with disease-free axilla.

References

- Veronesi U, Paganelli G, Galimberti, et al. Sentinel-node biopsy to avoid axillary dissection in breast cancer with clinically negative lymph nodes. *Lancet* 1997;349:1864-7.
- Lee AHS, Ellis IO, Pinder SE, et al. Pathological assessment of sentinel lymph node biopsies in patients with breast cancer. *Virchows Arch* 2000;436:97-101.
- Veronesi U, Paganelli G, Viale G, et al. Sentinel lymph node biopsy and axillary dissection in breast cancer results in a large series. *J Natl Cancer Inst* 1999;17;91(4):368-73.
- Veronesi U, Galimberti V, Zurrada S, et al. Sentinel lymph node biopsy as an indicator for axillary dissection in early breast cancer. *Eur J Cancer* 2001;37(4):454-8.
- Renato A, Valdés O, Liesbeth J, et al. Evaluation of mammary lymphoscintigraphy by a single intramural injection for sentinel node identification. *J Nuclear Med* 2000; 141(9).
- Rink T, Heuser T, Fitz H, et al. Lymphoscintigraphic Sentinel node imaging and gamma probe detection in breast cancer with Tc-99m nanocolloidal albumin: results of an optimized protocol. *Clin Nucl Med* 2001;26(4):293-8.
- Van Diest PJ, Torrens H, Borgstein PJ, et al. Reliability of intraoperative frozen section and imprint cytological investigation of sentinel lymph nodes in breast cancer *Histopathology* 1999;35:14-8.
- Giuliano AE, Jones RC, Brennan M, et al. Sentinel lymphadenectomy in breast cancer. *J Clin Oncol* 1997 (6):2345-50.
- Kissin MW, Querci della Rovere G, Easton D, et al. Risk of lymphoedema following the treatment of breast cancer. *Br J Surg* 1986;73:580-4.
- Stewart FW, Treve N. Lymphangiosarcoma in postmammectomy lymphoedema. *Cancer* 1948:1:64-81.