

Image in cardiology

Pulmonary Hypertension in Mitral Stenosis: An Optical Coherence Tomography Study

Hipertensión pulmonar en la estenosis mitral: un estudio de tomografía de coherencia óptica

Elisabete Jorge,^{a,b,*} João Calisto,^a and Henrique Faria^a

^a Serviço de Cardiologia, Hospitais da Universidade de Coimbra, Centro Hospitalar e Universitário de Coimbra, Portugal

^b Faculdade de Medicina, Universidade de Coimbra, Coimbra, Portugal

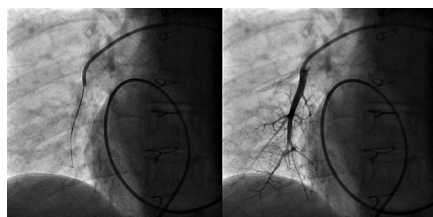


Figure 1.

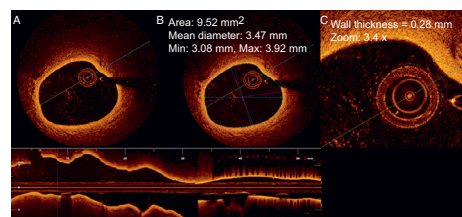


Figure 2.

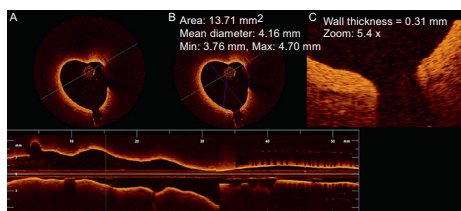


Figure 3.

A 65-year old woman with a prior history of surgical mitral commissurotomy 30 years ago presented with a 6-month history of worsening fatigue and exertional dyspnea. On physical examination, she had a mitral stenosis murmur, a loud P2, with an irregular pulse and mild peripheral edema. The electrocardiogram showed atrial fibrillation; the echocardiogram was notable for a fibro-calcified mitral valve, with severe restriction of leaflet mobility and an area of 1.1 cm². Biventricular function was normal.

As the valve anatomy was considered suitable for percutaneous intervention, the patient was scheduled a balloon valvuloplasty. The pre-intervention right heart catheterization showed a pulmonary artery pressure of 45/17/29 mmHg. After successful mitral dilatation, optical coherence tomography (LightLab Imaging Inc., Westford, Massachusetts, United States) was performed on a distal segmental branch of the right pulmonary artery (Fig. 1).

Optical coherence tomography images showed diffuse thickening of the distal pulmonary arterial wall (Figs. 2 and 3). We registered a pulmonary artery wall thickness between 0.28 mm and 0.31 mm, higher when compared to reports from subjects without pulmonary hypertension (0.16 [0.03] mm for vessels with 2.14 [0.33] mm of diameter). No complications arose during or after the procedure.

Optical coherence tomography is a safe and potentially useful tool for characterize, with high resolution, the pulmonary vessels and may contribute to investigate the mechanisms of vascular remodeling in pulmonary hypertension.

Acknowledgments: We are indebted to Mark Green, Paula Lopes, Cristina Silva, and Joana Ferreira.

CONFLICTS OF INTEREST

Dr Jorge received a research grant from St Jude Medical, Portugal.

SUPPLEMENTARY MATERIAL



Supplementary material associated with this article can be found in the online version available at <http://dx.doi.org/10.1016/j.rec.2013.06.019>.

* Corresponding author:.

E-mail address: elisabetejorge@gmail.com (E. Jorge).

Available online 26 October 2013