

# Retinal Thickness in Eyes With Mild Nonproliferative Retinopathy in Patients With Type 2 Diabetes Mellitus

## Comparison of Measurements Obtained by Retinal Thickness Analysis and Optical Coherence Tomography

Isabel Pires, MD; Rui C. Bernardes, MSc; Conceição L. Lobo, MD, PhD; Mário A. Soares, Tech; José G. Cunha-Vaz, MD, PhD

**Objective:** To compare measurements of retinal thickness in eyes with mild nonproliferative retinopathy in patients with type 2 diabetes mellitus using 2 different techniques: the retinal thickness analyzer (RTA) and optical coherence tomography (OCT).

**Methods:** Twenty-eight eyes from 28 patients with type 2 diabetes mellitus and mild nonproliferative retinopathy were classified according to the Wisconsin grading system by 7-field stereoscopic fundus photography. Ten eyes were classified as level 10 (absence of visible lesions) and 18 as level 20 or 35 (minimal retinopathy). All eyes were examined by the RTA and OCT. Healthy populations were used to establish reference maps for the RTA (n=14; mean age, 48 years; age range, 42-55 years) and OCT (n=10; mean age, 56 years; age range, 43-68 years). Reference maps were computed using the

means  $\pm 2$  SDs of the values obtained for each location. Increases in thickness were computed as a percentage of increase over these reference maps.

**Results:** The RTA detected increases in thickness in 1 or more locations in 24 of the 28 diabetic eyes examined, whereas OCT detected increases in only 3 eyes. The percentages of increase detected by the RTA ranged from 0.3% to 73.5%, whereas OCT detected percentages of increase of 0.3% to 4.8%.

**Conclusion:** Optical coherence tomography is less sensitive than the RTA in detecting localized increases in retinal thickness in the initial stages of diabetic retinal disease.

*Arch Ophthalmol.* 2002;120:1301-1306

From the Department of Ophthalmology, University Hospital of Coimbra (Drs Pires, Lobo, and Cunha-Vaz and Ms Soares), the Center of New Technologies for Medicine (Mr Bernardes and Dr Cunha-Vaz), Association for Biomedical Research and Innovation on Light and Image (Dr Cunha-Vaz), and the Institute of Biomedical Research on Light and Image, Faculty of Medicine, University of Coimbra (Drs Lobo and Cunha-Vaz), Coimbra, Portugal.

**D**IABETIC RETINOPATHY (DR) remains a leading cause of blindness in developed countries. Macular edema is a frequent alteration in type 2 diabetes mellitus and the most frequent cause of visual loss.<sup>1</sup> It has been considered to be mainly due to abnormal fluid accumulation resulting from a breakdown of the blood-retinal barrier.<sup>2</sup>

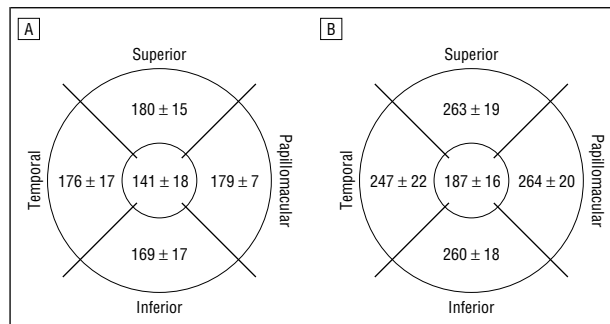
A definition of clinically significant macular edema (CSME) has been proposed by the Early Treatment Diabetic Retinopathy Study (ETDRS).<sup>3</sup> Current diagnostic methods for its detection and evaluation are slitlamp biomicroscopy (SLB) and stereoscopic fundus photography (SFP), providing a subjective evaluation of retinal thickness.

Detection of retinal thickening by means of SLB or SFP, however, seems to be associated with relatively low sensitivity. A study by Shahidi et al<sup>4</sup> using the retinal thickness analyzer (RTA) shows that SLB

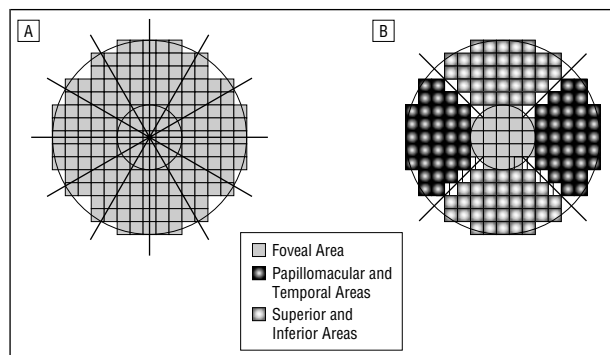
and SFP may detect increases in thickness only when they show values of more than 60% greater than the reference population and may, therefore, be unable to identify mild or localized macular thickening.

Improved detection of macular edema is expected to offer new perspectives for the follow-up and treatment of DR. The ETDRS, which is based on SLB and SFP findings, has demonstrated that photocoagulation for CSME only reduces the risk of moderate visual loss by approximately 50%.<sup>2</sup>

Optical imaging instruments, such as the RTA (Talia Technology Ltd, Mevaseret, Israel) and optical coherence tomography (OCT) (Zeiss Humphrey Systems, Dublin, Calif), have been proposed as powerful tools for the objective assessment of macular edema. It seems desirable to test these methods when minimal changes in retinal thickness may be present, when other methods cannot identify changes, and when visual acuity is not affected. Both techniques, which are capable of measuring retinal



**Figure 1.** Retinal thickness analyzer (A) and optical coherence tomography (B) reference maps from controls showing the mean  $\pm$ SD thickness values for each of the 5 areas of interest. Values are given in micrometers for a right eye. The 5 locations—the fovea (1000  $\mu$ m) and the papillomacular, superior, temporal, and inferior quadrants of the retina—were automatically measured and averaged.



**Figure 2.** A, Best fit between retinal thickness analyzer (RTA) and optical coherence tomography (OCT) measurements for the 5 locations of interest. Each square represents an area measuring 200  $\times$  200  $\mu$ m (RTA). Also shown are 2 concentric circles with 1000- and 3000- $\mu$ m radii, establishing the limits used by OCT. B, Locations of general RTA measurements vs OCT measurement lines.

thickness and rapidly generating thickness maps at the posterior pole,<sup>5,6</sup> are noninvasive and noncontact procedures.

We used the RTA and OCT to measure retinal thickness in the eyes of healthy volunteers and diabetic patients with minimal nonproliferative DR to compare both methods.

## METHODS

### PATIENTS

Twenty-eight patients (10 men and 18 women), aged 50 to 69 years (mean  $\pm$ SD age, 59.2  $\pm$  5.4 years), with an established diagnosis of type 2 diabetes mellitus were recruited to participate in this study. Duration of diabetes mellitus ranged from 1 to 20 years (mean  $\pm$ SD, 7.9  $\pm$  4.8 years), and glycosylated hemoglobin values ranged from 5.5% to 11.7% (mean  $\pm$ SD, 7.3%  $\pm$  1.5%). Blood pressure levels were 155/85 mm Hg or less.

All patients underwent a complete ophthalmologic examination, including the following assessments: corneal refractive power, refractive error and best-corrected visual acuity, intraocular pressure, SFP, and retinal thickness measurements obtained using both of the quantitative methods (the RTA and OCT). All eyes had a best-corrected visual acuity of 20/20, clear media, no neovascularization, and no CSME or previous laser treatment.

Fundus examination was performed by SLB using a +90-diopter (D) lens and a Goldmann contact lens and 7-field SFP obtained and classified by an independent grader (C.L.L.) ac-

ording to the criteria of the ETDRS protocol<sup>3</sup> without being aware of the RTA or OCT findings. Stereoscopic pairs of fields were obtained using a 30° fundus camera. Ten eyes were classified as level 10 (DR absent) and 18 as level 20 or 35 (microaneurysms only or mild nonproliferative DR, respectively). Only 1 eye of each patient was studied.

Retinal thickness was assessed after the clinical examination by using the RTA and OCT in a single session through a dilated pupil (minimum of 5-6 mm), with drops of 2.5% phenylephrine hydrochloride and 1% tropicamide, by an experienced examiner (M.A.S.) who was aware of the clinical findings. A single examination was performed using each method. Before the study, a full explanation of the procedure was given to all participants, and informed consent was obtained in all cases. Tenets of the Declaration of Helsinki were followed.

Two healthy populations volunteered to participate as age-matched control groups for the RTA (n = 14; mean age, 48 years; age range, 42-55 years) and OCT (n = 10; mean age, 56 years; age range, 43-68 years). All of the individuals in these 2 control groups underwent a complete ophthalmologic examination and had a best-corrected visual acuity of 20/20 OU (refraction was within 2 D of emmetropia), clear media, normal visual fields, and absence of optic disc or retinal abnormalities on fundus examination (performed by SLB using a Goldmann contact lens). Retinal thickness was measured in both eyes using the RTA and OCT by the same examiner through a dilated pupil. Only 1 eye from each volunteer was randomly selected to compute RTA and OCT reference maps, using the means  $\pm$  2 SDs. The following mean  $\pm$ SD results were obtained: for the RTA—central foveal thickness, 141  $\pm$  18  $\mu$ m; papillomacular area, 179  $\pm$  7  $\mu$ m; superior area, 180  $\pm$  15  $\mu$ m; temporal area, 176  $\pm$  17  $\mu$ m; and inferior area, 169  $\pm$  17  $\mu$ m; for OCT—central foveal thickness, 187  $\pm$  16  $\mu$ m; papillomacular area, 264  $\pm$  20  $\mu$ m; superior area, 263  $\pm$  19  $\mu$ m; temporal area, 247  $\pm$  22  $\mu$ m; and inferior area, 260  $\pm$  18  $\mu$ m (**Figure 1**).

### RETINAL THICKNESS ANALYZER

The RTA is a quantitative and reproducible method for evaluating retinal thickness.<sup>2,5,7-10</sup>

The principle of retinal thickness analysis is based on projecting a thin helium-neon laser (543-nm) slit obliquely on the retina and viewing it at an angle in a manner similar to SLB. The total area scanned with the RTA is 6000  $\times$  6000  $\mu$ m, with each pixel representing an area of 200  $\times$  200  $\mu$ m.

To compare RTA and OCT areas of thickness, a new thickness map for the RTA measurements was built. Considering the covered area for each single value of the RTA thickness map and the areas covered at the 5 different locations of the OCT map, a new thickness map of the RTA was computed. This map takes into account the values that best fit the locations covered by the OCT map (**Figure 2**). The software version used was the 2.11 with analysis 6.35 (Talia Technology Ltd).

### OPTICAL COHERENCE TOMOGRAPHY

Optical coherence tomography is a diagnostic technique that provides cross-sectional tomographs of the retinal structure in vivo in which optical interferometry is used to resolve the distances of reflective structures within the eye. It is analogous to ultrasound B-scan but with superior resolution—approximately 10  $\mu$ m in the retina.<sup>6,11-13</sup>

Data are displayed in 2 different manners: as a numeric report and as a false-color topographic map divided into 9 ETDRS-type regions. For each of these regions, an average retinal thickness is automatically computed. In the color-coded map, bright colors, such as red and white, correspond to optical reflectivity areas and dark colors, such as blue and black, indicate reflectivity areas.

Acquisition time is 1 second for each of the 6 radial lines needed for a complete topographic macular examination. Patient discomfort, however, is minimal.

The software version used was A6.2 (Zeiss Humphrey Systems).

### LOCATIONS FOR RETINAL THICKNESS MEASUREMENTS

The OCT scans were performed in the control and diabetic eyes using the 6-radial-lines pattern, each 3.45 mm long, passing through the center of fixation. The scanning protocol for retinal mapping was first proposed by Hee et al.<sup>6</sup> Each of the 6 tomograms (B-scans) was oriented along a line intersecting the central fovea and containing 100 equally spaced axial profiles (A-scans) of optical reflectivity.

For this study, 5 measurements of retinal thickness were considered. These 5 values were automatically obtained in 5 retinal locations within a circle: a central disc area of 1 mm in diameter, centered on the patient's fixation, which was assumed to correspond to the central fovea, and in a peripheral ring area, 3 mm in diameter, in 4 retinal quadrants—papillomacular, superior, temporal, and inferior (Figure 2).

The RTA scans were obtained from the same diabetic eyes by the same examiner (M.A.S.). Retinal thickness measurements made by the RTA, as previously stated, produce an output map in which each value covers an area of  $200 \times 200 \mu\text{m}$ . To compare the measurements made by the 2 instruments, a best-fit overlapping area of both measures was found (Figure 2). Figure 2 shows 2 concentric circles of 1000- and 3000- $\mu\text{m}$  radii. The shaded squares represent locations of RTA measurements to be considered for each of the 5 locations of the OCT measurements (Figure 2A) and the locations of general RTA measurements vs OCT line measurements (Figure 2B).

As a result, the central site of the OCT measures an area of  $0.79 \text{ mm}^2$ , and the RTA squares cover an area of  $0.84 \text{ mm}^2$ , which is the closest area possible, representing an increase of 6% in total area for this location. For the remaining locations (superior, inferior, papillomacular, and temporal), the process repeats, with the OCT covering an area of  $1.57 \text{ mm}^2$  and the RTA covering an area of  $1.40 \text{ mm}^2$  (12% more area covered by the OCT).

Although in the central area (1 mm in diameter) the information provided by each method can be assumed to be equally detailed in both methods, as we get away from the central fovea, the information provided by the RTA is more detailed than that given by OCT. Optical coherence tomography keeps its measurements along a line, not evaluating the thickness in the areas between the lines. As a result, 1.5 mm from the center of the fovea, that is, at the outer frontier of the 3-mm ring, the distances between OCT measurements (one line to the next) are larger than  $750 \mu\text{m}$ .

### DATA ANALYSIS

Retinal thickness maps of the eyes from diabetic patients under study were obtained using the RTA and OCT. Moreover, maps of increased thickness were computed by comparing the thickness values of the eyes under study with both reference maps (means + 2 SDs) established for the RTA and OCT using a reference population. Reproducibility data for the RTA and OCT can be found elsewhere.<sup>8,9,11,13-15</sup>

### RESULTS

The results are summarized in the **Table**. The RTA detected thickness increases in 24 of 28 patients, with values ranging from 0.3% to 73.5%. The RTA increased val-

ues were noted in at least 1 location in all level 10 patients, in 8 of 11 level 20 patients, and in 6 of 7 level 35 patients. Furthermore, increased thickness was detected in more than 1 location simultaneously in 18 patients, and 9 patients had increased thickness in all 5 locations examined. These 9 patients—3 graded as level 10 (patients 1, 3, and 7), 4 as level 20 (patients 11, 12, 15, and 19), and 2 as level 35 (patients 26 and 27)—seem to have a more diffuse type of macular thickening that may occur independently of the retinopathy photographic level. Four patients—3 graded as level 20 (patients 11, 15, and 19) and 1 as level 35 (patient 27)—had marked central foveal thickness (increases 20% higher than the reference values). No eye graded level 10 showed increases in retinal thickness higher than 20%. The Table shows that these large increases are accompanied by similar large increases in the 4 remaining areas.

Optical coherence tomography detected retinal thickness increases in 2 level 10 eyes (patients 3 and 7) and in 1 level 35 eye (patient 23) ranging from 0.3% to 4.8%, always located on the foveal area.

The RTA and OCT retinal thickness increases were the same in patients 3 and 7 in the central fovea. However, patient 19 showed a large increase in thickness as measured by the RTA in the foveal area (73.5%), whereas OCT detected no change. On the other hand, OCT detected an increase in central foveal thickness of 0.8% in patient 23, but the RTA did not show any increase.

Patients in this study showed acceptable glycosylated hemoglobin levels, with a mean value of 7.3%, indicating a general situation of relatively good metabolic control, with duration of diabetes mellitus ranging from 1 to 20 years (mean, 7.9 years). No direct correlation could be established between increases in retinal thickness and duration of disease or short-term status of metabolic control.

### COMMENT

Results of the present study show that localized areas of retinal edema, that is, areas of abnormal increase in retinal thickness, are occurring in the macula in the early stages of diabetic retinal disease. Localized areas of increased retinal thickness were identified by the RTA in 24 of the 28 eyes examined but by OCT in only 3 of the 28 eyes.

All 10 eyes with no visible retinopathy showed localized areas of abnormal increase with the RTA. Although the increases were minimal in 4 eyes, they were greater than the values of a reference population (means + 2 SDs). Optical coherence tomography detected increases in retinal thickness in only 2 of these eyes.

Of 18 eyes with mild nonproliferative retinopathy of level 20 or 35 using the Wisconsin grading, based on SFP, 14 showed localized areas of increased retinal thickness when using the RTA, whereas only 1 showed increased retinal thickness in the fovea using OCT. In this study, the RTA detects abnormal increases in retinal thickness in the diabetic retina before OCT. The results obtained using the RTA demonstrate that localized retinal edema is one of the earliest alterations occurring in the

**Retinal Thickness Increases Detected by OCT and the RTA in Patients With Diabetic Retinopathy\***

Patient No./Age, y/ Duration of DM, y	Glycosylated Hemoglobin, %	Eye	Wisconsin Grading Level	Retinal Thickness Increase, %									
				Foveal Area		Papillomacular Area		Superior Area		Temporal Area		Inferior Area	
				OCT	RTA	OCT	RTA	OCT	RTA	OCT	RTA	OCT	RTA
1/57/20	6.7	L	10	0.0	1.8	0.0	17.7	0.0	12.1	0.0	0.4	0.0	6.0
2/53/5	5.7	L	10	0.0	0.0	0.0	4.7	0.0	0.0	0.0	0.0	0.0	0.0
3/67/16	7.7	R	10	0.3	4.0	0.0	21.4	0.0	15.0	0.0	1.2	0.0	4.3
4/58/4	11.7	R	10	0.0	0.0	0.0	5.0	0.0	0.0	0.0	0.0	0.0	0.0
5/63/6	6.3	R	10	0.0	0.0	0.0	6.6	0.0	0.0	0.0	0.0	0.0	0.0
6/61/3	7.6	L	10	0.0	0.0	0.0	29.4	0.0	20.6	0.0	8.1	0.0	7.4
7/67/8	7.2	R	10	4.8	11.8	0.0	26.1	0.0	25.3	0.0	17.0	0.0	14.9
8/50/12	6.3	L	10	0.0	19.2	0.0	37.0	0.0	12.4	0.0	0.0	0.0	0.0
9/57/10	7.5	R	10	0.0	0.0	0.0	3.7	0.0	0.0	0.0	0.0	0.0	0.0
10/55/5	9.5	L	10	0.0	10.9	0.0	28.4	0.0	7.4	0.0	0.0	0.0	0.5
11/56/7	5.7	R	20	0.0	22.8	0.0	40.7	0.0	24.1	0.0	25.7	0.0	19.8
12/58/8	8.1	L	20	0.0	6.5	0.0	16.8	0.0	8.2	0.0	3.3	0.0	6.9
13/54/15	6.7	R	20	0.0	0.0	0.0	0.0	0.0	0.0	0.0	0.0	0.0	0.0
14/54/5	7.5	L	20	0.0	3.1	0.0	13.4	0.0	2.8	0.0	0.0	0.0	0.0
15/53/8	6.8	L	20	0.0	23.1	0.0	40.0	0.0	22.9	0.0	19.1	0.0	24.6
16/66/4	6.3	L	20	0.0	15.9	0.0	3.0	0.0	5.8	0.0	3.0	0.0	0.0
17/54/15	7.8	R	20	0.0	0.0	0.0	15.3	0.0	11.8	0.0	15.3	0.0	1.9
18/65/8	6.2	R	20	0.0	0.0	0.0	0.0	0.0	0.0	0.0	0.0	0.0	0.0
19/61/2	9.4	L	20	0.0	73.5	0.0	55.8	0.0	36.8	0.0	31.1	0.0	43.1
20/63/1	5.6	R	20	0.0	0.0	0.0	9.1	0.0	0.0	0.0	0.0	0.0	0.0
21/69/4	6.1	R	20	0.0	0.0	0.0	0.0	0.0	0.0	0.0	0.0	0.0	0.0
22/63/4	6.2	R	35	0.0	0.0	0.0	2.3	0.0	8.6	0.0	0.0	0.0	0.0
23/66/6	7.3	R	35	0.8	0.0	0.0	11.9	0.0	0.0	0.0	0.0	0.0	0.0
24/65/15	8.5	L	35	0.0	0.0	0.0	6.8	0.0	0.3	0.0	0.0	0.0	0.0
25/55/7	9.5	R	35	0.0	0.0	0.0	0.0	0.0	0.0	0.0	0.0	0.0	0.0
26/56/10	6.7	L	35	0.0	7.2	0.0	33.1	0.0	19.0	0.0	9.4	0.0	13.5
27/52/10	9.3	R	35	0.0	56.5	0.0	47.4	0.0	31.9	0.0	24.8	0.0	38.4
28/59/3	5.5	R	35	0.0	8.4	0.0	22.5	0.0	0.0	0.0	0.0	0.0	0.0

\*OCT indicates optical coherence tomography; RTA, retinal thickness analyzer; DM, diabetes mellitus; L, left; and R, right.

macula in eyes with type 2 diabetes mellitus. In this study, however, OCT did not show these areas of localized retinal edema. Hee et al,<sup>6</sup> using OCT for screening for macular edema, showed similar results. They detected increased foveal thickness in only 2 of 55 eyes from 31 patients who had no visible retinopathy.

The localized areas of retinal edema detected in the fovea by the RTA showed increases in retinal thickness that varied from 0.3% to 73.5% higher than the reference values for the respective area under evaluation. The highest increase in eyes with Wisconsin grading level 10 was 19.2%, whereas larger increases reaching 56.5% and 73.5% were detected in eyes graded as level 20 or 35. Although our results indicate that increases in retinal thickness are an early finding in diabetic retinas, they also show that more marked increases in retinal thickness are associated with progression of the retinal microvascular alterations. It is also shown in this study that the development of localized areas of retinal edema is not a constant finding, as 4 of 28 eyes remained edema free. No clear correlation was found in this study among duration of disease, level of metabolic control, and the presence of localized areas of retinal edema.

Evidence from previous studies by Lobo et al,<sup>16,17</sup> using integrated data obtained with the retinal leakage

analyzer and the RTA, indicates that 2 types of retinal edema may occur simultaneously in the earliest stages of diabetic retinal disease: retinal edema of the cytotoxic type, occurring independently of an associated breakdown of the blood-retinal barrier, and a vasogenic type of edema directly due to alteration of the blood-retinal barrier.

In a subsequent 1-year follow-up study<sup>17</sup> of eyes with minimal nonproliferative retinopathy in patients with type 2 diabetes mellitus, retinal edema was shown to be predominantly of the vasogenic type, that is, due to an alteration of the blood-retinal barrier. In that same study, the extent and height of the retinal edema did not correlate with the levels of metabolic control.

The reference values and SDs obtained by the RTA and OCT in the present study were similar to those reported in the literature. The central macular thickness in a similarly aged group examined by the RTA and OCT showed mean  $\pm$  SD values of  $141 \pm 18 \mu\text{m}$  and  $187 \pm 16 \mu\text{m}$ , respectively. None of the eyes included in this study had the characteristics of CSME, as described in the ETDRS, and all the diabetic patients had 20/20 visual acuity.

The absolute values of macular thickness quantified by the RTA and OCT are still uncertain because

comparison between the in vivo retinal thickness measurements and histologic analysis has not been conducted owing to the associated problems. In vitro retinal thickness measurements reported in the literature<sup>18,19</sup> establish a range of 100 to 130  $\mu\text{m}$  for the central foveal thickness.

Several authors have published different measures for foveal thickness using the RTA. Zeimer<sup>8</sup> stated a reference retinal thickness of 167  $\mu\text{m}$  in the fovea, with mean local variation of 23  $\mu\text{m}$ . Landau et al<sup>9</sup> make reference to 178  $\mu\text{m}$ . These authors used a previous software version in which the thickness was considered the distance between the sites of maximal steepness of the slit profile. Currently, the thickness is considered the distance between the peaks of 2 Lorentzian curves fitted to the slit profile.<sup>2</sup> Particular attention should be given to this fact when comparing different reference values, as not all authors make reference to the software versions used or the area covered in the "foveal area." Konno et al<sup>10</sup> used only the minimum value in field 5 of the thickness map and found a mean  $\pm$  SD retinal thickness of  $107 \pm 18.6 \mu\text{m}$  using software version 2.13 with analysis version 6.30. Neubauer et al,<sup>14</sup> using RTA software version 3 with analysis version 7.06, found a mean  $\pm$  SD value of  $181 \pm 17 \mu\text{m}$ . They also found a median of 150  $\mu\text{m}$ , which means that there is equal probability of finding higher and lower values from this mark.

For OCT, Hee et al<sup>6</sup> found a mean  $\pm$  SD retinal thickness of  $174 \pm 18 \mu\text{m}$  for the central 500  $\mu\text{m}$ . Konno et al<sup>10</sup> found a mean  $\pm$  SD value of  $155 \pm 15 \mu\text{m}$  using software version A4.01 and looking for "... the minimum value located near the center of the image." Massin et al<sup>15</sup> found a mean  $\pm$  SD value for a central area 1 mm in diameter centered on the fovea of  $178 \pm 17 \mu\text{m}$  using software version A5, which differs 9  $\mu\text{m}$  from our results. Finally, Neubauer et al<sup>14</sup> found a mean  $\pm$  SD value of  $153 \pm 16 \mu\text{m}$  using software version A4.1. Again, they found a median value of 150  $\mu\text{m}$ , the same median as they found for the RTA.

We established both reference populations in our site. If there is any difference in age-matched populations for the RTA and OCT, it would mean a disadvantage for the RTA because the RTA population is younger. Zeimer<sup>8</sup> states that there is a decrease of 5% per year in macular thickness.

Shahidi and associates,<sup>4</sup> using the RTA, reported that clinical examination with SLB permits detection of retinal thickness only when it is more than 60% greater than reference retinal thickness measurements. This is in agreement with our findings. In our study, involving patients who did not have CSME when examined by SLB and SPF disclosed values in this borderline range in the central foveal area in only 2 of the 28 eyes.

There are obvious differences in the technique producing the measurements and the thickness maps between the RTA and OCT. Whereas in the central foveal area the information provided by each method can be assumed to be equally detailed, as we get away from the central fovea, the information provided by the RTA is clearly more detailed than that given by OCT. Optical coherence tomography makes its measurements along lines, not evaluating the thick-

ness in the areas between the lines. This is shown in Figure 2.

In our clinical experience with these methods, another advantage of the RTA is its short acquisition time. The 200 milliseconds required for the scanning procedure are associated with less discomfort to the patient because of less prolonged light exposures. Also, with the RTA, it is easier for patients to maintain steady ocular fixation, and there are fewer problems associated with blinking. On the other hand, in more advanced stages of retinopathy, RTA results may be affected by irregular reflections from hard exudates accumulated in the retina and by the interference of media opacities such as severe cataract or vitreous opacities.

Comparing the 2 techniques to measure retinal thickness, the RTA seems to be particularly appropriate for measuring changes in retinal thickness when these changes are minimal, particularly in the initial stages of diabetic retinal disease and in eyes without media opacities and in the absence of morphologic retinal alterations, such as hard exudates. We consider the RTA to be a promising tool to evaluate quantitatively the changes in retinal thickness before the development of CSME, when an early therapeutic intervention may be more effective. In our experience, OCT is particularly informative when there are changes in the retinal architecture through the formation of cysts or localized fluid detachments. None of these situations were found in the eyes included in this study. Studies in progress performed by our group examining the presence of macular edema after cataract surgery indicate that OCT detects only abnormal retinal thickness values where there is some degree of visible fluid accumulation and cystlike formations are found in OCT cross sections.

In conclusion, localized areas of increased retinal thickness (ie, edema) occur in the retina in type 2 diabetes mellitus in the initial stages of retinopathy. These areas of localized retinal edema may be identified and quantified by the RTA, offering a unique opportunity to study the effects of early intervention in the evolution of diabetic retinal edema to prevent its progression to CSME.

*Submitted for publication December 11, 2001; final revision received June 25, 2002; accepted July 1, 2002.*

*Corresponding author and reprints: José G. Cunha-Vaz, MD, PhD, Department of Ophthalmology, University Hospital of Coimbra, Praceta Mota Pinto, 3000 Coimbra, Portugal (e-mail: cunhavaz@aibili.pt).*

## REFERENCES

1. Aiello L, Gardner T, King G, et al. Diabetic retinopathy. *Diabetes Care*. 1998;21:143-156.
2. Smith R, Lee C, Charles H, Farber M, Cunha-Vaz J. Quantification of diabetic macular edema. *Arch Ophthalmol*. 1987;105:218-222.
3. Early Treatment Diabetic Retinopathy Study Research Group. Photocoagulation for diabetic macular edema: Early Treatment Diabetic Retinopathy Study report number 1. *Arch Ophthalmol*. 1985;103:1796-1806.
4. Shahidi M, Ogura Y, Blair N, Rusin M, Zeimer R. Retinal thickness analysis for quantitative assessment of diabetic macular edema. *Arch Ophthalmol*. 1991;109:1115-1119.

5. Asrani S, Zeimer R, Goldberg M, Zou S. Application of rapid scanning retinal thickness analysis in retinal diseases. *Ophthalmology*. 1997;104:1145-1151.
6. Hee M, Puliafito C, Duker J, et al. Topography of diabetic macular edema with optical coherence tomography. *Ophthalmology*. 1998;105:360-370.
7. Zeimer R, Shahidi M, Mori M, Zou S, Asrani S. A new method for rapid mapping of the retinal thickness at the posterior pole. *Invest Ophthalmol Vis Sci*. 1996;37:1994-2001.
8. Zeimer R. Application of the retinal thickness analyzer to the diagnosis and management of ocular diseases. *Ophthalmol Clin North Am*. 1998;11:359-379.
9. Landau D, Schneidman E, Jacobovitz T, Rozenman Y. Quantitative in vivo retinal thickness measurements in healthy subjects. *Ophthalmology*. 1997;104:639-642.
10. Konno S, Akiba J, Yoshida A. Retinal thickness measurements with optical coherence tomography and the scanning retinal thickness analyzer. *Retina*. 2001;21:57-61.
11. Pedut-Kloizman T, Pakter H, Schuman J, Szwartz J, Hee M. Ophthalmic diagnosis using optical coherence tomography. *Ophthalmol Clin North Am*. 1998;11:465-486.
12. Hee M, Izatt J, Swanson E, et al. Optical coherence tomography of the human retina. *Arch Ophthalmol*. 1995;113:325-332.
13. Koozekanani D, Roberts C, Katz S, Herderick E. Intersession repeatability of macular thickness measurements with the Humphrey 2000 OCT. *Invest Ophthalmol Vis Sci*. 2000;41:1486-1491.
14. Neubauer A, Priglinger S, Ullrich S, et al. Comparison of foveal thickness measured with the retinal thickness analyzer and optical coherence tomography. *Retina*. 2001;21:596-601.
15. Massin P, Vicaute E, Haouchine B, Erginay A, Paques M, Gaudric A. Reproducibility of retinal mapping using optical coherence tomography. *Arch Ophthalmol*. 2001;119:1135-1142.
16. Lobo C, Bernardes R, Cunha-Vaz J. Alterations of the blood-retinal barrier and retinal thickness in preclinical retinopathy in subjects with type 2 diabetes. *Arch Ophthalmol*. 2000;118:1364-1369.
17. Lobo C, Bernardes R, Faria de Abreu J, Cunha-Vaz J. One-year follow-up of blood-retinal barrier and retinal thickness alterations in patients with type 2 diabetes mellitus and mild nonproliferative retinopathy. *Arch Ophthalmol*. 2001;119:1469-1474.
18. Straatsma B, Foos R, Spencer L. The retina: topography and clinical correlations. In: *Symposium on Retina and Retinal Surgery: Transactions of the New Orleans Academy of Ophthalmology*. St Louis, Mo: Mosby-Year Book Inc; 1969:1-26.
19. Hogan MJ, Alvarado JA, Weddel JE. *Histology of the Human Eye: An Atlas and Textbook*. Philadelphia, Pa: WB Saunders Co; 1971:490-492.

#### ARCHIVES Web Quiz Winner

**C**ongratulations to the winner of our February quiz, Luigi Capasso, MD, Il Università degli Studi di Napoli, Naples, Italy. The correct answer to our February challenge was calcium deposition. For a complete discussion of this case, see the Clinicopathologic Reports, Case Reports, and Small Case Series section in the March ARCHIVES (Pandey SK, Werner L, Apple DJ, Gravel J-P. Calcium precipitation on the optical surface of a foldable intraocular lens: a clinicopathological correlations. *Arch Ophthalmol*. 2002;120:391-393).

Be sure to visit the *Archives of Ophthalmology* World Wide Web site (<http://www.archophthalmol.com>) and try your hand at our Clinical Challenge Interactive Quiz. We invite visitors to make a diagnosis based on selected information from a case report or other feature scheduled to be published in the following month's print edition of the ARCHIVES. The first visitor to e-mail our Web editors with the correct answer will be recognized in the print journal and on our Web site and will also receive a free copy of the book *One Hundred Years of JAMA Landmark Articles*.



**Figure 2.** Photomicrograph of the explanted opacified Hydroview intraocular lens (Bausch & Lomb, Rochester, NY) showing the confluent deposits on the anterior optical surface. The polymethyl-methacrylate haptics are free of any deposits (original magnification  $\times 100$ ).