

## Sentinel lymph node sites in patients with primary cutaneous melanoma of the legs and feet

Ricardo Vieira<sup>1</sup>, João Duarte Freitas<sup>1</sup>, Raquel Cardoso<sup>1</sup>, Cândida Lourenço<sup>2</sup>, Hugo Duarte<sup>2</sup>, Ana Moreira<sup>2</sup>, Sofia Oliveira<sup>2</sup>, Filipa Vieira<sup>2</sup>, João Pedroso de Lima<sup>2</sup>, Américo Figueiredo<sup>1</sup>

Departments of <sup>1</sup>Dermatology and <sup>2</sup>Nuclear Medicine, University Hospital, Coimbra, Portugal.

**Key Words:** Inguinal lymph nodes. Popliteal lymph nodes. Sentinel lymph node biopsy. Lymphoscintigraphy. Cutaneous melanoma.

### ABSTRACT

The knowledge of lymphatic drainage patterns of the integument is useful to perform selective sentinel lymph node biopsies. The lower limbs appear to have more predictable drainage patterns than other anatomical sites. However, when the tumor is located in the leg or foot, the possible identification of popliteal lymph nodes or interval lymph nodes along the course of lymphatic vessels may generate some difficulties.

The aim of the present study was to determine the most frequent sites of regional lymphatic drainage in primary cutaneous melanoma of the legs and feet. Forty-eight patients with primary cutaneous melanoma of the legs or feet were submitted to lymphoscintigraphy by intradermal injection of 111 MBq of <sup>99m</sup>Tc-Nanocoll at the tumour site. The sentinel lymph nodes were identified and this procedure was followed by selective sentinel lymph node biopsy. The inguinal region can be considered a highly predictable site of drainage from melanomas located in the legs or feet, while the presence of popliteal sentinel lymph nodes is inconstant and unpredictable.

Lymphoscintigraphy is the standard procedure to identify sentinel lymph nodes in patients with melanoma of the skin. Combining dynamic and static images, this technique identifies the first lymph node(s)

to receive lymphatic flow from a certain region of the skin, after previous intradermal injection of a radio-labeled tracer. The procedure is safe, minimally invasive and respects the physiologic pathways of superficial lymphatic flow<sup>1</sup>.

Generically, the anatomy of superficial lymphatic vessels has plenty of variations, leading to unpredictable patterns of drainage<sup>2,3</sup>. Drainage to other basins than the expected and drainage to interval lymph nodes along the course of lymphatic vessels are relatively common events<sup>2-4</sup>. Despite these considerations, the integument of legs and feet seems to have a more predictable

### Correspondence:

Ricardo Vieira, M. D.  
Serviço de Dermatologia  
Hospitais da Universidade de Coimbra  
Praceta Mota Pinto  
3000-075 Coimbra  
Portugal.  
Tel.: (351) 239 400 420  
Fax: (351) 239 400 490  
E-mail: ricardo.vieira@portugalmail.pt

lymphatic drainage than other anatomical regions, such as the head, neck, trunk and even the upper limbs<sup>4</sup>. For the legs or feet, the predictable lymphatic basins are the groin or popliteal triangle, respectively.

The aim of this work was to study the lymphatic drainage from the skin of patients affected with primary cutaneous melanoma of the legs and feet, verifying the frequency of drainage to inguinal and popliteal lymph nodes.

#### MATERIAL AND METHODS

Forty-eight patients (41 females and 7 males) with primary cutaneous melanoma of the lower limbs (17 patients with melanoma of the legs and 31 patients with melanoma of the feet) were submitted to lymphoscintigraphy to identify the sentinel lymph nodes. All patients had former clinical indications to perform this procedure (Breslow index  $\geq 1.0$ , Clark level  $\geq$  III or ulcerated tumours) and none had clinical or ultrasonographic lymph node metastases or lymphatic abnormalities, as lymphoedema.

All patients were subcutaneously injected at tumor site with 111 MBq of <sup>99m</sup>Tc-Nanocoll. Dynamic lymphoscintigraphic images were obtained during the first 20 minutes. Static images were obtained at 30 and 120 minutes, respectively (Figs. 1 and 2). Lymph nodes receiving the radio-labelled tracer from different anatomical regions of the leg and foot were identified.

The procedure was performed after proper informed consent given by each patient, and was followed by selective sentinel lymph node biopsy.

#### RESULTS

Drainage to inguinal lymph nodes was observed in all patients (100%). Popliteal lymph nodes were identified in only 2

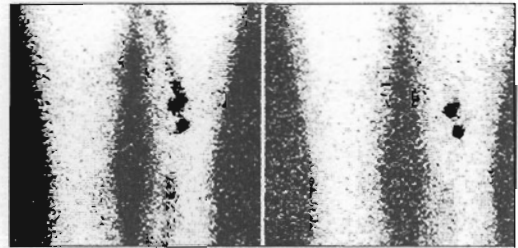


Fig. 1 - Detection of a popliteal sentinel lymph node: static lymphoscintigraphic images at 30 and 120 minutes.

(11.8%) of 17 patients with melanoma of the legs and 3 (9.7%) of 31 patients with melanoma of the feet. That corresponds to a total of 5 identifications of popliteal lymph nodes over a total number of 48 patients, resulting in a rate of 10.4%. No interval sentinel lymph nodes were identified.

The sites of lymphatic drainage by each anatomical region of leg and foot are described in Table I.

#### CONCLUSION

Inguinal lymph nodes seem to have a central role in superficial lymphatic drainage from the legs and feet, since they received afferent lymphatic vessels proceeding directly from the integument in a predictable pattern (100% of cases). Previous

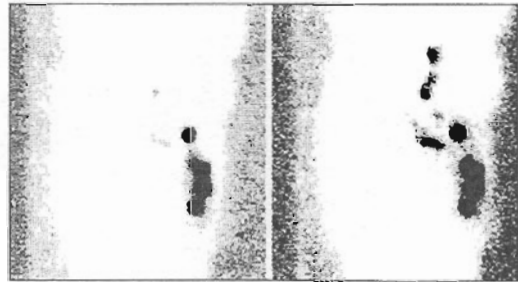


Fig. 2 - Detection of an inguinal sentinel lymph node: static lymphoscintigraphic images at 30 and 120 minutes.

**TABLE I**  
**Location of Sentinel Lymph Node(s) for Each Region of the Leg and Foot**

Site of injection of radio-labelled tracer	No. of cases	Sentinel lymph node	
		Popliteal node(s)	Superficial node(s) of the groin
Anteromedial aspect of the leg	6	1	6
Anterolateral aspect of the leg	2	0	2
Posterior aspect of the leg	9	1	9
Dorsal aspect of the foot	2	0	2
Plantar aspect of the foot	10	0	10
Calcaneus	7	1	7
Medial border of the foot	2	0	2
Lateral border of the foot	3	1	3
Toes	7	1	7
<b>TOTAL</b>	<b>48</b>	<b>5 (10.4%)</b>	<b>48 (100%)</b>

reports also support this consideration<sup>4-6</sup>. Conversely, drainage to popliteal lymph nodes was inconstant and the presence of anatomical variations, like interval lymph nodes, is irrelevant. The different regions considered in the leg or foot apparently demonstrated no predictive value over lymphatic drainage patterns.

The detection of popliteal sentinel lymph nodes in only 10.4% of cases can be compared with previously published smaller series that identified five of 14 patients (36%) with melanoma of the lower leg having popliteal sentinel lymph nodes<sup>5</sup>. Another paper in a very small group of three patients<sup>6</sup>, studied the lymphatic drainage from the integument of the legs and feet, finding a constant drainage to inguinal lymph nodes and no drainage to popliteal lymph nodes.

In conclusion, melanomas of the legs or feet always have sentinel lymph node(s) in the groin. Despite the inconstant identification of popliteal sentinel lymph node(s), the

occurrence of metastases in that lymphatic basin cannot be forgotten. Thus, good sense clearly recommends the performance of sentinel lymph node biopsy if a popliteal lymph node is identified by lymphoscintigraphy.

#### References

1. Pecking AP, Desprez-Curely JP, Cluzan RV. Tests and imaging of the lymphatic system. *Rev Med Interne* 2002;23:391-397.
2. Uren RF, Howman-Giles R, Thompson JF. Patterns of lymphatic drainage from the skin in patients with melanoma. *J Nucl Med* 2003;44:570-582.
3. Uren RF. Lymphatic drainage of the skin. *Ann Surg Oncol* 2004;11:179-85.
4. Stadius Muller MG, Hennipman FA, van Leeuwen PA, et al. Unpredictability of lymphatic drainage patterns in melanoma patients. *Eur J Nucl Med Mol Imaging* 2002;29:255-261.
5. Hatta N, Morita R, Yamada M, et al. Implications of popliteal lymph node detected by sentinel lymph node biopsy. *Dermatol Surg* 2005;31:327-330.
6. Aas M, Skretting A, Engeset A, et al. Lymphatic drainage from subcutaneous tissue in the foot and leg in the sitting human. *Acta Physiol Scand* 1985;125:505-511.