

Sentinel lymph node biopsy for melanoma Experience of 100 cases

Raquel Cardoso¹, Ricardo Vieira¹, Rosa Mascarenhas¹, Carlos Monteiro¹, Henrique Oliveira¹, João Duarte Freitas¹, Oscar Tellechea¹, M. Marques², Cândida Lourenço³, Hugo Duarte², João Pedroso Lima³, Maria José Julião⁴ and A. Figueiredo¹

Departments of ¹Dermatology, ²Statistics, ³Nuclear Medicine and ⁴Pathology, University Hospital, Coimbra, Portugal.

Key Words: Sentinel lymph node biopsy. Lymphoscintigraphy. Cutaneous melanoma.

ABSTRACT

The main aim of this study was to evaluate the clinical outcome of patients submitted to sentinel lymph node biopsy for melanoma. Another objective was to examine the procedure itself concerning morbidity and percentage of sentinel lymph nodes removed. One hundred patients underwent pre-operative lymphoscintigraphy to determine sentinel lymph nodes. During surgery, intra-operative gamma probe evaluation, along with isosulfan blue dye injection around the tumour, allowed their identification and removal.

Sentinel lymph node biopsy is a safe, low morbidity technique that could probably play a role in the early detection of sub clinical metastases, although the argument about its influence in what concerns the patients' overall survival persists.

Sentinel lymph node biopsy (SLNB) was initially performed in parotid carcinoma to detect lymph node metastases^{1,2}. Later, it was also developed for breast carcinoma and melanoma²⁻⁴. In 1992, Morton *et al.* published their results about the utility of sentinel lymph node (SLN) biopsy for patients with melanoma without regional and distant metastases⁴. They considered the presence of a melanoma lymph node

sequence spread and defined sentinel node as "the node most likely to contain metastatic melanoma"⁴. Nevertheless, lymph drainage does not always follow that pattern, as multiple sentinel lymph nodes may be present, an occult sentinel node may be missed or aberrant drainage could be real^{5,6}.

Sentinel lymph node biopsy allows early identification of occult metastases and selects specific patients for regional lymphadenectomy, which may have a beneficial outcome^{1,4}.

Correspondence:

Raquel Cardoso, M.D.
Serviço de Dermatologia
Hospitais da Universidade de Coimbra
Praça Professor Mota Pinto
3000 - 075 Coimbra
Portugal.
Tel: (351) 239 400 420
Fax: (351) 239 400 490
E-mail: raquel.tavares.cardoso@iol.pt

MATERIAL AND METHODS

From April 2000 through July 2004, in our Department of Dermatology, 100 patients were examined with AJCC (American Joint Committee on Cancer Staging System)

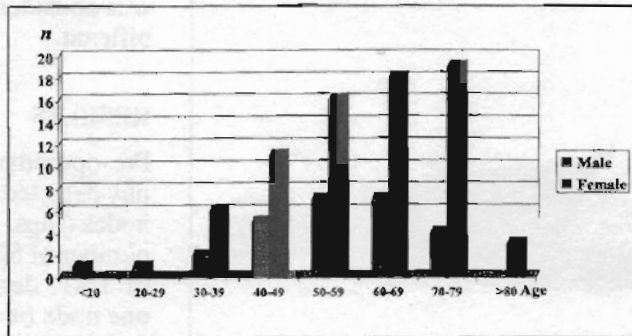


Fig. 1 - Distribution of age and gender of patients.

stage I or II cutaneous malignant melanoma, for assessment of possible lymph node metastases by means of sentinel lymph node biopsy.

The inclusion criteria for sentinel lymph node biopsy were Breslow's tumour thickness over 1mm, or less if there was ulceration or regression, and Clark's level equal to or over III. Exclusion criteria included regional and distant metastases, lymph drainage anomalies, or if the lesion had already been submitted to wide excision, or if a flap reconstruction had been performed.

The series included 27 males and 73 females, whose mean ages were 54.2 and 60.8 years, respectively (range 18 to 85), (Fig. 1).

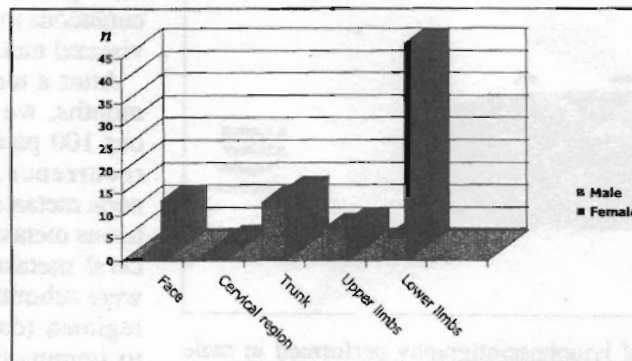


Fig. 2 - Anatomical location of melanomas.

The primary lesions were most commonly located on the trunk (51.8%) in male patients and on the extremities (58.9%) in female patients, followed by the face (13.7%) and trunk (13.7%) (Fig. 2).

The dominant histological types were superficial spreading and nodular melanoma, in both subsets. The mean Breslow thickness was 3.46mm and 3mm in the male and female groups, respectively. Twenty-one per cent of patients had melanoma thickness lower than or equal to 1mm; 54% had thickness between 1.01mm and 4mm; and 25% had thickness over 4mm. Fifty-three patients were on AJCC stage I and 47 on stage II.

The selected patients underwent pre-operative lymphoscintigraphy (12 to 24 hours before surgery). For the procedure, 2ml to 3ml of 37 MBq of technetium 99m-nanocolloid were injected intradermally around the tumour or biopsy scar, and dynamic and static imaging were performed on the lymph node regions involved to locate the SLNs. Before surgery, 1ml to 2ml of patent blue V was injected intradermally around the tumour or excision scar. Tracer counts of the lymph node basins were measured, with a gamma probe, and a local incision was made. This procedure along with the aid of patent blue allows the clear identification of the SLNs. All blue-stained and radioactive lymph nodes were excised. The background activity afterwards was lower than 10% of the hottest lymph node detected. Then, we proceeded to wide excision of the primary tumour site. The safety margins were related with tumour thickness: 3cm for tumours over 4mm; 2cm for tumours between 1.01mm and

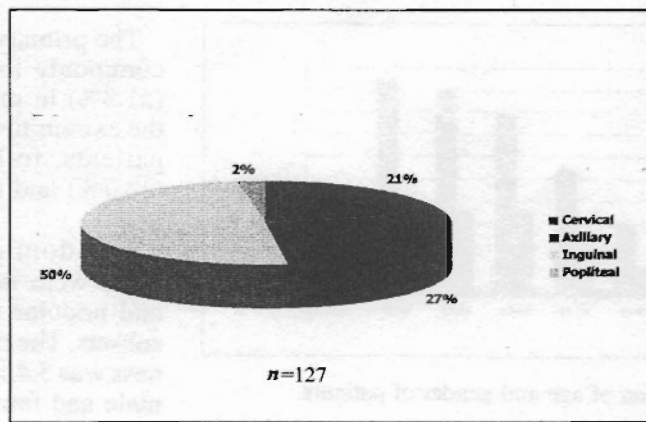


Fig. 3 - Results of lymphoscintigraphy performed in female patients.

4.0mm; and 1cm for tumours equal to or smaller than 1mm.

The SLNs were serially sectioned and evaluated with haematoxylin-eosin staining and immunohistochemistry (HMB-45, S-100). If there were metastases, the patient was submitted to regional lymph node excision and, eventually, to adjuvant therapy. All the patients were scheduled for follow-up visits.

Descriptive statistics and Mann-Whitney and chi-square tests were applied to the results obtained. A *p*-value lower than 0.05

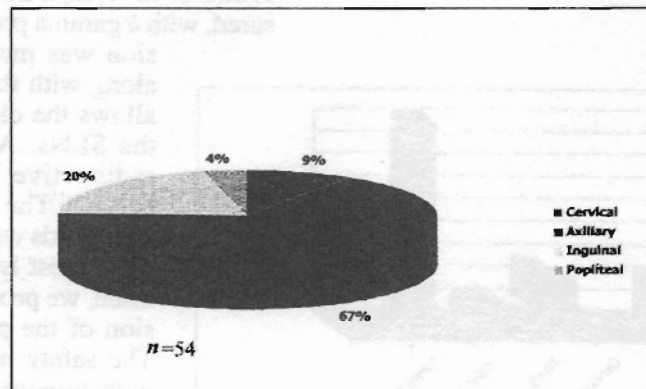


Fig. 4 - Results of lymphoscintigraphy performed in male patients.

was considered statistically significant.

RESULTS

Pre-operative lymphoscintigraphy detected 181 sentinel lymph nodes (Figs. 3 and 4). The mean number of SLNs per patient was of 1.81, detection being from one node ($n = 54$), two nodes ($n = 24$), three nodes ($n = 16$), to four or more nodes ($n = 6$). A total of 151 nodes were excised (83.4%), 102 of which were dyed. Forty-nine nodes were only identified by gamma probe.

Two patients presented surgical complications, namely seroma of the sentinel lymph node biopsy wounds.

Eighteen lymph nodes from 15 patients had metastases (11.9%). In these cases, the patients were submitted to lymphadenectomy. Afterwards, with a mean follow-up of 12.5 months, two patients developed local recurrence, five had cutaneous metastases and five had visceral metastases. Three of the 15 patients with positive nodes were free of disease at a mean follow-up of 23.6 months.

Thirteen patients with negative sentinel lymph nodes, later developed local recurrence ($n = 2$), regional metastases ($n = 6$), cutaneous metastases ($n = 2$) and visceral metastases ($n = 8$).

After a mean follow-up of 22 months, we verified that, from our 100 patients, five had local recurrence, eight had lymph node metastases, seven had cutaneous metastases and 13 had visceral metastases. Nine patients were submitted to chemotherapy regimen (dacarbazine) and two to immunotherapy (interferon). Eight patients were lost to fol-

TABLE I
Correlation between Breslow Thickness and Patients' Gender

Mean thickness	Gender
3.46mm	Males
3.00mm	Females

$p = 0.965$

TABLE II
Correlation between SLN Histology and Breslow Thickness

Histology	Mean thickness
Positive SLN	4.8mm - SD: 4.0
Negative SLN	2.7mm - SD: 2.5

$p = 0.011$

SD = standard deviation

TABLE III
Correlation between Breslow Thickness and Visceral Metastases

Mean thickness	Visceral metastases
5.23mm - SD: 4.5	Presence
2.84mm - SD: 2.5	Absence

$p = 0.018$

SD = standard deviation

TABLE IV
Correlation between SLN Histology and Visceral Metastases

Histology	Visceral metastases
Positive SLN	5
Negative SLN	8

$p = 0.024$

Odds ratio = 4.8

TABLE V
Correlation between Negative SLN and Regional Metastases

Negative SLN	Regional metastases
6	Presence
79	Absence

$p = 0.024$

Odds ratio = 4.8

low-up. Six patients died and only one of them had a positive sentinel lymph node.

There was no statistically significant correlation between gender and tumour thickness ($p = 0.965$) (Table I). There was higher probability of having a positive sentinel lymph node and visceral metastases if the tumour was thicker ($p = 0.011$ and $p = 0.018$, respectively) (Tables II and III). There was almost a fivefold probability of having visceral metastases if the sentinel lymph node was positive ($p = 0.024$) (Table IV). Seven per cent of the patients with negative sentinel lymph nodes developed regional lymph node metastases (Table V).

CONCLUSION

The percentage of missed sentinel lymph nodes (16.5%) is specially correlated with the initial difficulties of the technique (learning curve). The location of tumours on the head or neck also contributed, due to the proximity between the tumoural lesion and the sentinel lymph node and misleading radioactive counts. In those cases, we preferred to remove the melanoma first and afterwards proceed with the sentinel lymph node biopsy.

Sentinel lymph node biopsy is a low morbidity technique, as we found in our series. It has a role in the risk stratification, although the small sample, the short follow-

-up and absence of a control group do not allow us to conclude about survival improvement.

References

1. Gould EA, Winship T, Philbin PH, et al. Observations on a "sentinel node" in cancer of the parotid. *Cancer* 1960;13:77-78.
2. Malcolm RK, Michael JK. Sentinel lymph node biopsy is now an established and widely available technique for breast cancer and melanoma. *BMJ* 2004;328:1330-1331.
3. Cabanas RM. An approach for the treatment of penile carcinoma. *Cancer* 1977;39:456-466.
4. Morton DL, Wen DR, Wong JH, et al. Technical details of intraoperative lymphatic mapping for early-stage melanoma. *Arch Surg* 1992;127:392-399.
5. Daiel GC. The "true" sentinel lymph node: In search of an operational definition of a biological phenomenon. *Ann Surg Oncol* 2001;8:187-189.
6. Boán JF, Garcia-Veloso MJ, Richter JA. The role of sentinel lymph node biopsy in patients with cutaneous melanoma. *Skin Cancer* 2004;19:205-218.