

Primary peritoneal borderline tumour: report of an unusual case

D. Couto¹, M.D.; F. Mota¹, M.D., Ph.D.; T. Silva², M.D.; C. de Oliveira¹, M.D., Ph.D.

¹Department of Gynaecology; ²Department of Pathology; University Hospital of Coimbra (Portugal)

Summary

Primary peritoneal borderline tumour is a rare lesion, histologically indistinguishable from non-invasive peritoneal implants found in association with ovarian tumours of borderline malignancy.

We report a case of a primary peritoneal borderline tumour diagnosed in a 30-year-old patient with pelvic pain, infertility and elevated serum CA-125.

Key words: Primary peritoneal borderline tumour; Endosalpingiosis.

Introduction

Non-invasive peritoneal implants are present in 20 to 46% of women with ovarian serous borderline tumours [1]. When identical peritoneal lesions are rarely found in the absence of ovarian pathology, in the presence of minimal ovarian involvement or in association with benign ovarian tumour, they are being referred to as peritoneal tumours of borderline malignancy [2, 3], atypical endosalpingiosis [4] or peritoneal serous micropapillomatosis of low malignant potential [5].

We report a case of a primary peritoneal borderline tumour diagnosed in a 30-year-old woman together with a review of the literature.

Case Report

CAFA, a 30-year-old, multiparous, mediterranean woman, presented with infertility and pelvic pain.

Menarche occurred at the age of 12 years. She had been on oral hormonal contraception for ten years and then used an intrauterine device for two years. She had had a vaginal term delivery six years before and a spontaneous miscarriage one year later. She had again been trying to get pregnant for a year.

Her grandmother underwent a mastectomy for breast cancer and her father died from a cancer of the pancreas.

Ultrasound examination showed a pelvic cystic mass of 6.6 x 4.3 cm (Figure 1). The CA-125 serum level was 91 U/ml.

At laparoscopy there were extensive peritoneal exophytic lesions involving the uterus, fallopian tubes, both ovaries and cul-de-sac of Douglas (Figure 2).

The patient underwent a laparotomy with a left salpingo-oophorectomy. On frozen section the diagnosis of a borderline tumour was made and she underwent a total hysterectomy and right salpingo-oophorectomy with multiple peritoneal biopsies.

Pathologic Findings

Gross pathology

The hysterectomy specimen showed irregularity of the serosal surface, punctuate with micro nodules 1 to 2 mm in diameter, the largest on the isthmus measuring 1 cm (Figure 3).

Both ovaries adhered to the tubes and had multiple vegetations on the surface. The left ovary measured 6 x 5 x 3 cm and was multicystic. The cysts, 1 to 2 cm in diameter, had a smooth wall where they adhered to the tube. There were also small cysts filled with vegetations and calcifications. The right ovary measured 3.5 x 3 cm and had similar features.

Histological findings

The peritoneal lesions consisted essentially of micropapillary clusters of serous epithelial cells contained in small cystic spaces lined by invaginated mesothelial cells with abundant psammoma bodies; some lesions had a "burned out appearance" – peritoneal endosalpingiosis (Figure 4).

Focally, there were larger papillary processes with more complex branching. The degree of nuclear atypia was slight to moderate and mitoses were rare. All lesions were superficial and non-invasive, some epithelial, others desmoplastic (Figure 5).

Involvement of the ovarian surface was secondary and the ovarian cysts consisted of multiple follicular cysts and a small cystadenoma (Figure 6).

The final diagnosis was "serous borderline tumour of the peritoneum" and this prompted a second laparotomy with surgical removal of all visible peritoneal lesions. All lesions were superficial and non-invasive.

Discussion

Primary neoplasms of the female peritoneum may be mesothelial or mullerian in nature. The concept of primary mullerian tumours is based on the putative existence of a secondary mullerian system. The mullerian system is derived embryologically from the coelomic epithelium and subcoelomic mesenchyme. The adult derivatives of these structures – the surface epithelium of the ovary and the peritoneum – retain a potential for mullerian differentiation, developing tumours that can be benign, of borderline malignancy or malignant [6].

Revised manuscript accepted for publication October 5, 2006

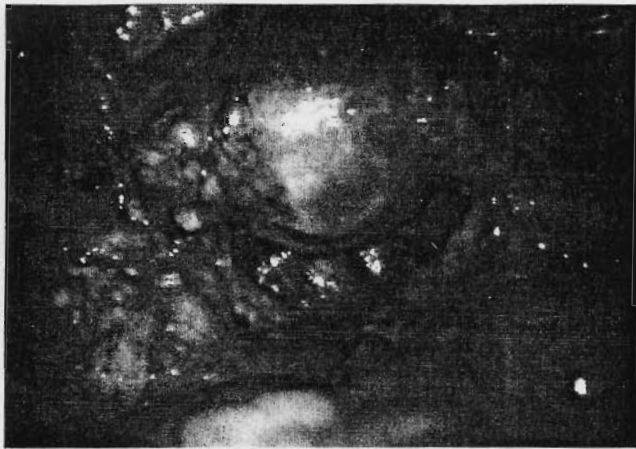
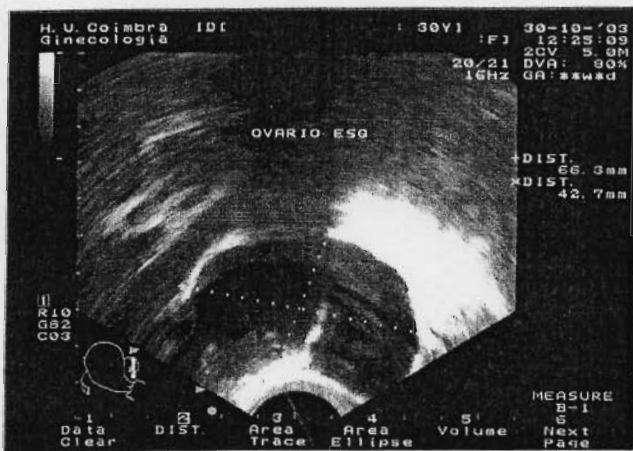


Fig. 2

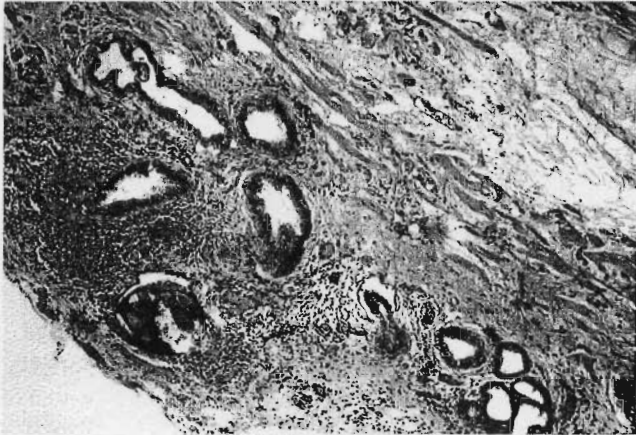
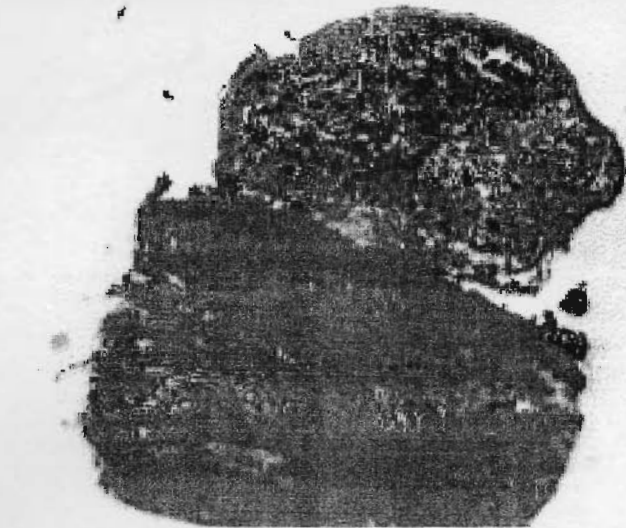


Fig. 4

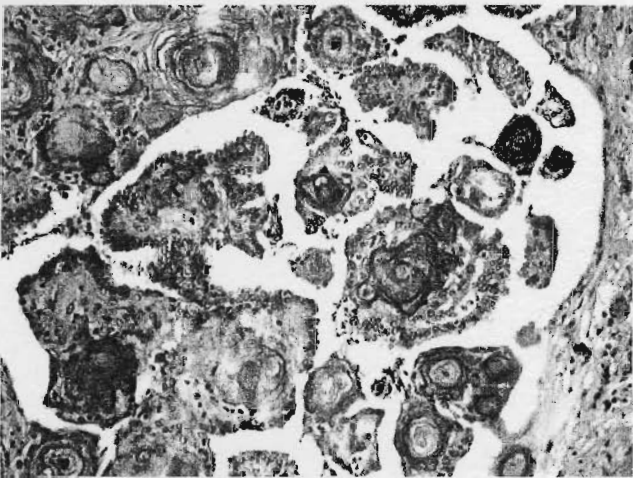


Fig. 6

- Figure 1. — Pelvic cystic mass 6.6 x 4.3 cm in diameter.
- Figure 2. — Peritoneal lesions involving the uterus, fallopian tubes, both ovaries and Douglas pouch at laparoscopy.
- Figure 3. — Nodule on the serosal surface of the uterus.
- Figure 4. — Endosalpingiosis lesion.
- Figure 5. — Serous proliferative tumour with multiple calcifications.
- Figure 6. — Tumoural and endosalpingiosis lesions on the ovarian surface.

The recognition of a primary peritoneal tumour of borderline malignancy relies on the presence of either normal ovaries, ovaries containing a benign tumour or ovaries showing only minimal surface involvement (8).

Only two large series of such lesions have been reported. Bell and Scully [3] analysed 25 cases they designated "serous borderline tumours of peritoneum". Biscotti *et al.* [5] studied 17 cases they reported as "peritoneal serous micropapillomatosis of low malignant potential".

These lesions are invariably extensive and are thought to develop from a pre-existing endosalpingiosis which is present in 70-80% of cases [3, 5]. Endosalpingiosis is a metaplastic lesion in the peritoneal cavity and is a precursor for primary peritoneal serous tumours [7]. Psammoma bodies are often associated [3, 5].

Patients with peritoneal borderline tumours are usually under the age of 40 years, although there have been cases reported in postmenopausal women [3, 5].

The risk factors for developing these tumours are not well known. Nulliparity, infertility and use of infertility drugs appear to increase the risk, while pregnancy, breastfeeding and oral contraceptives seem to have a protective effect [9, 10]. The condition does not have an association with hereditary ovarian cancers [10].

The lesions are usually asymptomatic, with incidental findings at laparotomy, but some have been associated with infertility, abdominal or pelvic pain, small bowel obstruction or amenorrhea [3, 5, 10].

Primary peritoneal borderline tumours macroscopically consist of multiple granules in the peritoneum or omentum, often with multiple adhesions associated. Histologically, they are non-invasive lesions and can be epithelial, desmoplastic or mixed (6).

Regarding the treatment, a conservative surgical approach is possible with preservation of the uterus and ovaries in young women, once the presence of an associated primary ovarian tumour has been excluded. In older women all visible lesions should be removed, as long as this does not imply removal of major organs, because of the risk of recurrence or transformation to low-grade carcinoma. Adjuvant therapy is not indicated [3, 5, 8].

The prognosis for patients with peritoneal borderline tumours is very good [3, 5] with a 95% survival rate similar to the survival reported for women with ovarian

serous borderline tumours and non-invasive peritoneal implants [6]. Of the 25 cases studied by Bell and Scully [3], 21, including eight who had been treated conservatively, were alive without recurrence 4.7 to 11.5 years post-operatively. Biscotti *et al.* [5] reported that two (14%) out of 17 cases had recurrent disease six months and 14.5 years after initial surgery. At the time the study was published, they were both alive 10.9 and 16.2 years after the first surgery. However, a small proportion of patients with residual disease may develop small bowel obstruction [5].

Close follow-up is recommended regardless of the extent of the surgical therapy [5].

References

- [1] Hart W.R.: "Pathology of malignant and borderline epithelial tumors of ovary". In: Coppleson M. (ed.), *Gynecologic Oncology. Fundamental Principles and Clinical Practice*; vol. 2, New York, Churchill-Livingstone, 1981, 633.
- [2] Bell D.A., Scully R.E.: "Benign and borderline serous lesions of the peritoneum in women". *Pathol. Ann.*, 1989, 24, 1.
- [3] Bell D.A., Scully R.E.: "Serous borderline tumors of the peritoneum". *Am. J. Surg. Pathol.*, 1990, 14, 230.
- [4] Zinsser K.R., Wheeler J.E.: "Endosalpingiosis in the omentum: a study of autopsy and surgical material". *Am. J. Surg. Pathol.*, 1982, 6, 109.
- [5] Biscotti C.V., Hart W.R.: "Peritoneal serous micropapillomatosis of low malignant (serous borderline tumors of the peritoneum): a clinicopathologic study of 17 cases". *Am. J. Surg. Pathol.*, 1992, 16, 467.
- [6] Fox H.: "Primary neoplasia of the female peritoneum". *Histopathology*, 1993, 23, 103.
- [7] Bell D.A., Weinstock M.A., Scully R.E.: "Peritoneal implants of ovarian serous borderline tumors: histologic features and prognosis". *Cancer*, 1988, 62, 2212.
- [8] Biron-Shental T., Klein Z., Eldstein E., Altaras M., Fishman A.: "Primary peritoneal borderline tumor: a case report and review of the literature". *Eur. J. Gynaecol. Oncol.*, 2003, 24, 96.
- [9] Trope C., Karen J.: "Management of borderline tumors of the ovary: state of art". *Semin. Oncol.*, 1998, 25, 372.
- [10] Trimble C.L., Trimble E.L.: "Management of epithelial ovarian tumors of low malignant potential". *Gynaecol. Oncol.*, 1994, 55, 52.

Address reprint requests to:
D. COUTO, M.D.
Serviço de Ginecologia,
Hospitais da Universidade de Coimbra
Praceta Prof. Mota Pinto
3049 Coimbra Codex (Portugal)