

Diabetic macular edema

J. CUNHA-VAZ

Department of Ophthalmology and Centre of Ophthalmology,
University Hospital of Coimbra and Institute of Biomedical Research on Light and Image, Coimbra - Portugal

ABSTRACT: *Retinal edema is defined as any increase of water in retinal tissue resulting in an increase in its volume. This increase may be initially intracellular or extracellular. In the first case, there is cytotoxic edema. In the second, vasogenic edema, directly associated with an alteration of the blood-retinal barrier (BRB).*

Retinal thickness can now be measured, using the retinal thickness analyser (RTA). Similarly, local breakdown of the BRB can now be mapped using the retinal leakage analyser (RLA). The application of these methods to diabetic macular edema has shown that both types of retinal retinopathy edema occur in the initial stages of diabetic retinal disease. These observations suggest a role for neuroprotective and vasoprotective agents in the management of diabetic retinal disease. (Eur J Ophthalmol 1998; 8: 127-30)

KEY WORDS: *Edema, Blood-Retinal Barrier, Macula, Retinal leakage analyser, Retinal thickness analyser*

Accepted: July 20, 1998

Diabetes is the leading cause of new cases of legal blindness among working-age Americans. Type I carries a higher risk of ocular complications, but because there are so many more Type II patients, they make up a substantial proportion of patients with blinding sequelae.

One of the two major causes of visual loss due to diabetes is macular edema. It has been estimated that each year in the United States there are almost 75,000 new cases of diabetic macular edema. These numbers are likely to rise, since it is expected that by the year 2010, 10% of the USA population will suffer from diabetes, especially the non-insulin dependent type (1).

Basic concepts of retinal edema

In 1985, Ferris and Patz (2) defined diabetic macular edema as "an abnormal collection of extracellular fluid in the retina". A sensitive assessment is given by the presence of increased fluorescence in the late stages of fluorescein angiography. In the same year, we stated that edema develops when fluid accumulates within the retina, increasing retinal volume, and we intro-

duced the concept of retinal compliance, an important factor in controlling the rate of fluid accumulation in the retina (3).

However, like brain edema, retinal edema must clearly be defined as any increase of water in the retinal tissue resulting in an increase in its volume, i.e., thickness. This increase may initially be intracellular or extracellular. In the first case - cytotoxic edema - the cell ionic exchanges are altered, with an excess of Na⁺ inside the cell. In the second case - vasogenic edema - there is a predominantly extracellular accumulation of fluid, directly associated with an alteration of the blood-retinal barrier (BRB) permeability to proteins. In this latter situation any loss of equilibrium between hydrostatic, oncotic and osmotic pressure gradients across the BRB contribute to further water movements and edema.

Cytotoxic edema is initially not a true edema but only a redistribution of water into the cell from its normal extracellular location, leading to cell damage and release of vasoactive substances which may induce vasogenic edema by altering the BRB. The initial alteration may be a lack of ATP⁺ with depolarization of the cell membranes, alteration of the cell ionic pumps

and an increase of extracellular K^+ , with glutamate release and increase of intracellular Ca^{2+} (4). Cytotoxic edema may also result from excitatory release of glutamate or lactic acidosis, activating Na^+/H^+ transport and causing accumulation of intracellular Na^+ .

Vasogenic edema results from a breakdown of the BRB with extracellular deposition of macromolecules. The primary defect is in the BRB and fluid accumulation is extracellular. In this situation, the "force" driving water across the capillary wall is a hydrostatic pressure difference, ΔP , and an effective osmotic pressure difference, $\Delta\pi\sigma$. The equation is therefore:

$$(\text{driving force}) = L_p [(P_{\text{plasma}} - P_{\text{tissue}}) - \sigma (\pi_{\text{plasma}} - \pi_{\text{tissue}})]$$

where L_p is the hydraulic conductivity or membrane permeability of the BRB and σ an osmotic reflection coefficient, P_{plasma} is the blood pressure, P_{tissue} is the retinal tissue pressure represented by its cohesiveness and compliance, π_{plasma} is blood osmotic pressure and π_{tissue} the tissue osmotic pressure.

The loss of equilibrium between these pressure gradients is important only after alteration of the BRB and then contributes to water movements.

An increase in ΔP contributing to retinal edema may arise from an increase in P_{plasma} or a decrease in P_{tissue} , or both. An increase in P_{plasma} due to increased systemic blood pressure does not normally cause retinal edema because of the autoregulation of retinal blood flow and the structural characteristics of the BRB. A decrease in P_{tissue} may be due to loss of cohesiveness of the retinal tissue, associated with vitreous traction, aging or retinal disease, thus increasing retinal compliance. A decrease in P_{tissue} allows for faster fluid accumulation within its limits, and facilitates the increase in retinal thickness.

A decrease in $\Delta\pi$, contributing to retinal edema, may be due to increased protein accumulation in the retina after breakdown of the BRB. A reduction in plasma osmolarity only contributes to edema formation in the brain if it is rapid and in the order of 35 mosmols. After a breakdown of the BRB the progression of retinal edema depends on the gradient between intravascular and tissue hydrostatic pressures. Tissue compliance then becomes more important, influencing the rate of edema progression.

A few notions must be briefly recapitulated. Retinal

edema may initially be exclusively intracellular or extracellular. In the first case, it may occur without breakdown of the BRB. In the second case, BRB breakdown must occur. Intracellular cytotoxic retinal edema may result in the production of a variety of vasoactive agents, such as free radicals or nitric oxide which, in turn, induce breakdown of the BRB and the subsequent vasogenic edema.

Clinical evaluation of retina edema

The clinical evaluation of macular edema is always difficult. Direct and indirect ophthalmoscopy may reveal nothing but an alteration of the foveal reflexes. Stereoscopic fundus photography and slit-lamp microscopy have played an important role in showing changes in retinal volume in the macular area but they are dependent on the observer and do not measure the volume change. In the Early Treatment Diabetic Retinopathy Study, the ophthalmologists agreed that the following characteristics indicate "clinically significant macular edema":

1) thickening of the retina (as seen either by slit lamp biomicroscopy or by stereo fundus photography) at or within 500 microns of the center of the macula;

2) hard exudates at or within 500 microns of the center of the macula, with thickening of the adjacent retina (but not residual hard exudates remaining after disappearance of retinal thickening); and

3) a zone(s) of retinal thickening one disc in area or larger, any part of which is within one disc diameter of the center of the macula.

This definition has proved its usefulness but needs further clarification. It was proposed to take involvement of the center of the macula and its relationship with visual loss into special consideration.

We have seen that retinal edema means there is an increase in retinal volume. This involves an increase in retinal thickness because of the anatomical architecture of the retina. There is now one technique available that objectively measures overall retinal thickness, the retinal thickness analyser (RTA) (5).

We have also seen that there are two main types of retinal edema: cytotoxic or intracellular, and vasogenic or extracellular. The first may be present without breakdown of the BRB whereas the second is directly associated with BRB breakdown. Clinically, BRB permeability may be measured by vitreous fluorometry. An increase

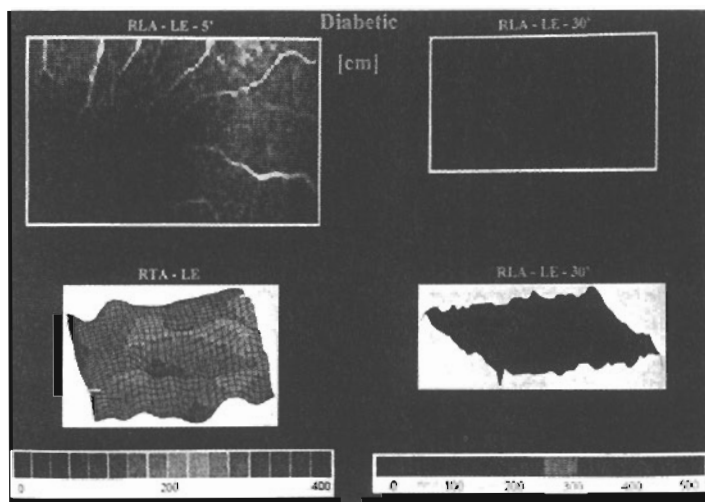


Fig. 1a - Composite information from the same area of the macula of a diabetic eye (cm) with no retinopathy (LE - left eye)
 Upper left - fluorescein angiography
 Upper right - retinal leakage analyser (RLA) - map of fluorescein leakage (bidimensional)
 Lower left - Retinal thickness analyser (RTA) - map of retinal thickness
 Lower right - RLA - map of fluorescein leakage (three-dimensional)
 Not all zones with increased thickness correspond to sites of increased fluorescein leakage.

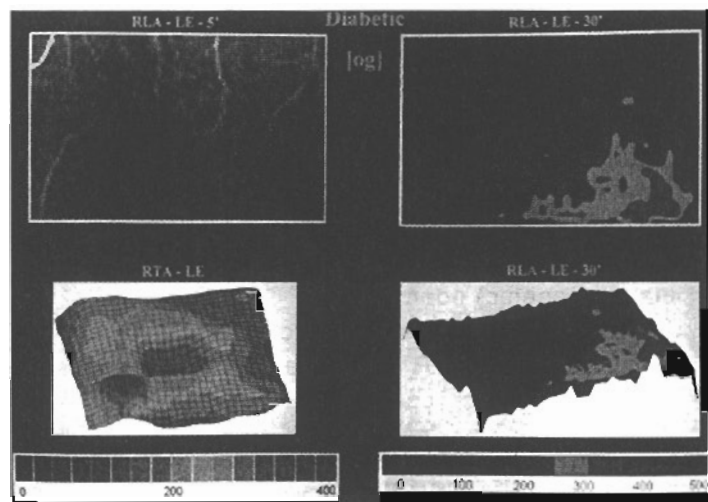


Fig. 1b - Composite information from the same area of the macula of a diabetic eye (og) with minimal retinopathy (LE-left eye).
 Upper left - fluorescein angiography
 Upper right - RLA - map of fluorescein leakage
 Lower left - RTA - map of retinal thickness
 Lower right - RLA - map of fluorescein leakage (three-dimensional)
 All the images are obtained from the same area of the retina.
 The zone with more increased thickness does not correspond to the site of more fluorescein leakage.

in vitreous fluorometry values is directly associated with visual loss in well-defined cases of diabetic retinal edema. In a study using fundus photography, fluorescein angiography and vitreous fluorometry, the latter was the best predictor of visual loss in diabetic macular edema (6).

Recently, we developed a new method for local measurements of BRB permeability, the retinal leakage analyser (RLA), based on a confocal scanning laser ophthalmoscope (7). This method has been tested in normal individuals, diabetic patients, before and after photocoagulation, and in a variety of other situations, in which it had very good resolution, both axial and lateral. This method can be used to map retinal leakage and simultaneously image the retina. The alterations of the BRB are quantified and can be directly correlated with changes in retinal morphology.

Retinal edema in diabetes

In the evaluation of diabetic edema these new methods have shown that both types, cytotoxic and vasogenic, occur in the diabetic retina before the devel-

opment of clinically significant macular edema. Preliminary results have shown that in diabetic eyes without vascular pathology visible on ophthalmoscopic examination there may be localized areas of increased retinal thickness in the posterior pole without breakdown of the BRB (Fig. 1a). In the same eyes, however, in other sites of the macula there are areas of increased thickness associated with increased fluorescein leakage and breakdown of the BRB (Fig. 1b).

In the diabetic retina, therefore, the two types of retinal edema appear to arise together from the initial steps of the disease. Cytotoxic edema may well first occur in the diabetic retina. Recent results from our laboratory indicate that the retinal vessels keep transporting glucose into the retina at even higher rates in the presence of hyperglycemia, creating an excessive accumulation of glucose in the inner retina (8). These high glucose levels in the retina in diabetes raise retinal levels of sorbitol and triose phosphates and increase lactate and fructose production. The increase in the lactate: pyruvate ratio is similar to that induced by hypoxia. Williamson and co-workers (9) called this a situation of hyperglycemia-induced "pseudo-hypoxia". Intracellular

edema is a natural outcome, with the resulting cell ionic changes and excessive glutamate release.

A functional alteration of the BRB involving its outward transport can be expected immediately. Later progressive retinal cellular damage would result in the release of vasoactive substances such as nitric oxide and free radicals, inducing vascular damage and breakdown of the BRB with protein leakage and extracellular (vasogenic) edema.

Studies of the earliest stages of retinal involvement in diabetes using the RTA and the RLA simultaneously, together with optical coherence tomography (OCT) will certainly offer new insights into diabetic retinal disease, particularly edema. Better management of diabetic macular edema will be an important result.

The reasoning behind laser photocoagulation treatment for diabetic retinal edema needs to be reviewed and analysed. Should only focal treatment of leakage sites be done to correct the alteration of BRB? Should damaged retinal tissue be destroyed to prevent the formation of vasoactive substances? Or, finally, should just a mild scatter be done over the posterior pole looking for activation of the outer BRB?

Medical therapy of diabetic retinal edema should be targeted better in the near future. Medical therapies for retinal edema have included corticosteroids, non-

steroid anti-inflammatory agents, carbonic anhydrase inhibitors and hyperoxic therapy. In diabetic macular edema, it may be more effective to establish which type of retinal edema predominates, cytotoxic or vasogenic, and select neuroprotective or vasoprotective agents accordingly. Potentially useful neuroprotective agents include calcium-channel blockers, glutamate receptor antagonists and antioxidants. Vasoprotective agents that offer promise are nitric oxide synthetase inhibitors, advanced glycation endproduct (AGE) formation inhibitors and angiotensin conversion enzyme (ACE) inhibitors.

These drugs may be used in the near future to protect the retinal cells and the BRB from the damage caused by the increased, abnormal glucose metabolism in the diabetic retina, and thus delay the development of retinopathy.

Reprint requests to:
Prof. José Cunha-Vaz
Department of Ophthalmology and
Centre of Ophthalmology
University Hospital of Coimbra and
Institute of Biomedical
Research on Light and Image
3000 Coimbra, Portugal

REFERENCES

1. King H. The epidemic of NIDDM: an epidemiological perspective. *Int Diab Fed Bull* 1995; 40: 10-2.
2. Ferris FL, Patz A. Macular edema. A complication of diabetic retinopathy. *Surv Ophthalmol* 1984; 28 (suppl): S452-61.
3. Cunha-Vaz JG, Travassos A. Breakdown of the blood-retinal barriers and cystoid macular edema. *Surv Ophthalmol* 1984; 28 (suppl): S485-92.
4. Cohadon F. Protection cérébrale. Bases conceptuelles et applications. Paris: Arnette Blackwell, 1995; 1-184.
5. Zeimer R, Mori MT, Khoobehi B. Feasibility test of a new method to measure retinal thickness noninvasively. *Invest Ophthalmol Vis Sci* 1989; 30: 2099-105.
6. Smith RT, Lee CM, Charles H, Farber M, Cunha-Vaz JG. Quantification of diabetic macular edema. *Arch Ophthalmol* 1987; 105: 218-22.
7. Lobo C, Isidoro I, Simões PC, Leite E, Sander B, Cunha-Vaz JG. Topographic vitreous fluorometry using a modified confocal laser scanning ophthalmoscope. *Invest Ophthalmol Vis Sci* 1996; 37 (suppl): S611.
8. Murta JN, Serra A, Cunha-Vaz JG. Characterization of D-glucose transport across diabetic retinal vessels. *Invest Ophthalmol Vis Sci* 1996; 37 (suppl): S979.
9. van Enden M, Nyengaard J, Ostrair E, Burgan JH, Williamson JR. Elevated glucose levels increase retinal glycolysis and sorbitol pathway mechanisms. *Invest Ophthalmol Vis Sci* 1995; 36: 1675-85.