

Case 8067

Giant aneurysm of the left renal artery

I. Santiago¹; C. Ruivo²; H. Rodrigues²; A. Gil-Agostinho²

¹Hospital Infante D. Pedro - Aveiro, Portugal

²Clínica Universitária de Imagiologia dos HUC - Coimbra, Portugal

Section: Cardiovascular

Published: 2010, Jan. 11

Patient: 22 year(s), male

Clinical History

A 22-year-old male patient with an unremarkable medical history was admitted to the ER with complaints of non-colicky, persistent, left-flank pain. Physical examination revealed a pulsatile mass in the left flank. He was normotensive. CT-Angiography showed a 19, 5 cm true aneurysm of the left renal artery.

Imaging Findings

A 22 year-old male patient was admitted to the ER with complaints of persistent, non-colicky, left flank pain with a 2-week duration. There were no accompanying symptoms, namely fever or dysuria. Medical history was unremarkable.

A large pulsatile mass in the left flank was noted during physical examination. No signs of peritoneal irritation were present. Patient was normotensive at the time (he had no previous tension records).

CT-Angiography showed a 19, 5 cm aneurysm involving the middle and distal thirds of the left renal artery. It appeared to have a compound fusiform and sacular morphology and showed extensive and irregular mural thrombosis and peripheral calcification on its sacular, distal part. It also compressed and displaced the renal parenchyma centrifugally, which showed a marked reduction and delay of the expected parenchymal enhancement when compared to the opposite side. No proximal stenosis of the renal artery was observed.

Digital subtraction angiography showed normal outline and calibre of the proximal segment of the

left renal artery. Late-phase images depicted normal elimination of contrast by the left kidney. Marked elongation of the left pelvicalical system with calicial spreading was apparent. Coil embolisation was attempted but unsuccessful. Patient underwent left nephrectomy and no post-operative complications were reported.

Discussion

Renal artery aneurysms are uncommon, with an estimated incidence of 0.09% in the general population, 0.1%-2.5% in angiographic series, and up to 9.7% in autopsy series. [3] They constitute between 15 and 25% of all visceral artery aneurysms, second only to splenic artery aneurysms, and are most commonly located along the main renal artery. [3, 6] They are bilateral in 10% of cases. [2]

Renal artery aneurysms exhibit calcification in 18% of cases and only 8.5% are larger than 20 mm. [3] The largest aneurysm we found in the literature measured 25 cm. [7] They may be true (saccular and fusiform), false (arising from penetrating or blunt trauma) or dissecting. [2] Approximately 75% of the renal artery aneurysms are saccular and almost invariably occur at the main renal artery bifurcation. [2] Only 10% are intraparenchymal, usually cortical and associated with polyarteritis nodosa. [2]

Peak incidence occurs between the ages of 40-60 years and some authors report it to be equal between men and women, while others report a higher incidence in women. [2, 3, 6]

The two most common underlying aetiologies are atherosclerosis or fibrous dysplasia, renal angiomyolipoma and congenital renal malformations being much less frequent causes. [3, 4] Secondary renal artery aneurysms are seen in such conditions as malignancies, infection (mycotic), and trauma, in association with systemic diseases, such as polyarteritis nodosa, neurofibromatosis, William's syndrome, midaortic syndrome, autoimmune vasculitis, and tuberous sclerosis, or are iatrogenic (e.g. renal biopsy). [2]

The clinical significance of these aneurysms varies from that of an incidental finding to hypertension, flank pain and haematuria. [3]

Possible complications include:

- . Rupture, with a generally low estimated risk (between 2, 8 and 5, 6%), thought to be greater during pregnancy, in patients with polyarteritis nodosa and in non-calcified aneurysms, with reported mortality rates above 80%; [1, 3, 4]
- . Embolisation; [1]
- . Hypertension, which has no relation with renal artery stenosis and has a prevalence of up to 80%. Hypotheses regarding the pathophysiologic basis of hypertension include coexisting renal artery stenosis, microembolisation from the aneurysm, compression or kinking of the renal artery or its branches, and turbulent flow; [1, 6]
- . Renal insufficiency; [1]

Plain film findings include marginal calcifications of the aneurysm and distended bowel loops as a sign of retroperitoneal irritation. Ultrasound may demonstrate a distended pelvis and perirenal collections in cases of rupture but findings are otherwise generally non-specific. MDCT

Angiography is the preferred imaging modality due to its unique spatial resolution. [4]

Follow-up of aneurysms < 2 cm is generally accepted. [6] Standard treatment for larger aneurysms is surgery and includes aneurysm resection, aortorenal bypass, reno-renal interposition, reimplantation, patch angioplasty, and nephrectomy. [3] Endovascular treatment is nowadays considered to be a valid alternative and includes both coil embolisation and endoprosthesis placement, but no direct comparison studies are available. [1]

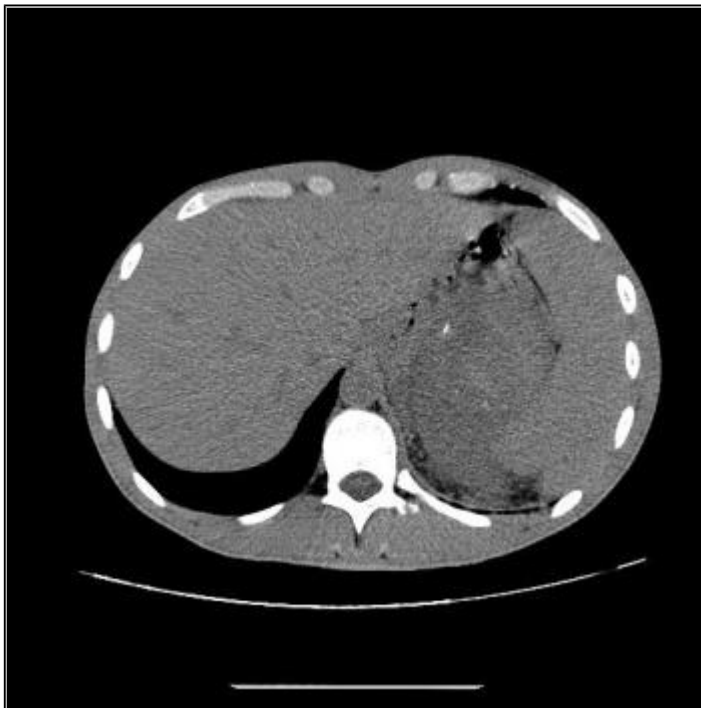
Indications for treatment include rupture, renovascular hypertension, embolisation, dissection, aneurysm expansion, size ≥ 1.5 cm to ≥ 2.5 cm, pregnancy and child bearing age. [3]

Final Diagnosis

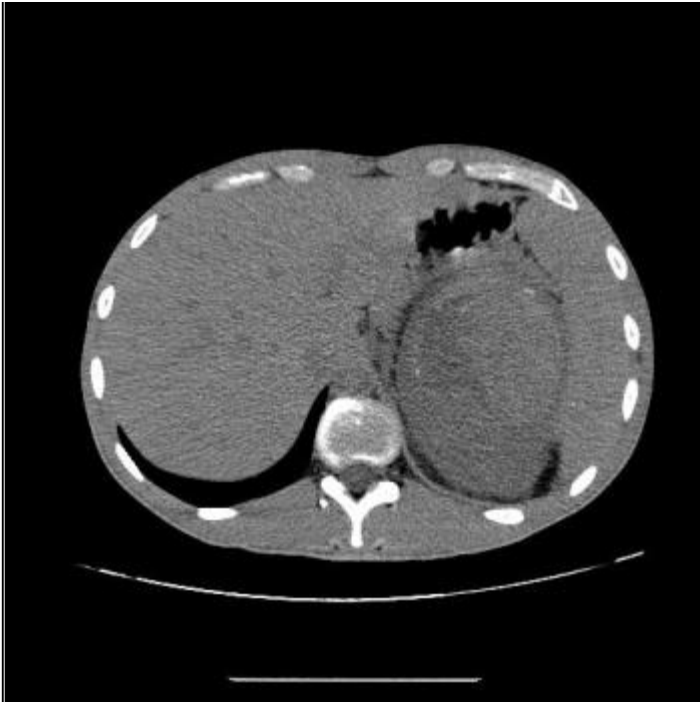
Giant aneurysm of the left renal artery

Figures

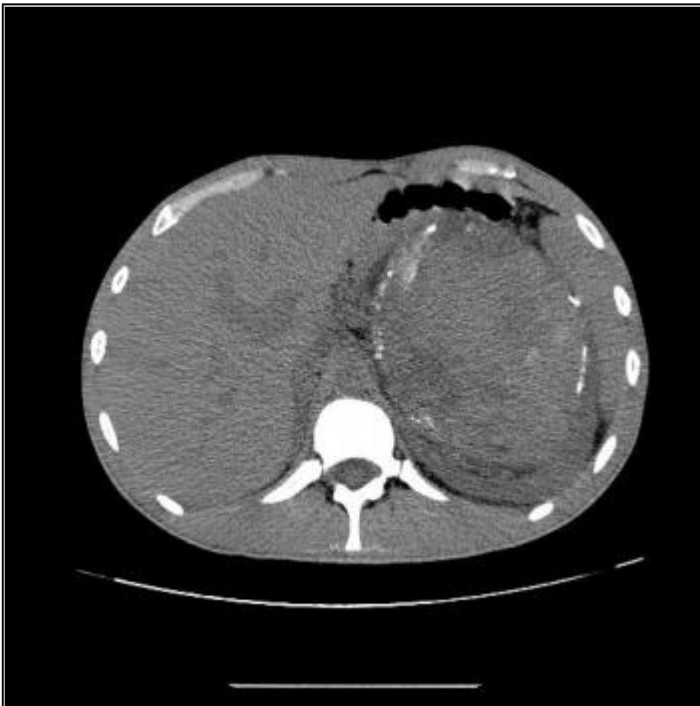Figure 1 CT Angiography



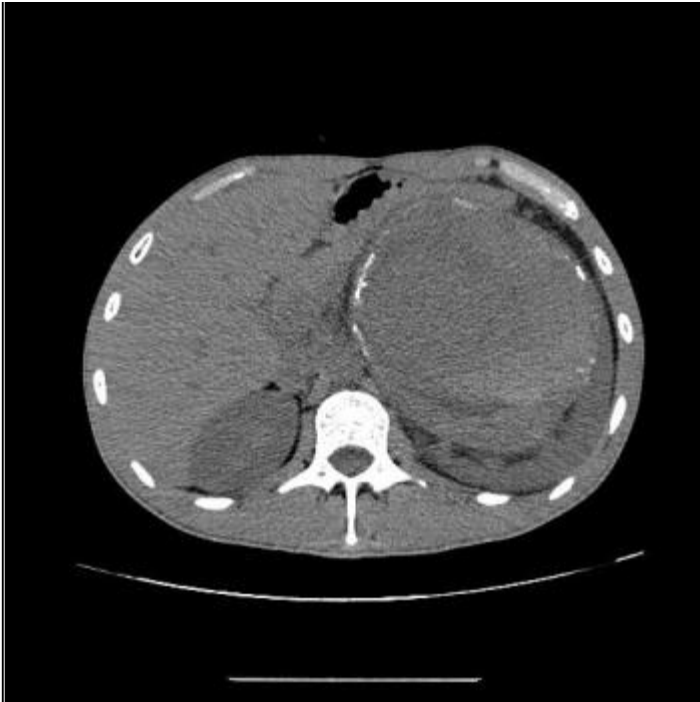Pre-contrast CT showed peripheral hyperattenuating areas suggestive of recent growth of the mural thrombus and linear calcifications.



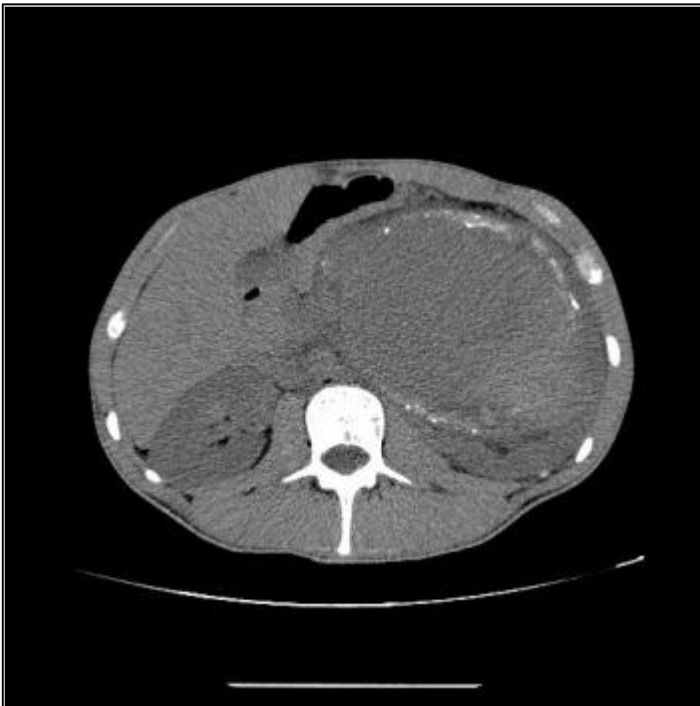Pre-contrast CT showed peripheral hyperattenuating areas suggestive of recent growth of the mural thrombus and linear calcifications.



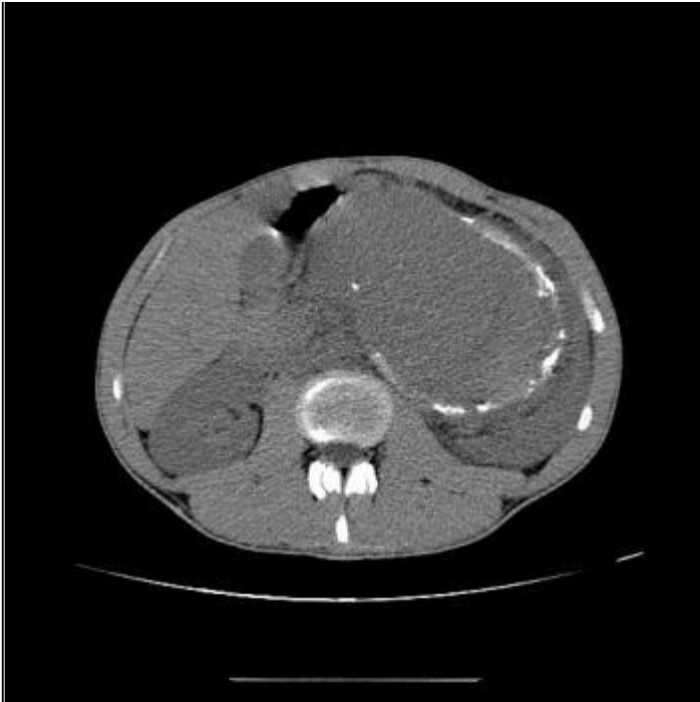Pre-contrast CT showed peripheral hyperattenuating areas suggestive of recent growth of the mural thrombus and linear calcifications.



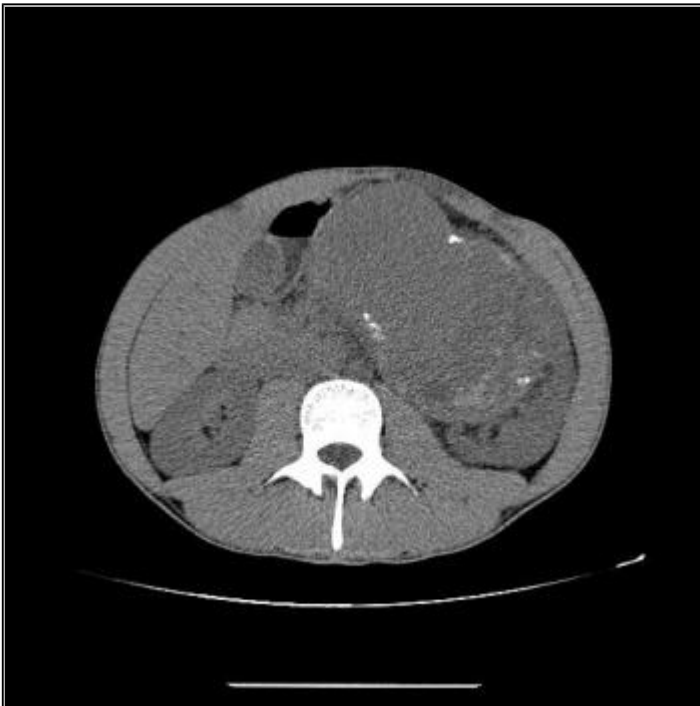Pre-contrast CT showed peripheral hyperattenuating areas suggestive of recent growth of the mural thrombus and linear calcifications.



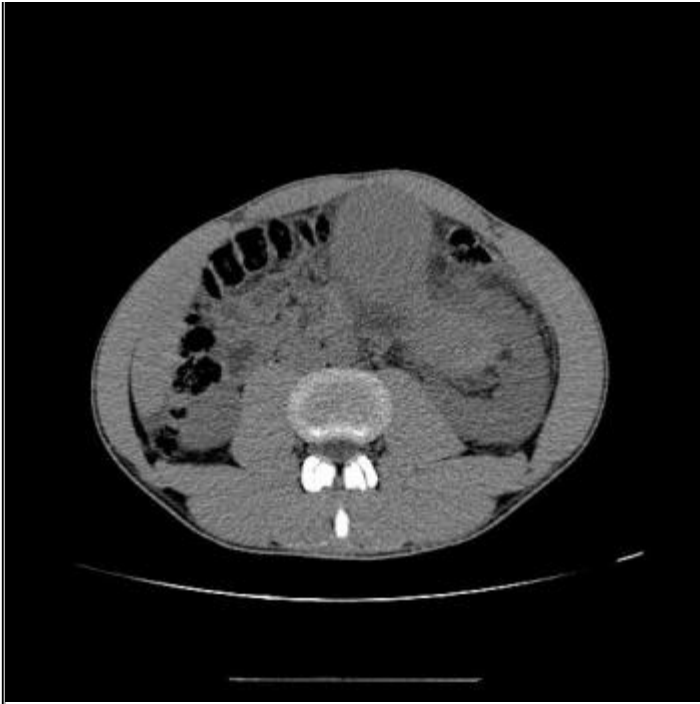Pre-contrast CT showed peripheral hyperattenuating areas suggestive of recent growth of the mural thrombus and linear calcifications.



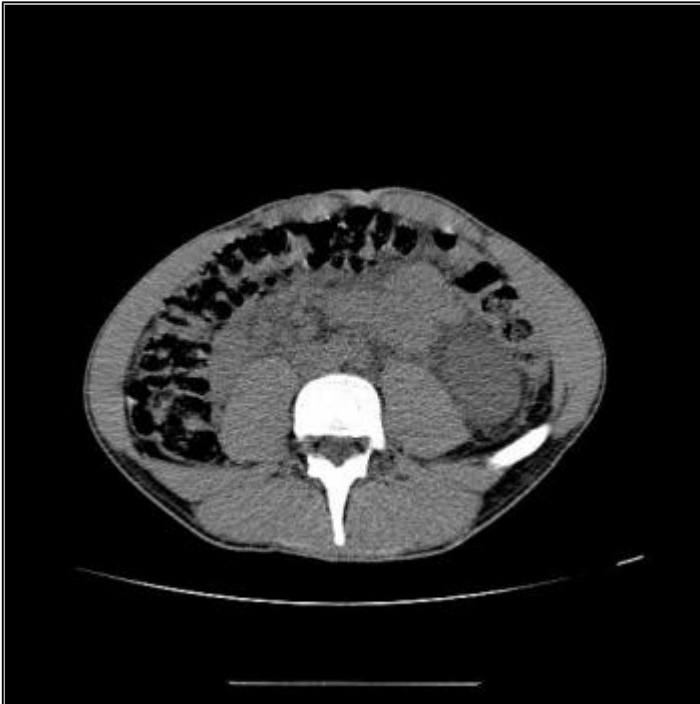Pre-contrast CT showed peripheral hyperattenuating areas suggestive of recent growth of the mural thrombus and linear calcifications.



Pre-contrast CT showed peripheral hyperattenuating areas suggestive of recent growth of the mural thrombus and linear calcifications.



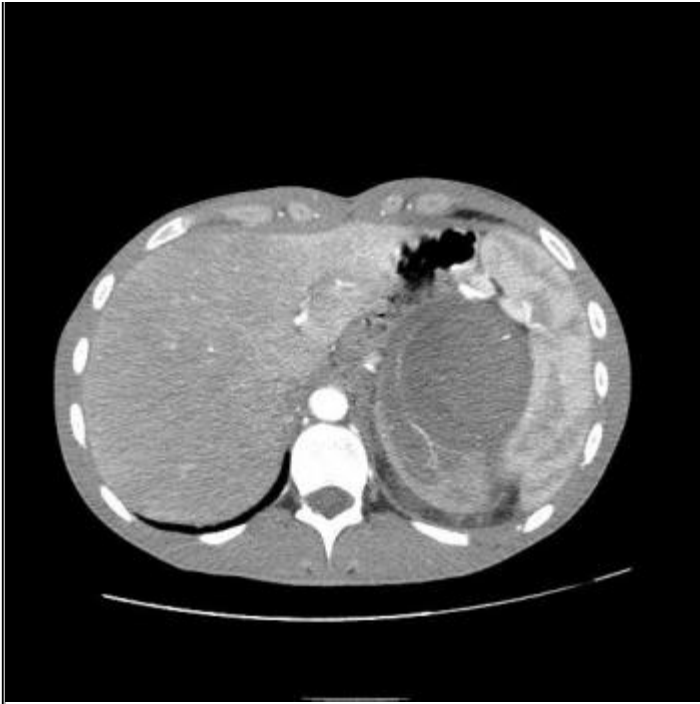
Pre-contrast CT showed peripheral hyperattenuating areas suggestive of recent growth of the mural thrombus and linear calcifications.



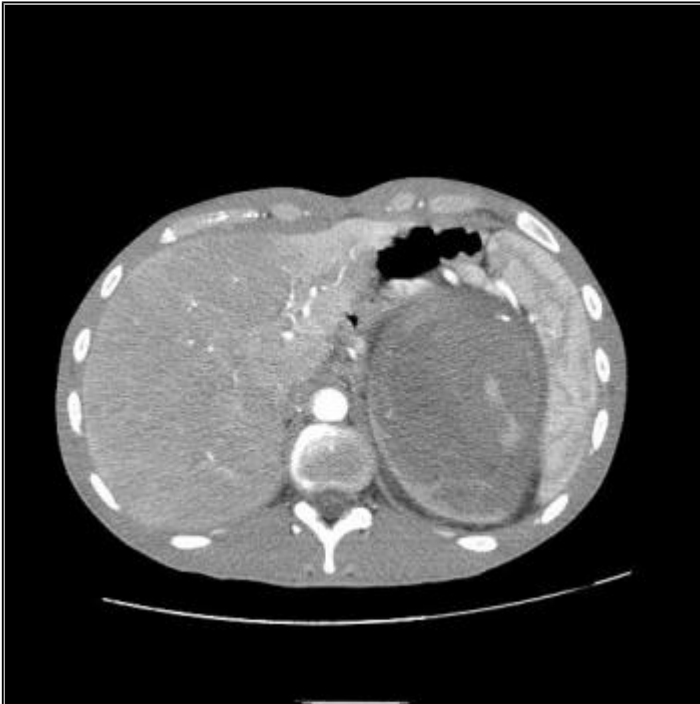
Pre-contrast CT showed peripheral hyperattenuating areas suggestive of recent growth of the mural thrombus and linear calcifications.

Figure 2 CT Angiography

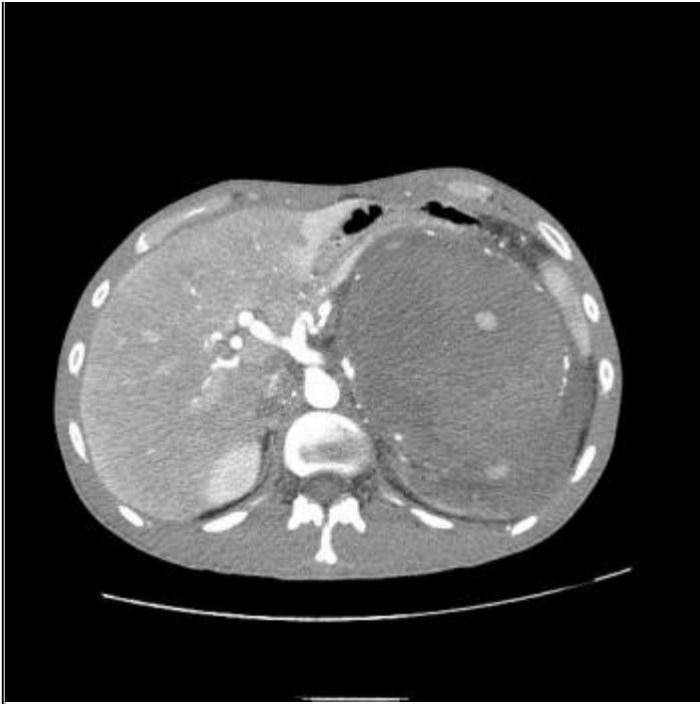



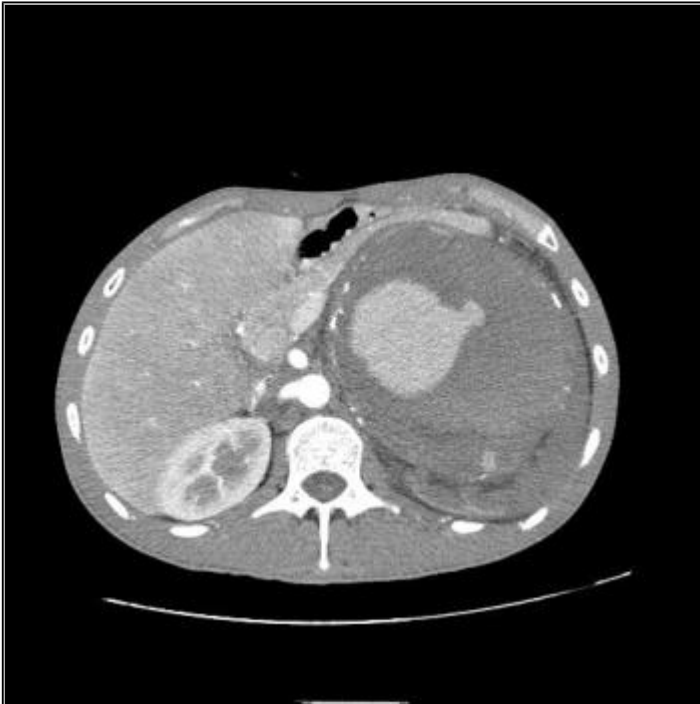Post-contrast CT depicted the 19,5 cm aneurysm involving the middle and distal thirds of the left renal artery, with a compound fusiform and sacular morphology and extensive mural thrombosis. It compressed and displaced the renal parenchyma centrifugally, which showed a marked reduction and delay of the expected parenchymal enhancement. No proximal stenosis of the renal artery was observed.



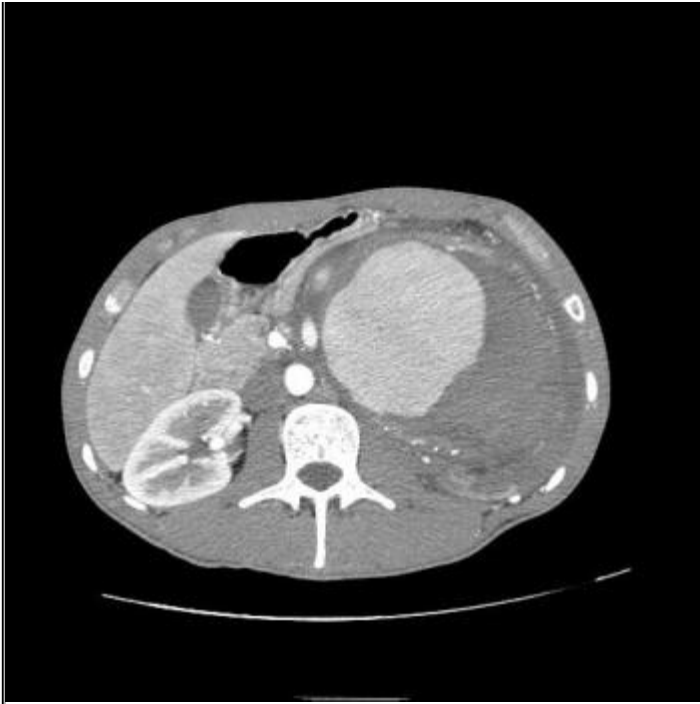Post-contrast CT depicted the 19,5 cm aneurysm involving the middle and distal thirds of the left renal artery, with a compound fusiform and sacular morphology and extensive mural thrombosis. It compressed and displaced the renal parenchyma centrifugally, which showed a marked reduction and delay of the expected parenchymal enhancement. No proximal stenosis of the renal artery was observed.



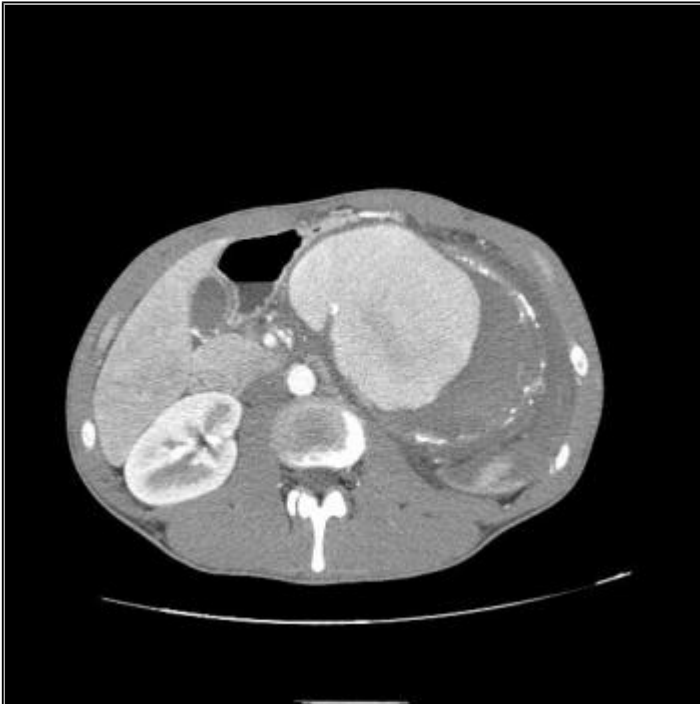Post-contrast CT depicted the 19,5 cm aneurysm involving the middle and distal thirds of the left renal artery, with a compound fusiform and sacular morphology and extensive mural thrombosis. It compressed and displaced the renal parenchyma centrifugally, which showed a marked reduction and delay of the expected parenchymal enhancement. No proximal stenosis of the renal artery was observed.



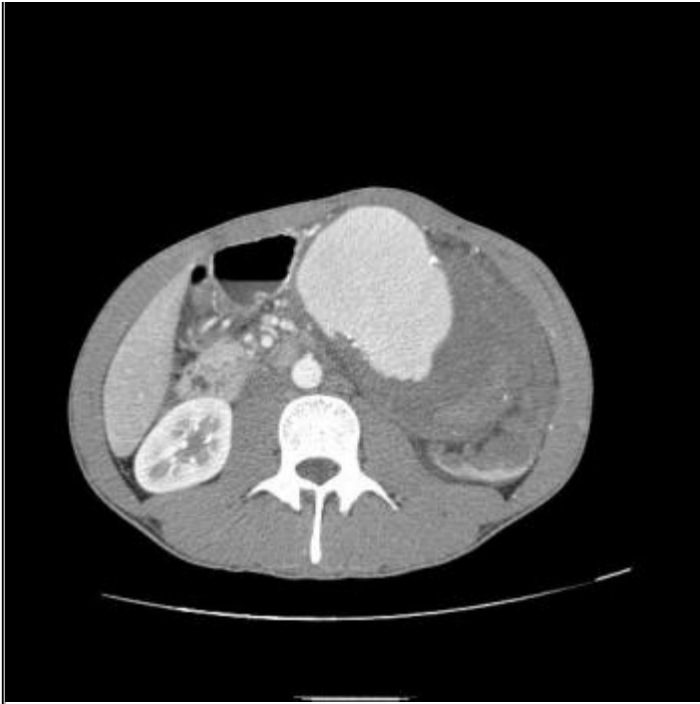Post-contrast CT depicted the 19,5 cm aneurysm involving the middle and distal thirds of the left renal artery, with a compound fusiform and sacular morphology and extensive mural thrombosis. It compressed and displaced the renal parenchyma centrifugally, which showed a marked reduction and delay of the expected parenchymal enhancement. No proximal stenosis of the renal artery was observed.



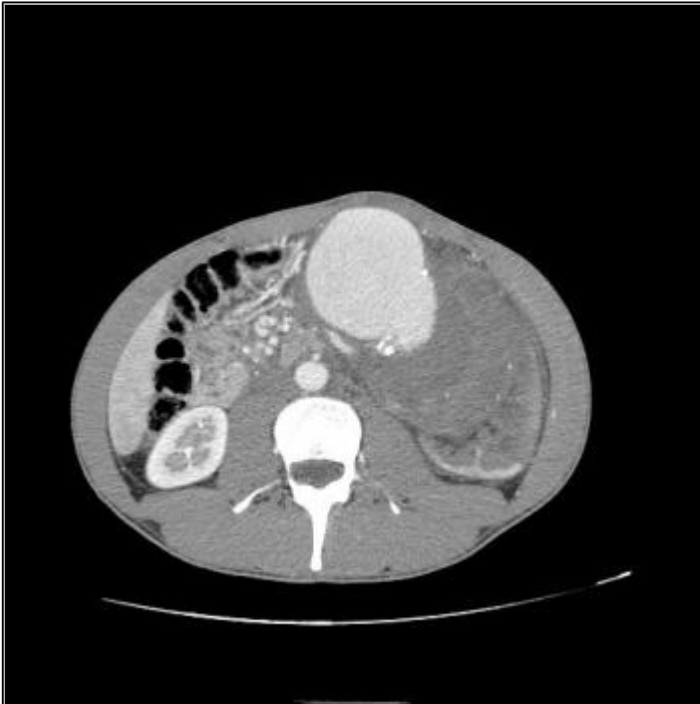Post-contrast CT depicted the 19,5 cm aneurysm involving the middle and distal thirds of the left renal artery, with a compound fusiform and sacular morphology and extensive mural thrombosis. It compressed and displaced the renal parenchyma centrifugally, which showed a marked reduction and delay of the expected parenchymal enhancement. No proximal stenosis of the renal artery was observed.



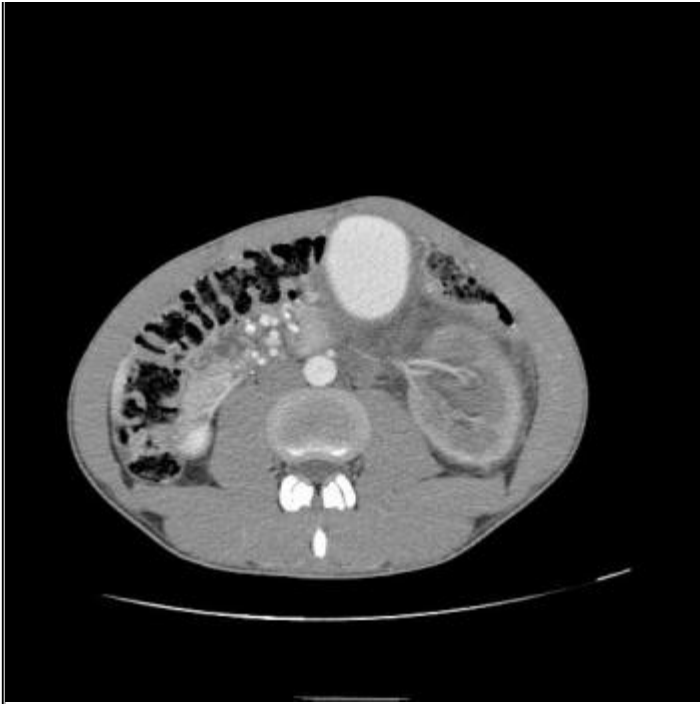Post-contrast CT depicted the 19,5 cm aneurysm involving the middle and distal thirds of the left renal artery, with a compound fusiform and sacular morphology and extensive mural thrombosis. It compressed and displaced the renal parenchyma centrifugally, which showed a marked reduction and delay of the expected parenchymal enhancement. No proximal stenosis of the renal artery was observed.



Post-contrast CT depicted the 19,5 cm aneurysm involving the middle and distal thirds of the left renal artery, with a compound fusiform and sacular morphology and extensive mural thrombosis. It compressed and displaced the renal parenchyma centrifugally, which showed a marked reduction and delay of the expected parenchymal enhancement. No proximal stenosis of the renal artery was observed.

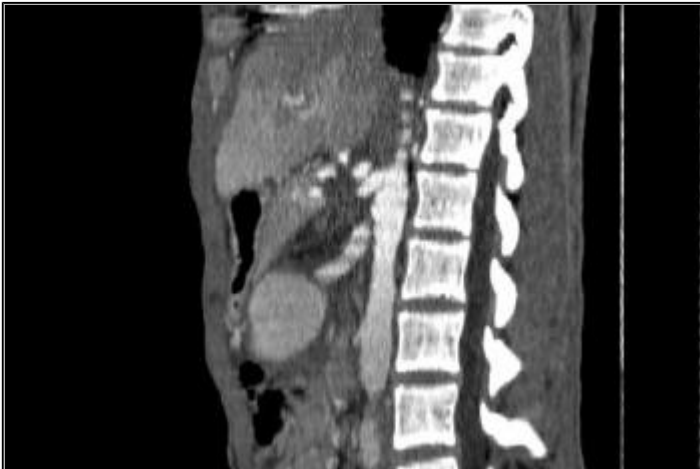

Post-contrast CT depicted the 19,5 cm aneurysm involving the middle and distal thirds of the left renal artery, with a compound fusiform and sacular morphology and extensive mural thrombosis. It compressed and displaced the renal parenchyma centrifugally, which showed a marked reduction and delay of the expected parenchymal enhancement. No proximal stenosis of the renal artery was observed.

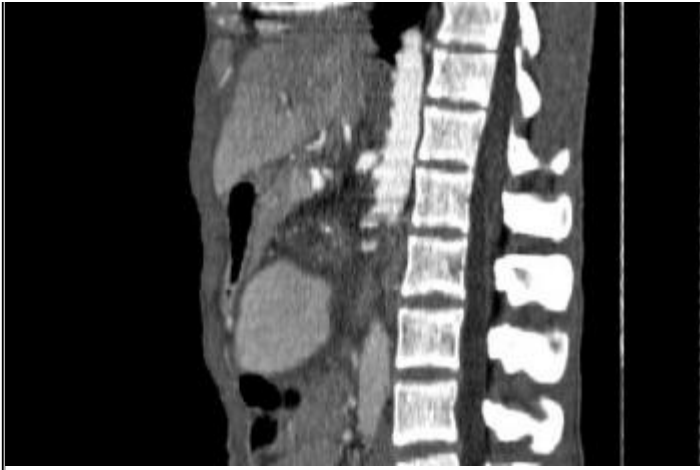


Post-contrast CT depicted the 19,5 cm aneurysm involving the middle and distal thirds of the left renal artery, with a compound fusiform and sacular morphology and extensive mural thrombosis. It compressed and displaced the renal parenchyma centrifugally, which showed a marked reduction and delay of the expected parenchymal enhancement. No proximal stenosis of the renal artery was observed.

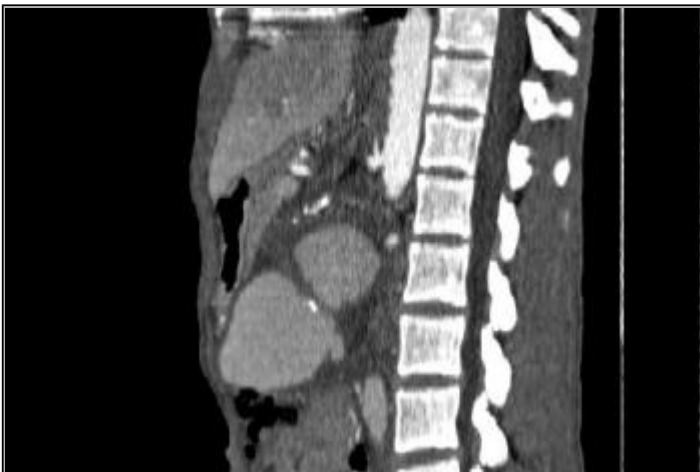
Figure 3 CT Angiography



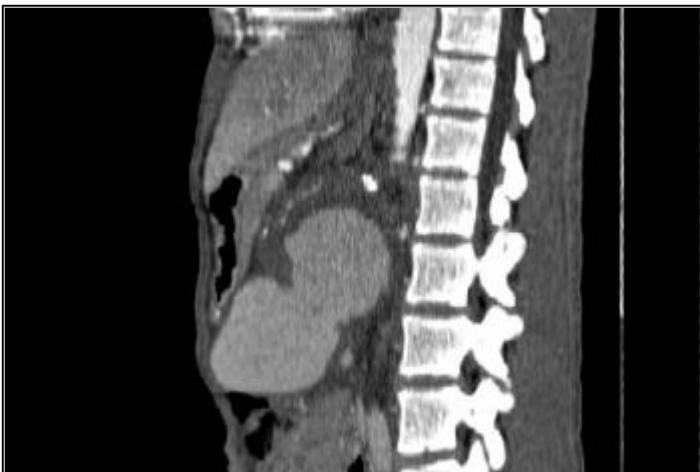Sagittal reformatation, better depicting the cranio-caudal extension of the aneurysm and the centrifugal displacement of the renal parenchyma.




Sagittal reformatation, better depicting the cranio-caudal extension of the aneurysm and the centrifugal displacement of the renal parenchyma.

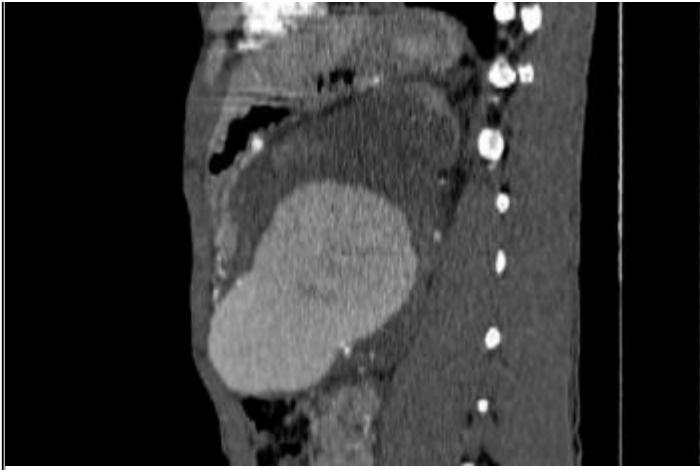


Sagittal reformatation, better depicting the cranio-caudal extension of the aneurysm and the centrifugal displacement of the renal parenchyma.

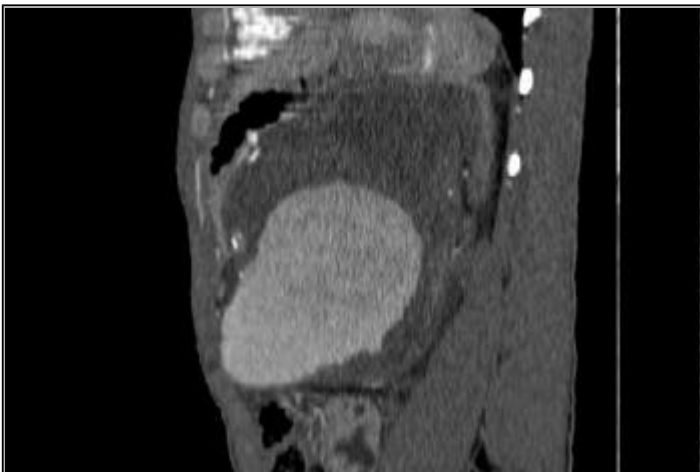


Sagittal reformatation, better depicting the cranio-caudal extension of the aneurysm and the centrifugal displacement of the renal parenchyma.

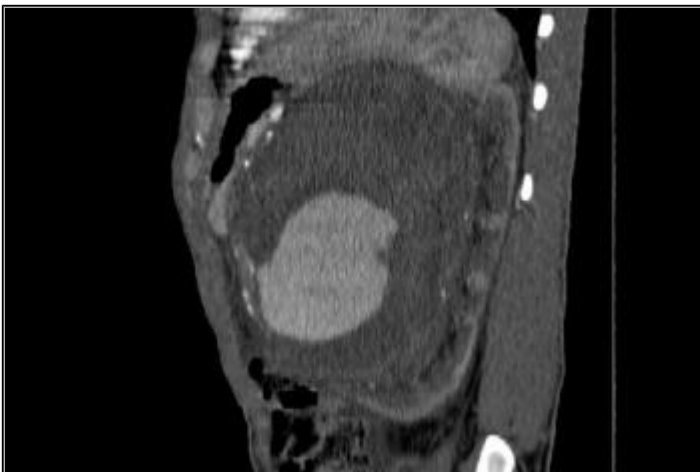





Sagittal reformatation, better depicting the cranio-caudal extension of the aneurysm and the centrifugal displacement of the renal parenchyma.

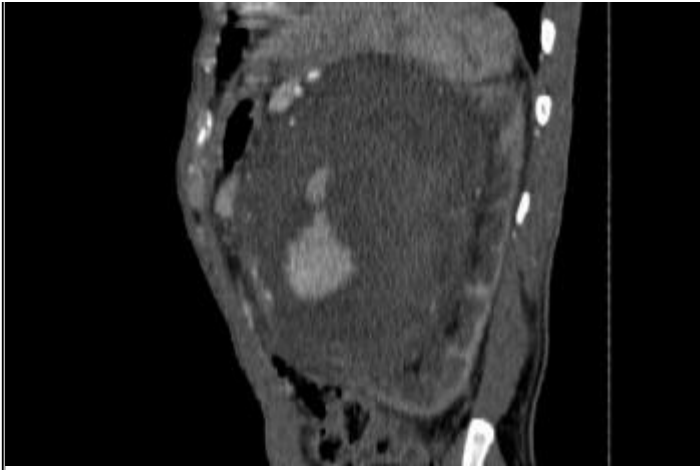


Sagittal reformatation, better depicting the cranio-caudal extension of the aneurysm and the centrifugal displacement of the renal parenchyma.

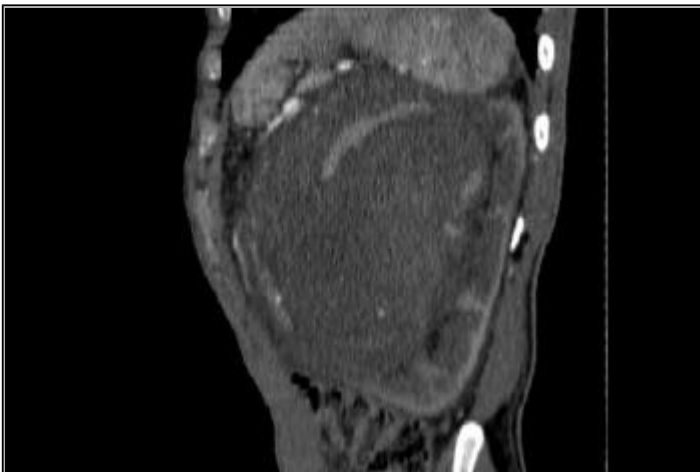


Sagittal reformatation, better depicting the cranio-caudal extension of the aneurysm and the centrifugal displacement of the renal parenchyma.

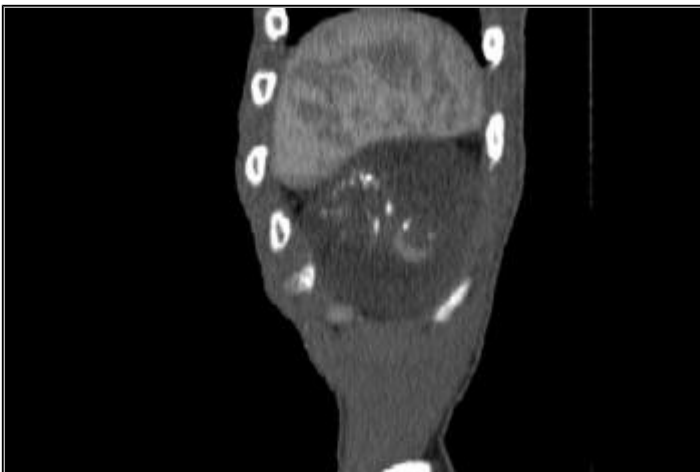




Sagittal reformatation, better depicting the cranio-caudal extension of the aneurysm and the centrifugal displacement of the renal parenchyma.



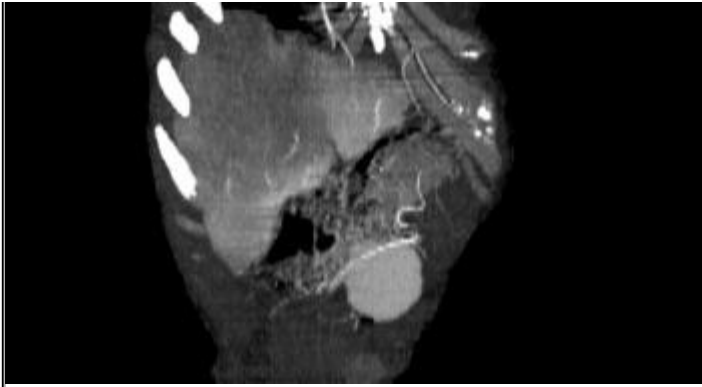
Sagittal reformatation, better depicting the cranio-caudal extension of the aneurysm and the centrifugal displacement of the renal parenchyma.



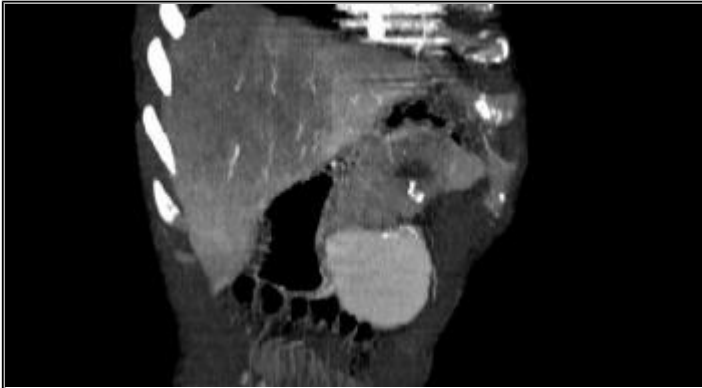
Sagittal reformatation, better depicting the cranio-caudal extension of the aneurysm and the centrifugal displacement of the renal parenchyma.

Figure 4 CT Angiography

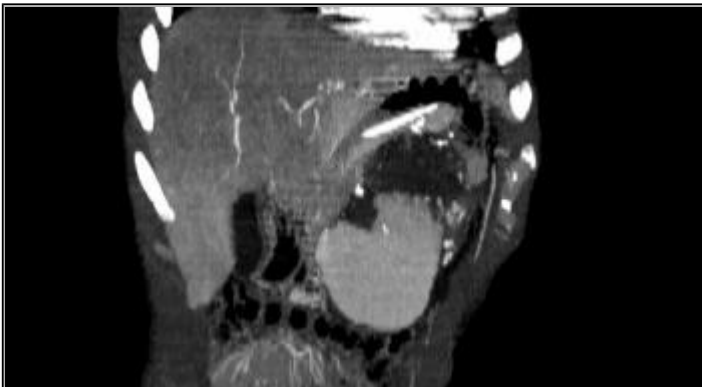




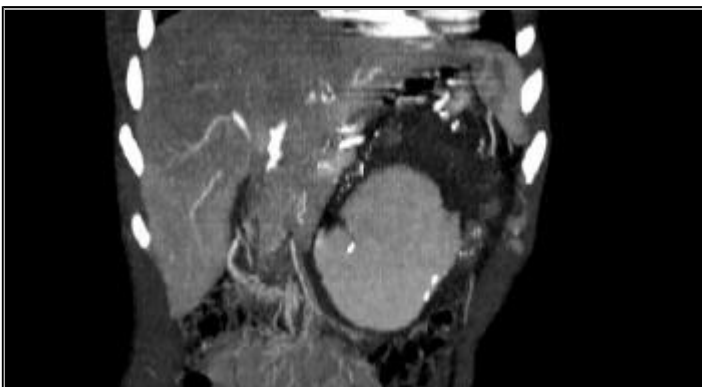
Coronal reformatation.



Coronal reformatation.

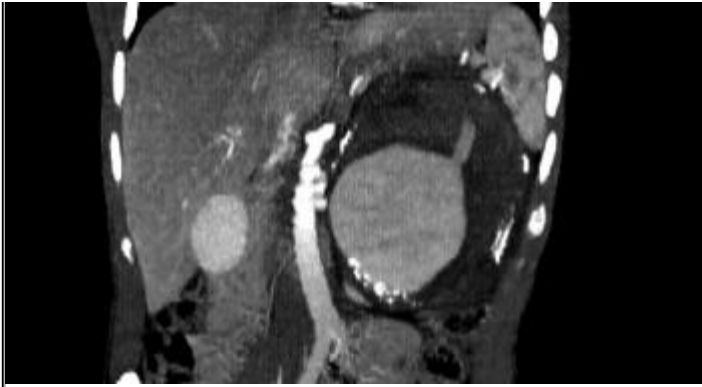


Coronal reformatation.

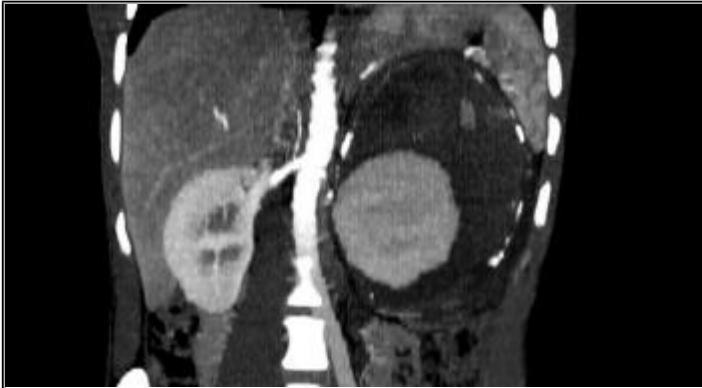

Coronal reformatation.

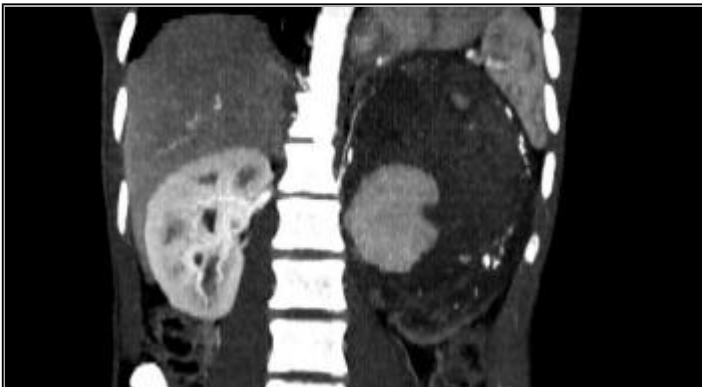




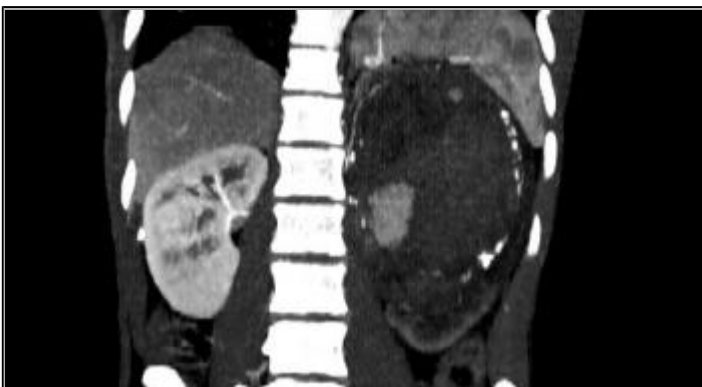
Coronal reformatation.



Coronal reformatation.

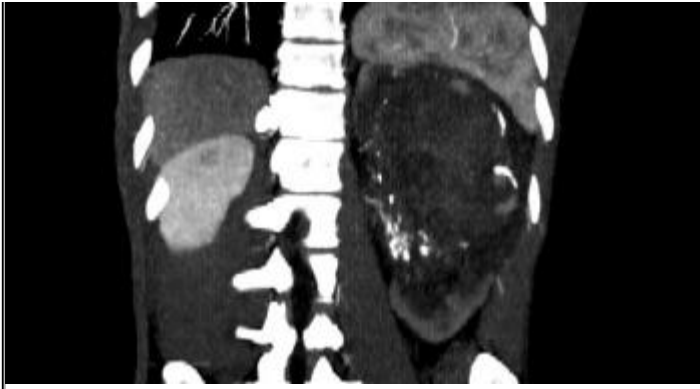

Coronal reformatation.

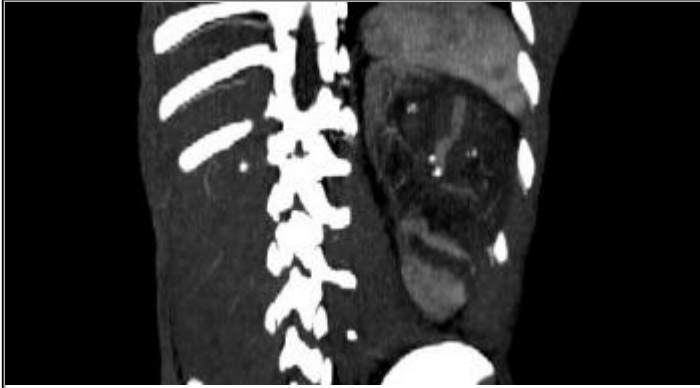


Coronal reformatation.



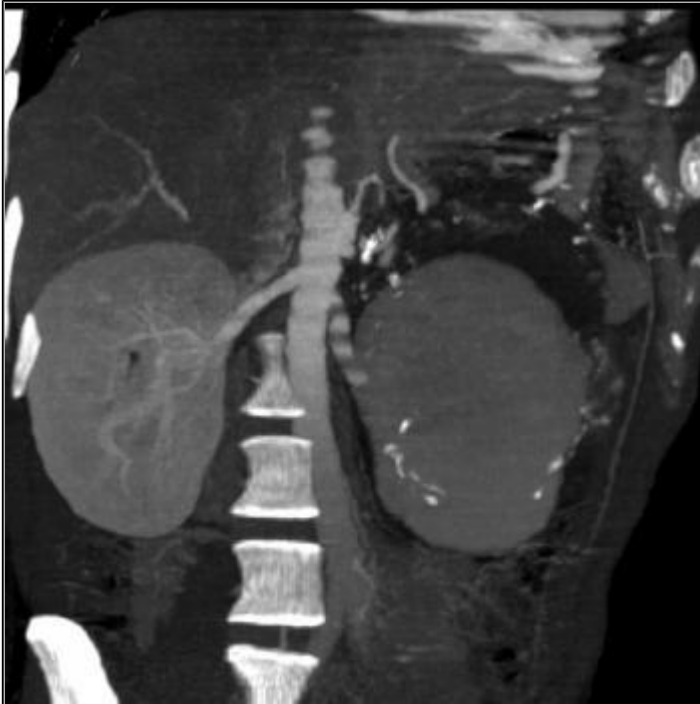

Coronal reformatation.

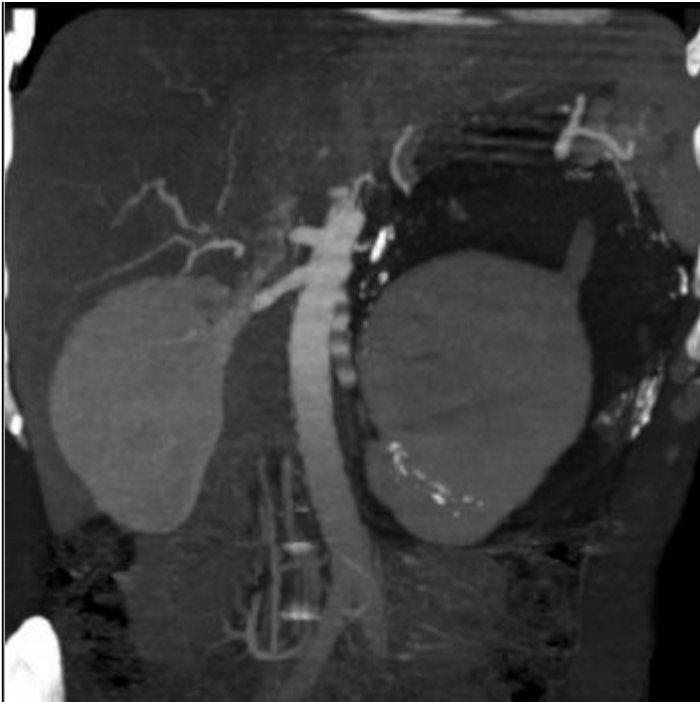

Coronal reformatation.

Figure 5 CT Angiography

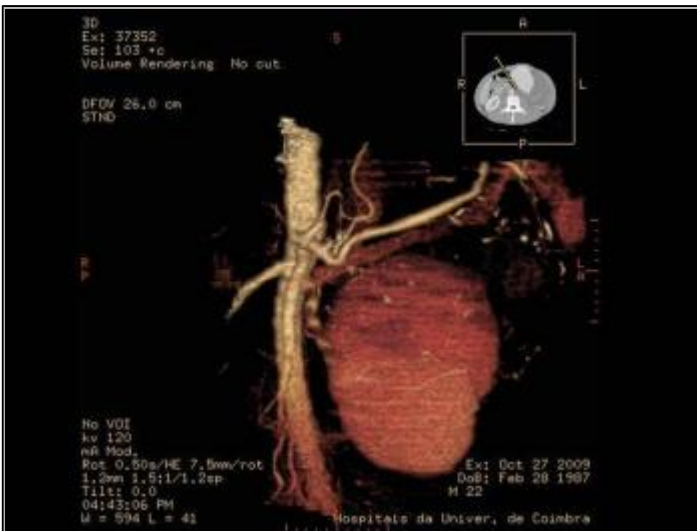


Coronal MIP image.

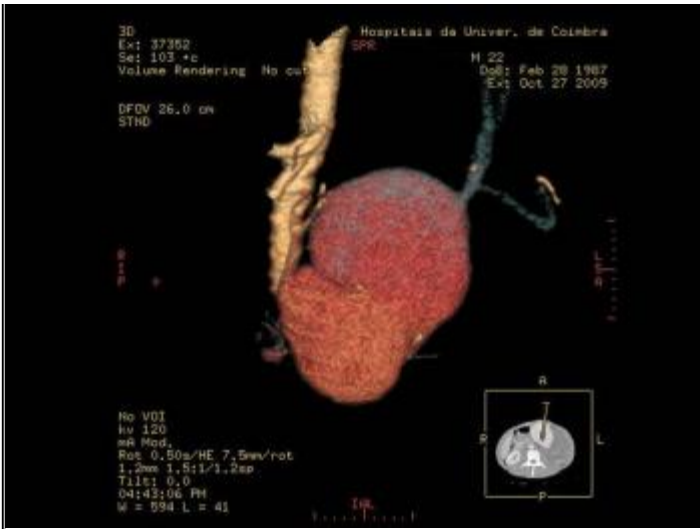


Coronal oblique MIP image.

Figure 6 CT Angiography

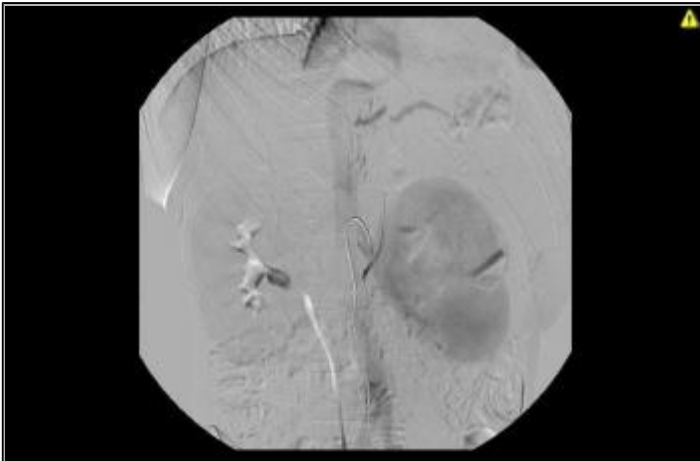


VR reconstruction, coronal oblique plane.

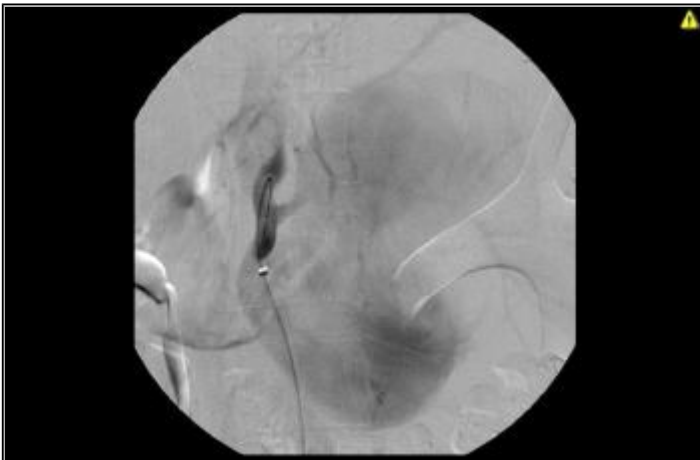

VR reconstruction, sagittal oblique plane.

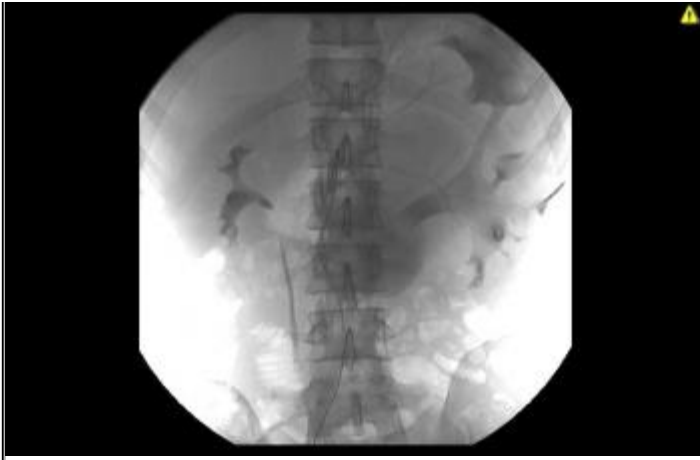
Figure 7 DSA



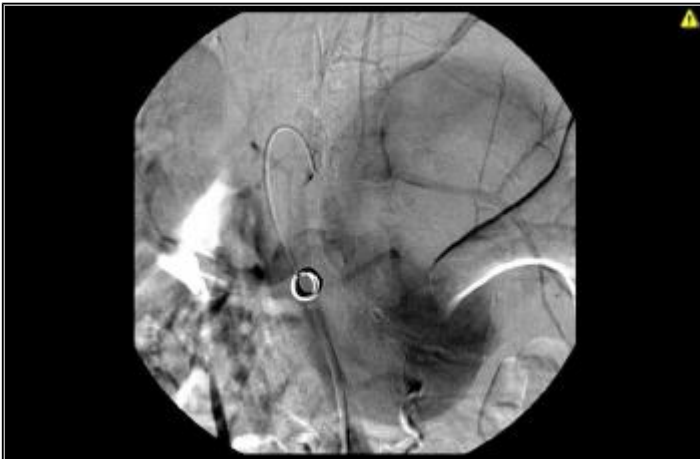
Administration of contrast after left renal artery catheterization depicting the lumen of the aneurysm.



Proximal left renal artery showed no signs of stenosis.



Note marked spreading and elongation of the calices on the left.



Coil embolisation was attempted but unsuccessful.

MeSH

Aneurysm [C14.907.055]

A sac formed by the dilatation of the wall of an artery, a vein, or the heart.

Renal Artery [A07.231.114.745]

A branch of the abdominal aorta which supplies the kidneys, adrenal glands and ureters.

References

- [1] Leiva L, Arroyo A, Gesto R (2009) [Saccular renal artery aneurysm] *Cir Esp* 86:49-51
- [2] Raza H, Al Flaiw A, Quadri K (2004) Renal Artery Aneurysm: A Case Report and Review of Literature. *Saudi J Kidney Dis Transpl* 15:375-9
- [3] Sahin S, Okbay M, Cinar B, Uzunlulu N (2007) Wide-necked renal artery aneurysm: endovascular treatment with stent-graft. *Diagn Interv Radiol* 13:42-45
- [4] De Wilde V, Devue K, Vandenbroucke F et al (2007) Rupture of renal artery aneurysm into the renal pelvis, clinically mimicking renal colic: diagnosis with multidetector CT. *The British Journal*

of Radiology 80(959):e262-4

[5] Noshier JL, Chung J, Brevetti LS et al (2006) Visceral and Renal Artery Aneurysms: A Pictorial Essay on Endovascular Therapy. Radiographics 26:16871704

[6] Blanco Dez A, Armas Molina J, Alvarado Rodriguez A et al (2008) [Renal artery aneurysm. Laparoscopic nephrectomy, ex-vivo reconstruction and autotrasplantation] Actas Urol Esp 32:763-6. Spanish

[7] Chiesa R, Melissano G, Castellano R (2004) Giant renal artery aneurysm. J Vasc Surg 40:1245

Citation

I. Santiago¹; C. Ruivo²; H. Rodrigues²; A. Gil-Agostinho²

¹Hospital Infante D. Pedro - Aveiro, Portugal

²Clínica Universitária de Imagiologia dos HUC - Coimbra, Portugal (2010, Jan. 11)

Giant aneurysm of the left renal artery {Online}

URL: <http://www.eurorad.org/case.php?id=8067>