

1 Background

Ultrasound studies in carpal tunnel syndrome (CTS) have demonstrated increased median nerve cross-sectional area (CSA) at the carpal tunnel inlet. Thus, ultrasound of the median nerve may be useful in screening for CTS.

The objective of this study was to assess the diagnostic utility of ultrasound for the diagnosis of CTS and to evaluate the reproducibility of median nerve CSA measurements.

2 Methods

➤ Participants

Individuals with symptoms compatible with classic/probable CTS were consecutively recruited among patients referred to the electromyography laboratory. Asymptomatic healthy volunteers were recruited among hospital staff.

➤ Boston Carpal tunnel syndrome Questionnaire (Portuguese version)

Symptom severity (11 items) and functional status (8 items). Multiple choice format scored from 1 point (mildest) to 5 points (most severe).

➤ Nerve conduction studies (NCS)

NCS were considered diagnostic of CTS if 1. sensory nerve action potential (SNAP) distal latency <3ms and/or 2. median-ulnar latency difference >0.4ms. Additional abnormalities, including compound muscle action potential onset latency >4ms and absence of median SNAP were used to determine the severity of CTS.

The severity of electrophysiological CTS impairment was assessed by a previously reported neurophysiological classification: Normal, Mild, Moderate, Severe and Very severe [Padua L et al, 1997].

➤ Ultrasound evaluation

Median nerve cross-sectional area and intraneural power Doppler at the proximal inlet of the carpal tunnel were measured three times, and the mean values were used for analysis.

➤ Inter- and intra-reader reliability

Two rheumatologists with different levels of experience performed the clinical and US measurements independently and blinded to the clinic and electrophysiological findings.

➤ Statistical analysis

Two-tailed Student t-test was used to evaluate the significance of the differences between the CTS and control group, in SPSS software.

Receiver operating characteristic analysis was used to assess the sensitivity and specificity of the CSA in predicting electrophysiological findings.

3 Results

➤ Sixty symptomatic wrists and twenty-six asymptomatic control wrists were examined (see Table 1).

Table 1 Distribution of patients' demographic and clinical data according to symptomatic-NCS positive, symptomatic-NCS negative and asymptomatic NCS negative groups.

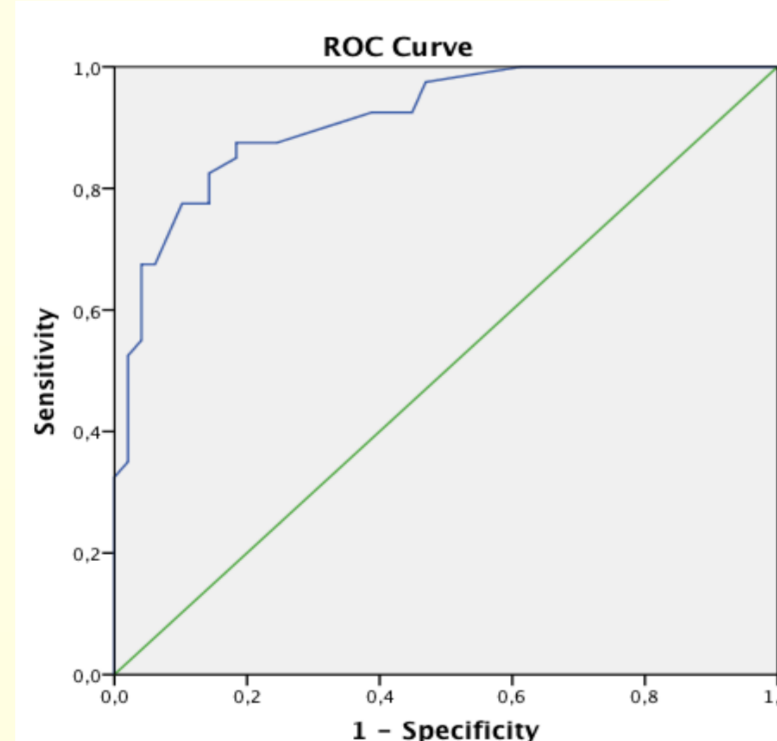
	Symptomatic NCS + 50 wrists	Symptomatic NCS - 10 wrists	P- value	Asymptomatic NCS - 26 wrists
Age (years)	49.2 (11.6)	51.4 (10.8)	-	42.9 (9.3)
Female, n (%)	45 (90)	6 (60)	-	6 (23)
BMI (Kg/m ²)	27.8 (4.2)	27.3 (5.7)	-	23.3 (3.4)
VAS (0-10mm)	3.4 (3.1)	2.3 (3.1)	0.0001 [#]	0
BQ- sympt (1.0-5.0)	2.4 (1.7)	1.7 (1.1)	0.141	0
BQ - funct (1.0-5.0)	1.7 (1.2)	1.1 (0.8)	0.059	0
CSA, mm ²	13.4 (4.4)	8.3 (1.8)	0.0001 [#]	8.1 (1.9) [†]
Power-Doppler score, n (%)	6	0	0.018 [#]	0

Values are labeled as mean (SD). BMI body mass index, VAS visual analog scale for pain, BQ-sympt BQ symptoms scale, BQ-funct BQ function scale.

[#]Statistically significant difference between symptomatic EMG positive and EMG negative group (p<0.05).

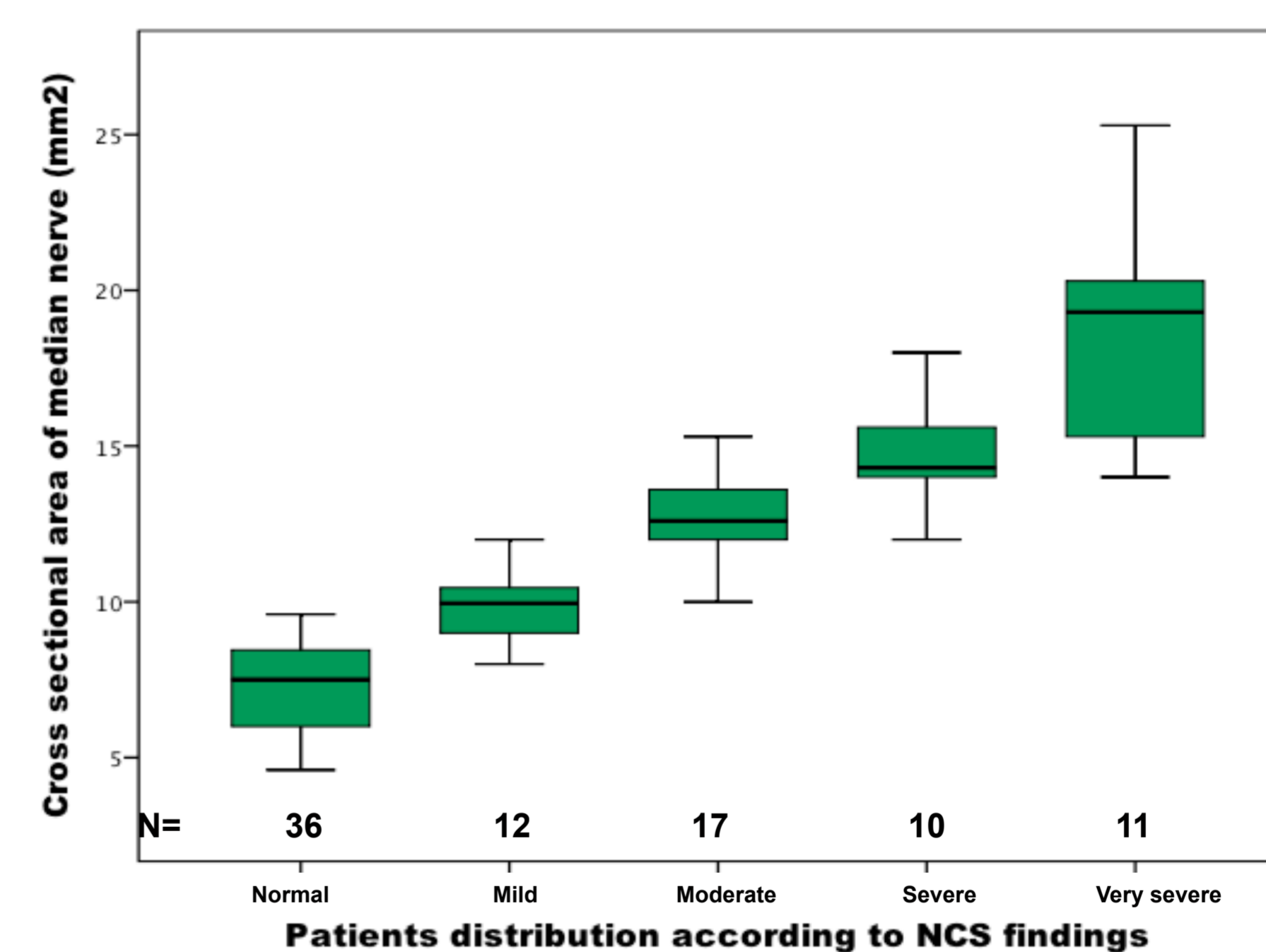
[†]Statistically significant difference between EMG positive and control group (p<0.05).

Fig. 1- ROC curve for median nerve.



Optimal screening cut-off values for CSA is 8.8mm² (93% sensitivity, 40% specificity, 78% positive predictive value, 77% negative predictive value). The area under ROC is 0.914.

Fig. 2 Distribution of cross-sectional areas of median nerves.



➤ CSA was statistically different between the severity groups according to NCS (p<0.05) (see Fig. 2).

➤ The inter- and intra-reader reliability for CSA were 0.94 and 0.91, respectively.

4 Discussion

We found that the median nerve ultrasound is a highly sensitive screening tool for NCS abnormality.

Possible implications of median nerve ultrasound screening:

- Fast, inexpensive and comfortable for patients
- Short learning curve allowing the use of ultrasound in CTS routine evaluation
- May cost-effectively reduce the number of NCS in patients with suspected CTS

Expand the study to a larger population would be necessary to determine how US and NCS testing can be used together to improve the diagnosis and treatment of CTS.

5 Conclusions

- a) Median nerve ultrasound is a highly sensitive screening tool providing an excellent discrimination between CTS patients and controls.
- b) Our results suggest that US measurement of the median nerve CSA is an easy-to-perform and reproducible technique when a standardized ultrasound examination protocol is used.
- c) Further studies are needed to define the diagnostic threefold to ensure the best possible diagnostic performance of US examination.