

PICTURES IN DIGESTIVE PATHOLOGY

Successful endoscopic banding after cyanoacrylate failure for active bleeding duodenal varix

H. T. Sousa, C. Gregório, P. Amaro, M. Ferreira, J. M. Romãozinho, H. Gouveia and M. C. Leitão

Gastroenterology Department, Coimbra University Hospital, Portugal

Upper digestive bleeding caused by ruptured duodenal varices is a rare and often life-threatening condition, for which there is little agreement on the best therapeutic option (1-5). A 47-years-old male, with alcoholic liver cirrhosis (Child-Pugh class C; MELD 29) and previous oesophageal varices bleeding, was admitted for profuse hematochezia. He was tachycardic, hypotensive and had haemoglobin 2,7 g/dl. Fluid and blood resuscitation, intravenous octreotide, ciprofloxacin and PPI were promptly started. Emergent upper gastrointestinal endoscopy (UGIE) revealed scarce fresh blood in the stomach and grade II oesophageal varices with red signs, which were thought to be the source of bleeding and treated with endoscopic banding. As hemodynamic instability and hematochezia persisted, UGIE was repeated with similar findings and no bleeding was identified on angiography. At 48 h from admission massive re-bleeding occurred and a 3rd UGIE showed a fresh clot-over-varix located at 2nd to 3rd portions of duodenum (Fig. 1). Injection of the varix with 1 cc of lipiodol and cyanoacrylate 1:1 mixture was performed (Fig. 2), but spurting began soon after the procedure. Given the high surgical risk, yet another endoscopic approach was decided and successful 1-ring banding was accomplished (Fig. 3). A 3rd-day UGIE showed a clean, shallow ulcer at the site of the varix (Fig. 4). No rebleeding episodes occurred. Several authors reported endoscopic banding for bleeding duodenal varices (1-4), sometimes followed by other therapies for rebleeding (3,4). Others used cyanoacrylate for emergent treatment of this condition (5), including after banding failure (3). This is, to our knowledge, the first report in which banding was ap-

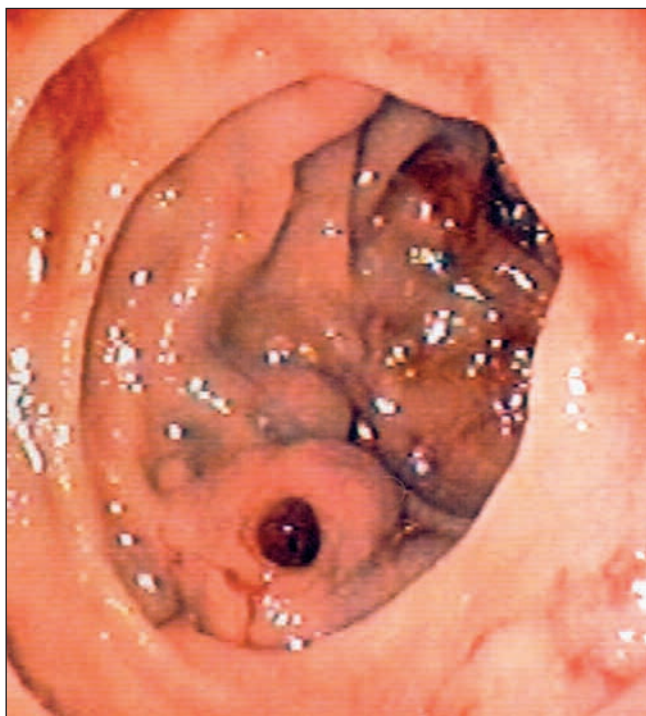


Fig. 1. Clot over ruptured duodenal varix located at 2nd to 3rd portion of the duodenum.

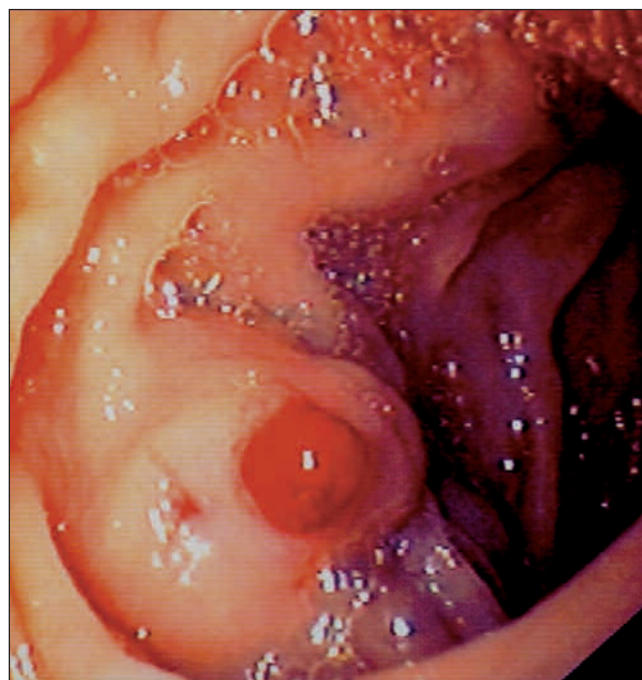


Fig. 2. Ruptured duodenal varix immediately after cyanoacrylate injection.

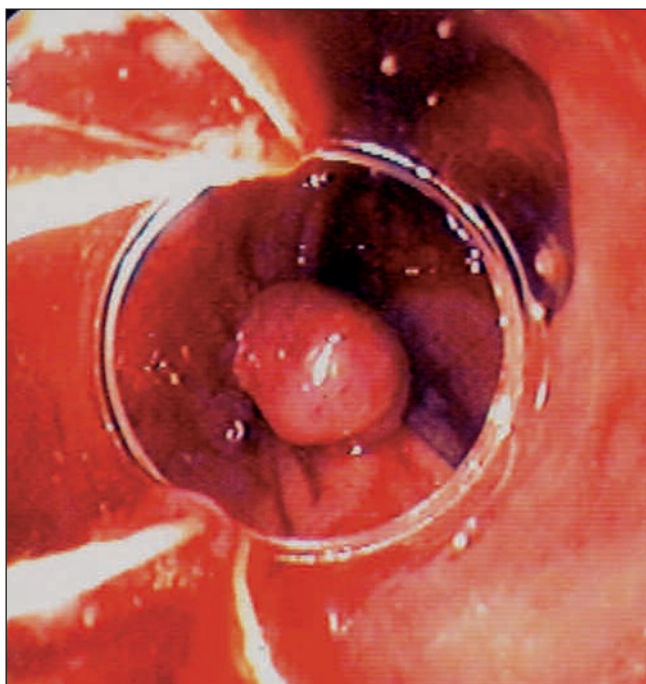


Fig. 3. Successful 1-ring banding of ruptured duodenal varix.

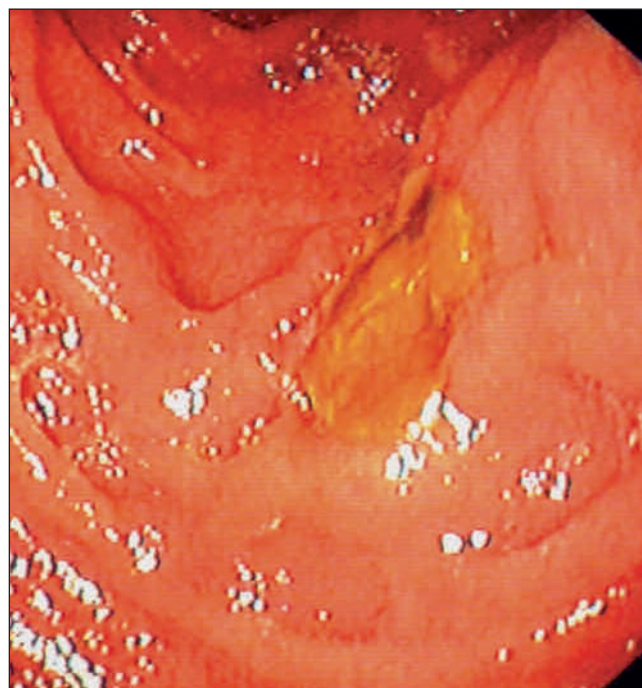

Fig. 4. Third-day endoscopy showed a shallow ulcer with no bleeding stigmata.

plied as a salvage therapy after cyanoacrylate failure. The size of the varix could be of importance in deciding whether banding should be an appropriate option (1,2), but the existing limited experience warrants that management of ectopic varices should still depend on the physician experience (4).

REFERENCES

1. Yeh YY, Hou MC, Lin HC, Chang FY, Lee SD. Case report: Successful obliteration of a bleeding duodenal varix by using endoscopic ligation. *J Gastroenterol Hepatol* 1998; 13: 591-3.
2. Tan NC, Ibrahim S, Tay KH. Successful management of a bleeding duodenal varix by endoscopic banding. *Singapore Med J* 2005; 46: 723-5.
3. Yoshida Y, Imai Y, Nishikawa M, Nakatukasa M, Kurokawa M, Shibata K, et al. Successful endoscopic injection sclerotherapy with N-butyl-2-cyanoacrylate following the recurrence of bleeding soon after endoscopic ligation for ruptured duodenal varices. *Am J Gastroenterol* 1997; 92: 1227-9.
4. Selçuk H, Boyvat F, Eren S, Korkmaz M, Gür G, Yılmaz U, et al. Duodenal varices as an unusual cause of gastrointestinal bleeding due to portal hypertension: A case report. *Turk J Gastroenterol* 2004; 15: 104-7.
5. Ota K, Shirai Z, Masuzaki T, Tanaka K, Higashihara H, Okazaki M, et al. Endoscopic injection sclerotherapy with N-butyl-2-cyanoacrylate for ruptured duodenal varices. *J Gastroenterol* 1998; 33: 550-5.