

CASE REPORT

An 11-year-old boy with pharyngitis and cough: Lemierre syndrome

Patricia Mação,¹ Candida Cancelinha,¹ Paulo Lopes,² Fernanda Rodrigues¹

¹Department of Emergency Service and Infectious Disease Unit, Hospital Pediátrico Coimbra, Centro Hospitalar Universitário de Coimbra, Coimbra, Portugal

²Department of Pediatric Service, Centro Hospitalar Cova da Beira, Covilha, Portugal

Correspondence to

Dr Patricia Mação,
patriciamacao@gmail.com

SUMMARY

The authors present the case of an 11-year-old boy with pharyngitis, treated with amoxicillin, that worsened on day 7, with cough, high fever and refusal to eat. Lethargy and respiratory distress were noted. Based on radiographic findings of bilateral infiltrates he was diagnosed with pneumonia and started on intravenous ampicillin and erythromycin. Two days later he complained of right-sided neck pain and a palpable mass was identified. An ultrasound showed partial thrombosis of the right internal jugular vein and a lung CT scan revealed multiple septic embolic lesions. Lemierre syndrome was diagnosed, antibiotic treatment adjusted and anticoagulation started. A neck CT-scan showed a large parapharyngeal abscess. His clinical condition improved gradually and after 3 weeks of intravenous antibiotics he was discharged home on oral treatment. This case illustrates the importance of diagnosing Lemierre syndrome in the presence of pharyngitis with localised neck pain and respiratory distress, to prevent potentially fatal complications.

BACKGROUND

Lemierre syndrome (LS) is an uncommon disease, first described by Andre Lemierre in 1936, who reported 20 cases of 'anaerobic septicaemia'.¹ This syndrome is characterised by an acute oropharyngeal infection followed by ipsilateral septic thrombophlebitis of the internal jugular vein (IJV), and is frequently complicated by metastatic infections via septic emboli. LS usually affects healthy adolescents and young adults, with a slightly higher incidence in males.²⁻⁴ The most common aetiological agent is *Fusobacterium necrophorum*.³

With the widespread use of antibiotics in the management of acute oropharyngeal infections, its incidence has declined substantially, with no identifiable reported cases in the 1950s and 1960s.³⁻⁷ However, in the last decades, a few cases have been published, maybe related to an increase in its incidence and clinical recognition or reflecting the common use of antibiotics, particularly macrolides (without action against *F necrophorum*), in the treatment of pharyngeal infections.^{6,8} An incidence between 0.6 and 2.3 per million has been reported, with death rates ranging from 4% to 18%, and with significant morbidity, specifically in cases with delayed diagnosis.²⁻⁴

We present this case with the purpose of increasing physician's awareness of this disorder, since a high degree of clinical suspicion is warranted to diagnose this syndrome. Accurate and timely

diagnosis and appropriate therapy are crucial to prevent its elevated morbidity and mortality.

CASE PRESENTATION

A previously healthy 11-year-old boy presented to his local hospital complaining of pain when swallowing and low fever. Group A streptococcal rapid antigen test on a throat swab was negative, and he was discharged home with the diagnosis of viral pharyngitis. During the following days he was seen again in hospital, with no changes on examination, diagnosis or management.

On day 5 of disease he returned with additional complaints: cough and high fever. Examination remained unchanged, and despite a negative group A streptococcal rapid antigen test, a course of oral amoxicillin was prescribed. There was no improvement and he returned to the emergency room 2 days later refusing to eat, lethargic and complaining of pain in his right shoulder. He appeared acutely ill, with grunting, increased respiratory rate (up to 30/min) and transcutaneous oxygen saturation consistently >95% in room air. Examination of his throat revealed mild erythema and swelling of the oropharynx and on auscultation there was reduced air entry in both lower lung lobes. The chest x-ray showed bilateral opacities in both of these lobes, more pronounced on the right, with air bronchogram and diffuse bilateral bronchopneumonia foci without effusion (figure 1). Blood tests showed elevated white blood cell count with neutrophilia ($13 \times 10^9/l$) and C reactive protein of 19.3 mg/dl. Serologies for *Mycoplasma pneumoniae*, *Chlamydia pneumoniae*, Epstein-Barr virus and Cytomegalovirus and blood cultures were performed. A diagnosis of pneumonia was made and he was started on intravenous ampicillin and erythromycin.

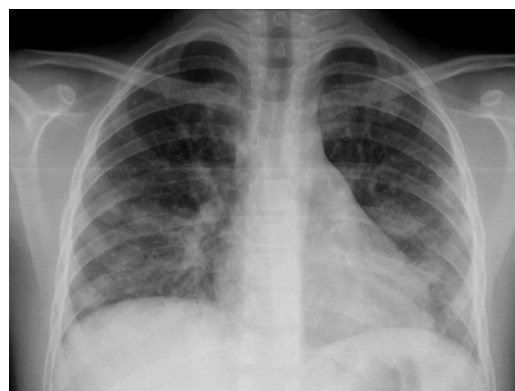

Figure 1 Chest x-ray.

To cite: Mação P, Cancelinha C, Lopes P, et al. *BMJ Case Rep* Published online: [please include Day Month Year] doi:10.1136/bcr-2012-008527

In spite of initial clinical improvement, 48 h later (day 9 of disease) he developed respiratory distress, high fever, abdominal and right-sided neck pain. Examination revealed a small right-sided cervical mass towards the back of the anterior triangle.

INVESTIGATIONS

An ultrasound showed lymphadenopathies and partial thrombosis of the right IJV.

A thoracic CT scan revealed multiple cavitated pneumonic foci compatible with septic embolic lesions.

TREATMENT

On the basis of these findings, the diagnosis of Lemierre syndrome was made and antibiotics were changed to piperacillin+tazobactam and metronidazole. Anticoagulation with subcutaneous enoxaparin was started.

OUTCOME AND FOLLOW-UP

He was transferred to the joint care of the ear–nose and throat (ENT) and paediatric infectious diseases teams at a tertiary centre. On arrival his tonsils looked asymmetrical. A neck CT scan with contrast was performed and confirmed thrombosis of the right IJV and also showed a large parapharyngeal loculated heterogeneous lesion compatible with an abscess, causing displacement of the airway to the left, with extension to the carotid space and encirclement of the carotid artery without compression or infiltration of the artery wall (figure 2).

The ENT team elected to pursue an expectant approach due to the proximity of the abscess to the internal carotid artery. He required oxygen supplementation during the first 24 h and his general condition improved gradually. Laboratory markers normalised within 1 week. Blood cultures were negative and serologies did not show acute infection.

He was discharged home after 3 weeks of intravenous antibiotics on oral amoxicillin+clavulanic acid and metronidazole, completing 6 weeks of treatment. Anticoagulation was continued for 6 months.

The patient remained asymptomatic after discharge. Follow-up ultrasound scans of the jugular vein still showed persistent thrombus with no further extension. A follow-up CT scan of the chest was normal 6 months later.

DISCUSSION

In paediatrics, the natural course of pharyngitis is typically complete resolution within 1 week. An atypical course of the disease, with worsening symptoms or these lasting longer than expected or emergence of painful unilateral swelling of the neck, should raise other diagnoses, including Lemierre syndrome.

The progression of clinical symptoms closely follows the disease course and can be divided into four stages: in the first stage clinical findings are not specific and depend on the primary site of infection (usually the oropharynx). In the second and third stages there is invasion of the lateral parapharyngeal space leading to IJV thrombophlebitis, often manifesting as pain and unilateral swelling at the angle of the jaw and along the sternocleidomastoid muscle (present in 50% of cases).⁷ The fourth and last stage corresponds to metastatic spread, which depends on the clinical findings and the site of the septic embolism (most commonly the lung, with abscesses and respiratory distress).⁴

The causative organisms are usually part of the normal oropharyngeal flora. The most common pathogen is *F necrophorum* (more than 50% of the cases).⁹ Other pathogens include other *Fusobacterium* species (eg, *Fusobacterium nucleatum*), *Eikenella corrodens*, *Porphyromonas asaccharolytica*, *Streptococcus pyogenes*, *Bacteroides* and also *Staphylococcus aureus*, including methicillin-resistant strains (MRSA).^{10–12}

Early diagnosis and antibiotic therapy are essential for a good clinical outcome. Intravenous therapy with coverage for anaerobic pathogens during 3–6 weeks is recommended, and should be initiated as soon as possible. Drainage of purulent collections is highly encouraged, both for rapid recovery and for causative pathogen identification. Unfortunately we were not able to identify a microorganism. Blood cultures were obtained when the patient was already on antibiotics and surgical drainage was not chosen by the ENT team. As a result, metronidazole for anaerobes and piperacillin+tazobactam for coverage of Gram-positive bacteria, including *S aureus* were started. MRSA are very rarely found in community-acquired infections in our institution and in the central region of Portugal (unpublished data) and prevalence of carriage in healthy young children remains extremely low.¹³ However, in countries with a high incidence of community-acquired MRSA, adequate empirical

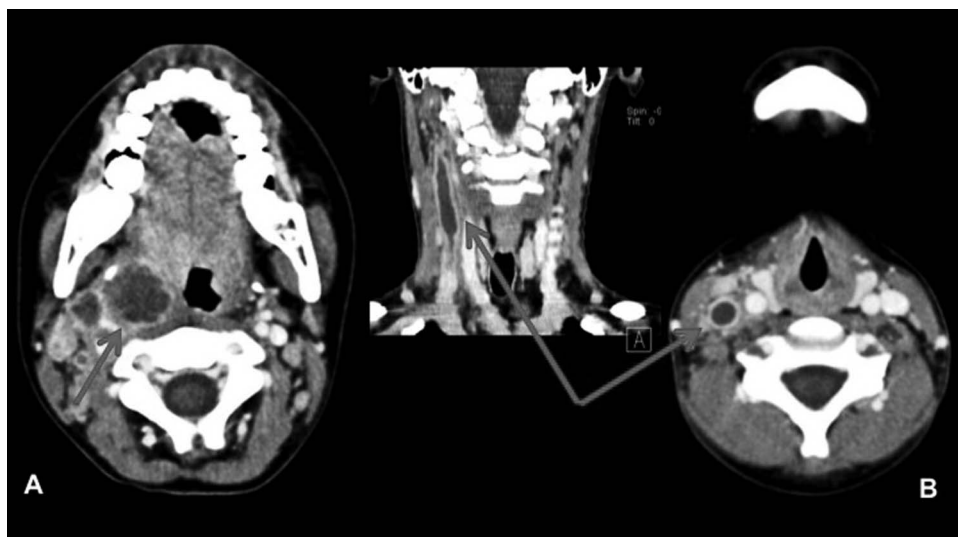


Figure 2 Neck CT scan with parapharyngeal abscess (A) and thrombosis of right internal jugular vein (B).

antibiotic treatment should be chosen to provide suitable coverage.

Other surgeries, such as surgical ligation or excision of the IJV, although rarely used, are described in the setting of on-going sepsis or in patients without response to antibiotic therapy.

The role of anticoagulation remains controversial, and there are no controlled studies to assess its value in septic thrombophlebitis of the IJV. Some authors recommend its use only if there is evidence of extension of the thrombus.¹⁰ Others advocate it as an adjunct to antibiotic therapy, referring its potential for faster resolution of thrombophlebitis and bacteraemia, thus limiting the development of new metastatic foci.⁴

Learning points

- ▶ Unusual clinical course of frequent diseases should alert physicians for complications.
- ▶ Lemierre syndrome still remains an important cause of morbidity due to rapid disease progression and potential diagnostic delays.
- ▶ Early diagnosis and treatment is important to avoid serious complications.

Acknowledgements We would like to thank our ENT and Radiology colleagues for their contribution to the management of this patient.

Competing interests None.

Patient consent Obtained.

Provenance and peer review Not commissioned; externally peer reviewed.

REFERENCES

- 1 Lemierre A. On certain septicaemias due to anaerobic organisms. *Lancet* 1936;227:701–3.
- 2 Alherabi A. A case of Lemierre syndrome. *Ann Saudi Med* 2009;29:58–60.
- 3 Chirinos JA, Lichtstein DM, Daniel M, et al. The evolution of Lemierre syndrome: report of 2 cases and review of the literature. *Medicine (Baltimore)* 2002;81:458–65.
- 4 Ridgway JM, Parikh DA, Wright R, et al. Lemierre syndrome: a pediatric case series and review of literature. *Am J Otolaryngol* 2010;31:38–45.
- 5 Young BJ, Steele RW. A teenager with sore throat and neck pain. *Clin Pediatr* 2010;49:1088–9.
- 6 Amaro C, Pissarra C, Salvado C, et al. Síndrome de Lemierre: um caso clínico. *Med Interna* 2005;12:225–9.
- 7 Screation NJ, Ravenel JG, Heitzman RE, et al. Lemierre syndrome: forgotten but not extinct—report of four cases. *Radiology* 1999;213:369–74.
- 8 Riordan T. Human infection with *Fusobacterium necrophorum* (Necrobacillosis), with a focus on Lemierre's syndrome. *Clin Microbiol Rev* 2007;20:622–59.
- 9 Karkos P, Asrani S, Karkos C, et al. Lemierre's syndrome: a systematic review. *Laryngoscope* 2007;117:1605–10.
- 10 Spelman D, Sexton DJ, Bloom A. Suppurative (septic) thrombophlebitis. In: UpToDate, Basow DS, Waltham, MA: UpToDate, 2012.
- 11 Hoehn KS, Capouya JD, Daum RS, et al. Lemierre-like syndrome caused by community-associated methicillin-resistant *Staphylococcus aureus* complicated by hemorrhagic pericarditis. *Pediatr Crit Care Med* 2010;11:e32–5.
- 12 Chanin JM, Marcos LA, Thompson BM, et al. Methicillin-resistant *Staphylococcus aureus* USA300 clone as a cause of Lemierre's syndrome. *J Clin Microbiol* 2011;49:2063–6.
- 13 Tavares DA, Sá-Leão R, Miragaia M, et al. Large screening of CA-MRSA among *Staphylococcus aureus* colonizing healthy young children living in two areas (urban and rural) of Portugal. *BMC Infect Dis* 2010;10:110.

Copyright 2013 BMJ Publishing Group. All rights reserved. For permission to reuse any of this content visit <http://group.bmj.com/group/rights-licensing/permissions>.

BMJ Case Report Fellows may re-use this article for personal use and teaching without any further permission.

Become a Fellow of BMJ Case Reports today and you can:

- ▶ Submit as many cases as you like
- ▶ Enjoy fast sympathetic peer review and rapid publication of accepted articles
- ▶ Access all the published articles
- ▶ Re-use any of the published material for personal use and teaching without further permission

For information on Institutional Fellowships contact consortiasales@bmjgroup.com

Visit casereports.bmj.com for more articles like this and to become a Fellow